

Alzheimer's Disease Anti-Amyloid Immunotherapies: Imaging Recommendations and Practice Considerations for ARIA Monitoring

Cogswell, Petrice M. Andrews, Trevor J. Barakos, Jerome A. Barkhof, Frederik. Bash, Suzie. Benayoun, Marc Daniel. Chiang, Gloria C. Franceschi, Ana M. Jack Jr, Clifford R. Pillai, Jay J. Poussaint, Tina Young. Raji, Cyrus A. Ramanan, Vijay K. Tanabe, Jody. Tanenbaum, Lawrence. Whitlow, Christopher T. Yu, Fang F. Zaharchuk, Greg. Zeinah, Michael. Benzinger, Tammie S. for the ASNR Alzheimer's, ARIA, and Dementia Study Group

ABSTRACT

With the full FDA approval and centers for Medicare & Medicaid services (CMS) coverage of lecanemab and donanemab, a growing number of practices are offering anti-amyloid immunotherapy to appropriate patients with cognitive impairment (MCI) or mild dementia due to amyloid-positive Alzheimer's disease (AD). The goal of this paper is to provide updated practical considerations for radiologists, including implementation of MR imaging protocols, workflows and reporting and communication practices relevant to anti-amyloid immunotherapy and monitoring for amyloid-related imaging abnormalities (ARIA). Based on consensus discussion within an expanded ASNR Alzheimer's, ARIA, and Dementia study group, we will: (1) summarize the FDA guidelines for evaluation of radiographic ARIA; (2) review the three key MRI sequences for ARIA monitoring and standardized imaging protocols based on ASNR-industry collaborations; (3) provide imaging recommendations for three key patient scenarios; (4) highlight the role of the radiologist in the care team for this population; (5) discuss implementation of MRI protocols to detect ARIA in diverse practice settings; and (6) present results of the 2023 ASNR international neuroradiologist practice survey on dementia and ARIA imaging.

ABBREVIATIONS: AD = Alzheimer's disease; ARIA = amyloid-related imaging abnormalities; APOE = apolipoprotein-E; CMS = centers for Medicare & Medicaid services; MCI = mild cognitive impairment.

Received month day, year; accepted after revision month day, year.

From the Departments of Radiology (P.M.C., C.R.J., J.J.P.) and Neurology (V.K.R.), Mayo Clinic, Rochester, Minnesota; Departments of Radiology (T.J.A., T.S.B., C.A.R.), Neurosurgery (T.S.B.), and Neurology (C.A.R.), WA University School of Medicine, St. Louis, Missouri; Department of Radiology (J.A.B.), CA Pacific Medical Center, San Francisco, California; Departments of Radiology (F.B.) and Nuclear Medicine (F.B.), VU University Medical Center, Amsterdam, the Netherlands; Queen Square Institute of Neurology and Centre for Medical Image Computing (F.B.), University College London, UK; RadNet Imaging Centers (S.B., L.T.), Los Angeles, California; Departments of Radiology (M.D.B., C.T.W.) and Biomedical Engineering (C.T.W.), Wake Forest School of Medicine, Winston-Salem, North Carolina; Department of Radiology (G.C.C.), Weill Cornell Imaging and New York Presbyterian, New York, New York; Department of Radiology (A.M.F.), Northwell Health, New York, New York; Department of Radiology (T.Y.P.), Boston Children's Hospital, Boston, Massachusetts; Department of Radiology (J.T.), UC Health University of Colorado Hospital, Aurora, Colorado; Department of Radiology (F.F.Y.), UT Southwestern Medical Center, Dallas, Texas; and Department of Radiology (G.Z., M.Z.), Stanford Health Care, Stanford Medicine Children's Hospital, Stanford, California.

The authors have not received funding or payments directly related to this article. Please see the final publication for a full list of author disclosures. Disclosure of potential conflicts of interest should be included here.

Please address correspondence to Petrice M. Cogswell, MD, PhD, Department of Radiology, Mayo Clinic, 200 First Street SW, Rochester, MN 5592, USA; Cogswell.petrice@mayo.edu.

INTRODUCTION

Monoclonal antibody therapies are becoming widespread in clinical practice, treating neurologic diseases ranging from cancer to multiple sclerosis and now Alzheimer disease (AD)¹⁻³. In AD, treatment with anti-amyloid immunotherapy may be associated with radiographic findings resembling cerebral amyloid angiopathy (CAA) related inflammation and has been termed amyloid related imaging abnormality (ARIA)⁴⁻¹². ARIA is hypothesized to arise from the removal of amyloid deposits from and alongside cerebral arteries, resulting in vessel leakage and potentially provoking an immune response which can continue for weeks to months even after cessation of anti-amyloid immunotherapy^{13,14}.

The two types of ARIA are ARIA-E, in which -E stands for vasogenic edema and sulcal effusions, and ARIA-H, in which -H stands for hemorrhage and includes microhemorrhages and superficial siderosis that in rare cases may be associated with intraparenchymal hemorrhage and intraventricular hemorrhage. ARIA is a common side effect of anti-amyloid immunotherapy for AD, occurring in approximately 10-30% of all participants treated in clinical trials for aducanumab, lecanemab, and donanemab^{6,9,11,12}. The data from those trials suggests 74-97% of ARIA is asymptomatic (i.e., is detected on routine monitoring). It is rare for ARIA to present with neurologic symptoms, but when it does, symptoms can include headache, confusion, dizziness, visual changes, or praxis difficulties^{8,9,11,15,16}. Differentiation of symptomatic ARIA from stroke is a critical concern, as misdiagnosis and treatment with thrombolytics can potentially result in fatal intracranial hemorrhage¹⁷.

The primary known risk factor for ARIA is apolipoprotein-E (APOE) $\epsilon 4$ genotype carrier status, which is also associated with an increased risk of CAA, due to increased vascular amyloid deposits in APOE $\epsilon 4$ carriers¹³. The effect of APOE $\epsilon 4$ on ARIA risk is dose-dependent, with APOE $\epsilon 4$ homozygous individuals displaying the highest risk. Baseline (pre-treatment) microhemorrhages are also predictive of future ARIA-H, and patients with 5 or more baseline microhemorrhages were excluded from recent clinical trials using anti-

amyloid immunotherapies^{8,11,18}. The second major risk factor for ARIA is drug dose. Finally, risk of ARIA is associated with treatment duration. Patients are at greatest risk of developing ARIA during the first few months of treatment, when vessel wall amyloid is being mobilized¹³. For these reasons, gradually increasing dose to reach a therapeutic dose level has been proposed to reduce ARIA incidence. Multiple non-contrast brain MRI scans are recommended to monitor for ARIA, especially during treatment initiation.

The United States FDA has adopted a standard radiographic classification for ARIA (**Figure 1**), following the classification systems used in clinical trials for anti-amyloid immunotherapies. The Alzheimer's Disease and Related Disorders Therapeutic Workgroup [American Neurological Association (ANA)] has published a white paper recommending that anti-amyloid immunotherapy be paused for moderate ARIA-E or ARIA-H (even if asymptomatic) and discontinued for severe ARIA^{19,20}. Given these serious patient care implications, the potentially numerous MR imaging sessions needed, and the prevalence of patients with AD who may be treated, it is important for radiology practices to be prepared to perform, interpret, and communicate findings of these MRI exams reliably, meaningfully, and in a timely manner.

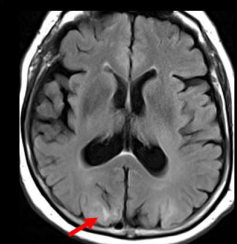
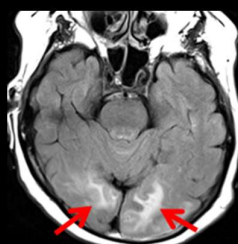
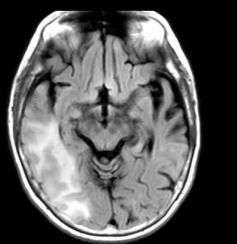
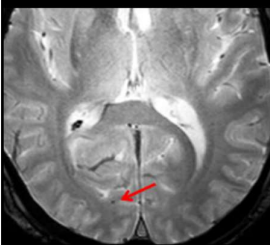
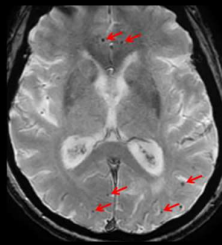

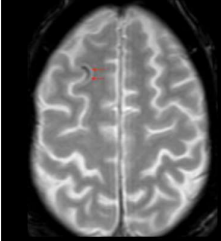
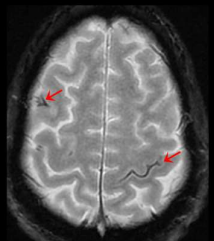

	Mild	Moderate	Severe
ARIA-E (new, treatment emergent sulcal and/or cortical/subcortical FLAIR hyperintensity)	One location < 5cm	One location 5-10 cm OR More than one location each < 10 cm	One or more location > 10 cm
			
ARIA-H (new, treatment emergent microhemorrhage)	≤ 4	5-9	≥ 10
			
ARIA-H (new, treatment emergent superficial siderosis)	1 focal area	2 focal areas	> 2 focal areas
			

FIG 1. ARIA radiographic severity score. Each ARIA-E, ARIA-H microhemorrhages, and ARIA-H superficial siderosis is graded separately based on treatment emergent imaging findings. Any new, transient edema/sulcal effusion and new microhemorrhages or siderosis that occur while on treatment constitute ARIA. For ARIA-E, the size indicates greatest extent of contiguous signal abnormality/gyral swelling measured in any dimension. ARIA-E: mild, new post-dosing right occipital parenchymal edema measuring < 5 cm; moderate, new edema in the bilateral occipital white matter is moderate ARIA-E based on two regions of involvement; severe, new edema involving the right temporal and occipital lobes measuring > 10 cm in greatest dimension. ARIA-H microhemorrhages: mild, one right occipital treatment emergent microhemorrhage; moderate, six scattered treatment emergent microhemorrhages, and severe, > 10 treatment emergent microhemorrhages clustered in the left occipital lobe. ARIA-H superficial siderosis: mild, one right frontal region of treatment emergent siderosis; moderate, two regions of siderosis, right frontal and left central sulcus; severe, three regions of siderosis, bilateral frontal and left parietal. Images courtesy of DIAN and Biogen.

With ongoing studies and approvals, AD therapeutics are becoming widely available in the community. As radiology practices prepare to provide care for these patients, many are seeking additional resources and guidance to optimize imaging protocols and workflows and to feasibly translate experience from clinical trials into clinical practice. This white paper builds upon our prior paper, “Amyloid-Related

Imaging Abnormalities with Emerging Alzheimer Disease Therapeutics: Detection and Reporting Recommendations for Clinical Practice”²¹. The primary aim is to provide updated practical considerations for implementation of MR imaging protocols, workflows and reporting and communication practices, based on consensus discussion within an expanded ASNR Alzheimer’s and Dementia study group, representing a broad scope of neuroradiology practice settings and locations.

ROLE OF THE RADIOLOGIST IN THE PATIENT CARE CYCLE

With the full FDA approval and CMS coverage of lecanemab and donanemab, anti-amyloid immunotherapy is now a realistic option for appropriate patients with mild cognitive impairment (MCI) or early dementia due to amyloid-positive AD. Amyloid positivity can be determined by amyloid PET, as performed in the lecanemab phase III trial¹¹, CSF biomarkers, as is most common in clinical practice²², and plasma biomarkers, which are an emerging clinical option²³. The evaluation of amyloid status, of exclusionary MRI findings at baseline, and for safety monitoring has resulted in an increase in radiology services, including MRI scans and fluoroscopic-guided lumbar punctures. The recently updated CMS payment decision for amyloid PET, removing the requirement to be part of a clinical research study, will also likely increase the demand for amyloid PET imaging. The increased volume of MRI scans reflects a combination of baseline/enrollment non-contrast brain MRI scans to confirm eligibility for therapy based upon several features, routine exams to monitor for ARIA, follow-up of documented ARIA, and imaging of symptomatic patients, with at least four MRI scans per patient anticipated in the first year of treatment.

The increase in scan volumes is expected to be widespread across academic and private practices, though may vary based on the local patient and provider population. Estimates of the number of patients who will undergo evaluation and treatment in a region and the projected increase in MRI scan volume may help facilities gauge their ability to accommodate the increased imaging demands for this patient population. Some practices have found that their projections may represent overestimates given variable access to upstream elements in the care pathway (i.e. referral to a neurologist) and other factors (e.g., medical comorbidities, patient preferences). For example, in a recent study of participants with mild AD in a population-based sample, only 5-8% of participants met eligibility criteria for the aducanumab and lecanemab trials²⁴. Despite the limitations of projections, it is anticipated that with drug availability and patient interest, there could be large numbers of patients seeking to be evaluated for treatment. Each practice must decide how they will manage and triage these requests, which could easily overwhelm existing radiology capacities and workflows without careful planning. Close communication between referring providers, radiologists, and hospital administrations will aid in preparation. In this article we provide recommendations for efficient and effective imaging of these patients, which can help accommodate the increased volumes.

IMAGING WORKFLOWS: THREE KEY PATIENT SCENARIOS

There are several aspects of radiology workflows that will benefit from advanced planning and consideration regarding AD therapeutics. We will discuss general considerations as well as those specific to three patient scenarios: (1) baseline dementia diagnosis/treatment enrollment evaluation, (2) asymptomatic ARIA monitoring, and (3) evaluation of the symptomatic patient on anti-amyloid immunotherapy. The applicability of these considerations to each practice will vary with the size of the practice, ability to perform subspecialized exams, and diversity of the MRI scanner fleet.

Timing of MRI scans

Each patient requires an MRI prior to the initiation of treatment, to evaluate for exclusionary findings and provide a baseline for future comparison. Appropriate use criteria by the Alzheimer’s Disease and Related Disorders Therapeutics Work Groups and FDA label for aducanumab recommend that the baseline MRI should be performed within one year prior to enrollment^{19,20,25,26}. The lecanemab and donanemab FDA labels specify a “recent” brain MRI prior to enrollment. *We recommend that the baseline brain MRI is ideally performed within 3-6 months prior to enrollment, but a brain MRI within 12 months may be adequate if negative for microhemorrhages*, which aligns with the lecanemab appropriate use recommendations¹⁹. Presence of 1-4 baseline microhemorrhages on a brain MRI performed 7-12 months prior to initiating therapy should trigger a repeat exam, as these patients are of high risk for additional microhemorrhages. Interval progression of these findings (more microhemorrhages) may affect the patient’s treatment eligibility, or if not identified pretreatment, may later be counted as ARIA-H. A repeat baseline scan may also be indicated if it was not performed with a dedicated dementia protocol (described below), including blood sensitive sequences of sufficient diagnostic quality to identify cerebral microhemorrhages or siderosis. Therefore, poor quality brain MRIs, despite being within the 12-months prior to therapy initiation, will often necessitate repeat baseline imaging, increasing burden on radiology departments.

During the first year of anti-amyloid immunotherapy, 3-4 routine non-contrast brain MRI scans for ARIA surveillance are recommended. *Patients should undergo routine monitoring brain MRI at a minimum prior to the 5th, 7th, and 14th infusions based on the lecanemab FDA label and prior to the 2nd, 3rd, 4th, and 7th infusions based on the donanemab FDA label*^{19,26}; the exact schedule of MRI exams is likely to have some variability with different anti-amyloid immunotherapies^{20,25}. We recommend that the referring provider schedule these monitoring exams at a single imaging center, if possible, to provide a consistent MRI exam for comparison. The referring provider may also consider prospectively scheduling all these exams at the time of therapy initiation to reduce ambiguity for patients and caregivers and ensure that access to ongoing monitoring is established at the outset. Patients who develop ARIA, whether symptomatic or asymptomatic, will require additional monthly MRI scans until resolution of ARIA-E and stabilization of ARIA-H.

After the first six months (14th infusion for lecanemab), ARIA is infrequent (71% ARIA detected on the first two monitoring MRIs)¹¹, and the frequency of MRI monitoring exams is not clearly defined. The lecanemab appropriate use recommendations suggest an additional MRI prior to the 26th infusion (week 52)¹⁹. There is currently limited data on long-term therapy and monitoring, and recommendations may evolve as further experience is gained in clinical trials and clinical practice.

Patients who are on treatment and develop neurologic symptoms will require an additional brain MRI to evaluate for ARIA, typically

on an urgent or emergent basis. Note that these patients may present to emergency departments with stroke-like symptoms and could mistakenly be treated with thrombolytics based on the standard head CT performed using stroke imaging protocols, which has been associated with at least one fatality¹⁷. Thus, the radiologist should have increased vigilance when discussing findings on head CTs for patients on anti-amyloid immunotherapies and provide recommendations for further evaluation with MRI. Emergent MRI should be considered in patients for which the differential includes acute stroke vs ARIA and endovascular or, rarely, thrombolytic therapy is being considered²⁷. If MRI is not available, ARIA-E must be in the differential with acute ischemia as the etiology for hypodensity identified on head CT and as the etiology of the patient's symptoms. Outside the scenario of acute stroke management, urgent MRI should be considered to evaluate for ARIA in the symptomatic patient on anti-amyloid immunotherapy. As with other aspects of patient care, management of symptomatic patients on therapy requires a coordinated approach among radiology, neurology/treating providers, and emergency medicine.

Three Key MRI sequences: ASNR ARIA consensus sequences

In all scenarios in which a patient on anti-amyloid immunotherapy is imaged, the three critical sequences are T2* GRE (to evaluate for ARIA-H), 2D or 3D T2 FLAIR (to evaluate for ARIA-E), and DWI (to differentiate ARIA-E from acute ischemia). We will describe the rationale and details of each of these sequences and how they may be incorporated into specific imaging protocols.

1. ARIA-H detection: T2* GRE vs SWI

In clinical trials, ARIA-H detection has been performed using high quality axial T2*- GRE sequences, and the existing ARIA-H severity scoring systems are based on counts made using that sequence. Clinical trials used a GRE rather than a SWI sequence, as there is less variation in the imaging across scanners and vendors, and SWI is not available on all scanners. Specific details on the performance of this T2* GRE are published in Cogswell et al., AJNR 2022²¹; the most important of these is the TE, which should be 15-20 ms at 3T and 25-35 ms at 1.5T. *Our recommendation is unchanged: standardized axial T2* GRE with appropriate TE should be performed in all scenarios for patients receiving anti-amyloid immunotherapy: baseline/enrollment, asymptomatic ARIA monitoring, and evaluation of a patient on anti-amyloid immunotherapy presenting with new neurologic symptoms.*

Despite this recommendation, we acknowledge that other heme-sensitive sequences may be used for ARIA-H assessment and result in interpretation challenges. First, some practices are planning to run both T2* GRE and SWI on all cases to aid interpretation; obtaining both sequences may be helpful and feasible if the time for acquisition does not interfere with patient scheduling. When both sequences are obtained, we suggest that the ARIA-H findings represent the integrated interpretation of all available data (a single ARIA-H severity score for each microhemorrhages and siderosis based on information from both sequences). As SWI is more sensitive than GRE for the detection of heme products²⁸, the decision to include SWI should be performed in collaboration with your referring physicians, as this could result in a more conservative treatment approach.

Second, invariably patients may present to facilities without dedicated imaging protocols for ARIA detection, potentially be scanned under protocols that use a fast, lower quality T2* GRE or those that use a SWI. As always, the radiologist should interpret the images in the context of the entire exam, using additional sequences and prior studies for comparison. The total number of microhemorrhages or degree of siderosis should represent the radiologists' best interpretation, using all available information; referring providers will be less interested in the technique by which microhemorrhage is detected and more interested in change or stability. If the interpretation is potentially biased by technical differences, it is important to clearly state so in the report. This is the standard practice when interpreting any patient exam and is common in our assessments of other patient populations such as those with multiple sclerosis or brain metastases. Statements such as "but not new in retrospect" or "likely unchanged, given differences in technique" may be helpful. Similar to typical interpretations for studies of questionable new metastases, suggestions for follow-up can be made in equivocal cases.

2. ARIA-E detection: T2-weighted FLAIR

Clinical trials have previously used 2D T2 FLAIR for ARIA-E detection. However, 3D T2 FLAIR is now standard in clinical protocols at some institutions. Our recommendation for T2 FLAIR imaging is unchanged: we support the use of either 2D or 3D T2 FLAIR, whichever can be routinely performed with high quality in your practice. If 3D T2 FLAIR is implemented, multiplanar reformation in the axial plane is recommended to facilitate interpretations when comparing with scans from other institutions that may use an axial 2D acquisition. Given that 3D FLAIR sequences are more immune to flow artifacts in the CSF that might be confused with ARIA-E sulcal effusion²⁹, they may be preferred, especially for problem solving.

3. Ischemia detection: DWI

DWI is recommended to evaluate for acute ischemia and differentiate that from ARIA-E. If a practice routinely performs DTI, providing and interpreting the DWI trace images and ADC map is required, as is standard clinical practice.

Imaging protocols: 3 patient scenarios, 3 key sequences

For the baseline/enrollment exam, we recommend a non-contrast brain MRI including the ARIA consensus T2 FLAIR, T2* GRE, and DWI as well as other standard sequences in your practice's dementia protocol (**Table 1**). For asymptomatic ARIA monitoring, the protocol may be simplified to just the 3 ARIA consensus sequences, which could be performed in an abbreviated imaging slot and allow for greater access for patients if the MRI scheduling is a bottleneck in the local care pathway. For symptomatic patients, in addition to ARIA, a full differential diagnosis such as infarct, tumor/metastases, and infection must be considered; thus, the MRI protocol would be tailored based on the clinical presentation. Ideally, this protocol would also include the three ARIA consensus sequences.

Practices may choose to include additional sequences according to their imaging capabilities and preferences, and for problem-solving individual cases. For example, a T2 sequence may be added to help troubleshoot indeterminate findings on T2 FLAIR and GRE (e.g.,

blood vessels) on a monitoring exam. Note, post-contrast imaging is not recommended at baseline or monitoring of asymptomatic patients, and its use may result in unwarranted costs, patient risks, and extended exam durations. However, for symptomatic presentations, contrast may be indicated for fully evaluating the differential diagnosis based on the clinical presentations.

Table 1: Summary of recommendations based on three patient scenarios.

	Baseline / enrollment evaluation	Asymptomatic monitoring	Symptomatic patient on therapy
Order	MRI brain dementia without IV contrast (indication: AD therapy enrollment)	MRI brain without IV contrast (indication: AD therapy monitoring)	MRI brain without (and with) IV contrast (indication: AD therapy, new symptoms)
Protocol	“AD therapy enrollment”	“AD therapy monitoring”	“AD therapy monitoring”
Minimum Sequences	2D or 3D T2 FLAIR GRE* ± SWI DWI 3D T1 T2 FSE	2D or 3D T2 FLAIR GRE* ± SWI DWI	2D or 3D T2 FLAIR GRE* ± SWI DWI ± additional sequences
Reporting template	“AD therapy enrollment”	“AD therapy monitoring”	“AD therapy monitoring”
Key findings	Microhemorrhages Siderosis White matter hyperintensities Infarcts	ARIA-E (edema, effusion) ARIA-H (new microhemorrhages, siderosis)	ARIA-E ARIA-H Other acute findings
Recommended communication	Standard reporting	Mild ARIA -> notification required Moderate or severe ARIA -> closed loop communication	

*GRE must be performed with an appropriate TE, 3T TE 15-20 ms, 1.5T TE 25-35 ms.

MRI brain orders

As different protocols are recommended for each of the three patient scenarios described, obtaining the appropriate protocol may be facilitated by unique orders for each. Specific orders for the baseline/enrollment evaluation, asymptomatic ARIA monitoring, and symptomatic patient receiving anti-amyloid immunotherapy may be considered and linked to distinct imaging protocols and reporting templates.

For AD therapeutics baseline/enrollment evaluation, the order may trigger the exam code MRI brain dementia without IV contrast with exam indication “AD therapeutics enrollment”. Utilizing the same imaging protocols for the indication “AD therapeutics enrollment” and for the standard “dementia evaluation” may reduce the need for repeat imaging at the time of the baseline evaluation, prior to the initiation of anti-amyloid immunotherapy.

An “AD therapeutics/ARIA monitoring” order may trigger exam code MRI brain without IV contrast with indication “AD therapeutics monitoring”. For monitoring, an order specific to AD therapeutics could serve to indicate that the dedicated imaging protocol should be performed and, via exam indication, also alert the radiologist to the purpose of the exam. Ideally, the date of treatment initiation should be included in the clinical indication for each monitoring brain MRI to facilitate appropriate comparison with the baseline and most recent prior exams.

For symptomatic patients on anti-amyloid immunotherapy, the “AD therapeutics/ARIA monitoring” order may be used, with additional sequences based on the clinical presentation. The exam indication will be particularly important when patients on treatment are being evaluated for new symptoms, where the context of anti-amyloid immunotherapy is critical to distinguishing probable ARIA from radiologic mimics.

Field strength

FDA labels do not specify a field strength for brain MRI exams to monitor for ARIA. Clinical trial imaging has been largely performed at 3 Tesla (T), with imaging at 1.5T for a subset of sites and patients, and 1.5T is the lowest field strength used in trials. Use of a lower field strength may result in underdiagnosis of ARIA-H because the effects of magnetic susceptibility scale with field strength²⁸. Practitioners should be aware that microhemorrhages may only variably be detected on lower field strength scanners (e.g. ~0.5T or open scanners) and are not visible on current ultra-low field scanners (e.g., 0.06 T). *In summary, our recommendation for scanner field strength in AD therapeutics imaging is unchanged: 3T is recommended, 1.5T and greater is adequate, and less than 1.5T is inadequate.* To increase overall capacity and meet growing demand for MRI, further research regarding detection of ARIA with lower field strengths would be helpful.

Standardization

Standardized imaging is important in ARIA evaluations as it facilitates the use of standardized assessment and treatment criteria and the ability to compare findings among serial MRI exams in an individual patient. Ideally, a patient would be imaged with the same field strength, vendor, and scanner model, using the same sequences and sequence parameters across serial exams (**Figure 2**). However, that level of consistency is typically not feasible in clinical practice given that a patient may not be imaged at the same imaging center over serial visits and, even at a single imaging center, there may be a diverse fleet of MRI scanners. Imaging on the same MR vendor is important to prevent ARIA-E mimics due to differential appearance of white matter hyperintensities between vendors²¹. Imaging at the same field strength is more important for ARIA-H detection given that the sensitivity for detecting heme products scales with magnetic field strength. The use of harmonized protocols (similar sequences and sequence parameters) across the scanners in a practice would standardize

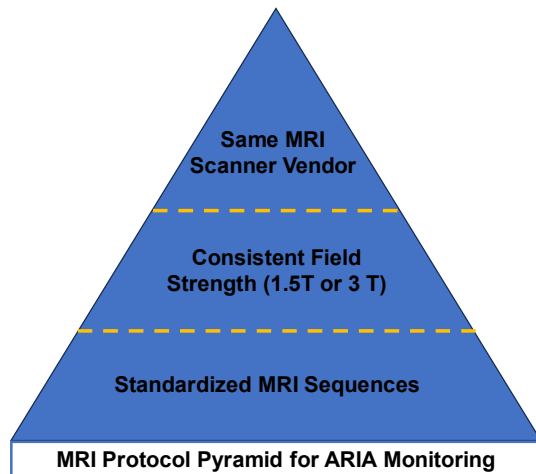


FIG 2. Pyramid of MRI protocol standardization. Ideally, patients are imaged using the same sequences and sequence parameters across serial exams, on the same field strength, vendor, and scanner model. If a patient cannot be imaged on the same scanner across serial exams, radiologists must be aware of differences that may affect ARIA evaluation. Most importantly, at the pyramid base, a standardized set of MRI sequences should be employed. Of next importance is the field strength, as sensitivity for heme products scales proportionally. Third, a patient would ideally be imaged on the same scanner vendor to prevent ARIA mimics based on differential appearance of white matter hyperintensities between vendors.

may be encouraged to obtain a copy of their baseline (+/- subsequent) MRI exams and have these studies available at monitoring visits. If the radiologist does not have a prior scan for comparison, a negative scan is conclusive (no ARIA). However, accurate detection of mild ARIA-E will be hindered, and if microhemorrhage are present, an accurate ARIA-H microhemorrhage severity score would not be possible without comparison with the baseline MRI.

Reporting

We recommend use of a templated report (see Resources section at <https://www.asnr.org/education-resources/alzheimers-webinar-series/>), which will guide the reader through reporting of the relevant findings for baseline/enrollment and monitoring MRI exams. An example of the temporal evolution of ARIA and example ARIA reporting are shown in **Figure 3** and the **Online Supplemental Data**.

For the baseline/enrollment MRI exam, the report should include the relevant exclusionary findings. The ANA white paper recommends consideration of the number of baseline microhemorrhages, regions of superficial siderosis, number of lacunar infarcts and infarcts involving a major vascular territory, and the extent of baseline white matter hyperintensity, graded using the Fazekas scale^{19,20,30}. These can be combined in a single section of the radiology findings, as in the reporting templates.

*For the ARIA monitoring exams, the report must include all relevant findings to arrive at an ARIA severity score – treatment emergent edema/sulcal effusion, and cumulative numbers of treatment emergent microhemorrhages and regions of superficial siderosis (**Figure 1**).* These findings will be used along with clinical symptoms to determine the patient's eligibility for continued drug dosing. In addition to

evaluation regardless of the scanner used.

To facilitate standardization, the ASNR has collaborated with GE HealthCare, Philips, and Siemens Healthineers to create standardized T2 FLAIR, T2* GRE, and DWI ARIA consensus protocols which can be directly imported into scanners through established vendor support. Each vendor has developed protocols based on the above recommendations and those provided in the prior publication by Cogswell et al (e.g. 2D slice thickness of 4 mm)²¹ and harmonized the sequences across their fleet of scanners. The base protocol from each vendor includes a 2D T2 FLAIR, T2* GRE, and DWI than can be performed in < 15 minutes of gradient time. The following are provided as optional sequences: 3D T2 FLAIR (may be used in place of 2D T2 FLAIR), SWI (may be used in addition to T2* GRE), and 3D T1. These protocols are posted on the ASNR website (<https://www.asnr.org/education-resources/alzheimers-webinar-series/>) and will be available in the product protocol trees. This harmonization is a major accomplishment for standardization in patient care and should help to decrease variability of interpretation of ARIA.

INTERPRETATION AND REPORTING WORKFLOWS

Interpretation

As ARIA is a new entity in the field of clinical imaging, education and training are important to ensure accuracy and consistency in reporting. Ongoing training and CME are available through the ASNR (<https://www.asnr.org/education-resources/alzheimers-webinar-series/>), ACR, Alzheimer's Association, RSNA, pharmaceutical companies, and during specialty meetings.

Comparison with prior exams (baseline and most recent prior) is necessary for ARIA assessment. As with other aspects of the evaluation, the comparison with prior exams will be aided by the patient consistently receiving care in the same imaging system. If such consistency of care is not possible, prior imaging could be made available via a central patient registry, such as ALZ-NET (alz-net.org). Additionally, patients

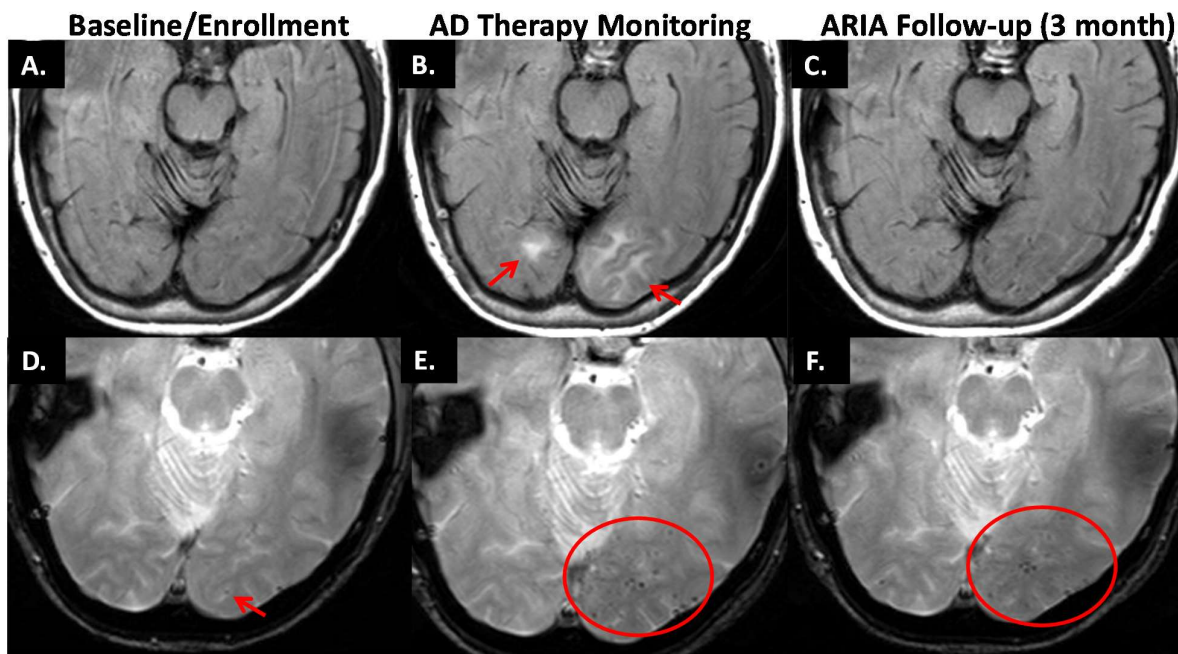


FIG 3. Temporal evolution of ARIA and reporting. AD Therapy Enrollment (A, D): Axial T2 FLAIR shows mild white matter hyperintensities (incompletely imaged in show slice) and no infarcts (A). GRE shows one left occipital microhemorrhage (arrow) and no superficial siderosis (D). AD Therapy Monitoring (B, E): T2 FLAIR shows new T2 hyperintense signal/edema in the left greater than right occipital white matter measuring up to 3.6 cm in greatest linear dimension. Based on two regions of signal abnormality, this is moderate ARIA-E (B). GRE shows a total of 13 new microhemorrhages (only some shown on this slice), severe ARIA-H microhemorrhages, and no ARIA-H siderosis (E). The patient was followed with monthly MRIs until the resolution of ARIA-E and stabilization of ARIA-H, which occurred after 3 months (C, F). T2 FLAIR shows resolution of occipital T2 signal abnormality, and no new FLAIR signal abnormality. No ARIA-E (C). GRE shows no new microhemorrhages. There is a total of 14 microhemorrhages, 1 unchanged from baseline, and 13 treatment emergent. Unchanged severe ARIA-H (F). See the Online Supplemental Data for example templated reporting of these findings. Images courtesy of DIAN.

use of a reporting template, marking findings on exams is helpful. Findings may be marked with an arrow or similar notation, labeled as “new” on date first identified, and/or listed with image numbers in the report to assist tracking over serial exams. Clearly describing number of pre-existing and new ARIA findings will help providing a total count; both may influence treatment decisions. If the radiologist cannot adequately assess for ARIA, for example due to patient motion, lack of or poor-quality GRE/SWI, that should be stated in the report. Inclusion of standardized MRI sequences and reporting in the baseline and ARIA monitoring MRI exams will provide the details needed for treatment decisions and can help to reduce the burden on the clinical practice by decreasing the number of “second reads” and repeat MRI exams.

An example of a streamlined workflow integrating MRI orders, protocols, and templates is as follows: A unique orderable is created for both “AD therapy enrollment” (MRI brain dementia without IV contrast) and “AD therapy monitoring” (MRI brain without IV contrast). These orders specify a set of scanners on which exams should be scheduled and indicate the appropriate imaging protocol. Finally, the use of a unique orderable allows the appropriate reporting template (“AD therapy enrollment” or “AD therapy monitoring”) to auto-populate when the exam is opened for interpretation.

Communication

The radiologist will play an important role in the decisions to enroll and maintain patients on treatment based on relevant MRI findings. Communication between ordering providers and radiologists will be critical in all encounters, including baseline assessment, asymptomatic monitoring, and during workup of symptoms, when the radiologist must entertain a broad differential diagnosis.

Nonroutine communication is recommended for findings of ARIA. When there is mild ARIA, notification is required (e.g., automated message or communication via assistant). Moderate to severe ARIA requires closed loop urgent communication. This communication is important as ARIA findings along with clinical symptoms will be used to make treatment decisions, and there may be a mismatch between radiographic severity and symptoms. Either can trigger further necessary action.

Computer-aided detection

AI computer-automated detection (CAD) solutions are in active development to aid neuroradiologists in ARIA reporting through the development of quantitative ARIA monitoring reports. The automated quantitative software may provide the location and count of new microhemorrhages/superficial siderosis (ARIA-H), as well as measure the greatest dimension and volume of edema/sulcal effusions (ARIA-E). The reports may provide longitudinal data across serial MRI scans and display criteria for grading ARIA as mild, moderate, or

severe in the correct clinical construct. The ability to directly insert these findings into the radiologist's dictation through an automated "pre-populated reporting template" may facilitate reporting. As always, these tools are considered an adjunct to neuroradiologic interpretation.

PRACTICAL CONSIDERATIONS

Patient access to MRI at timely intervals for follow-up imaging during treatment may be challenging at many sites if volumes increase as projected. Many practices are already facing limited MRI scanner slot availability due to pre-existing system overload secondary to a combination of increasing volume from multiple patient populations, a shortage of qualified MRI technologists to staff exams, and aging MRI systems. To increase capacity, patients may receive ongoing infusions and MRI monitoring at a center that is different than that of their initial evaluation based on availability. It is important that radiologists adopt standardized acquisition and reporting protocols for MRI in this situation to avoid miscommunication between providers and provide optimal care for patients undergoing anti-amyloid immunotherapy regardless of the practice setting.

One approach to improving access to MRI is to reduce the imaging time per patient, which may be achieved by limiting the number of sequences acquired or reducing the time per sequence. As discussed above, conventional brain imaging protocols may be truncated to include only the most essential sequences for ARIA assessment (T2 FLAIR, T2* GRE, and DWI) (**Table 1**). To reduce sequence time, practices may consider implementing accelerated MR imaging techniques, such as compressed sensing and/or AI-based reconstructions^{31,32}.

Another challenge practices will face will be how to handle patients with special MRI requirements, such as claustrophobia, cardiac implantable electronic devices (CIEDs), spinal stimulators, and other implanted devices. These exams typically necessitate specialized imaging personnel such as an MR safety officer (MRSO) or MR physicist safety expert (MRSE) to perform safely and are not easily scalable to large populations. Therefore, per appropriate use recommendations²⁷, patients unable to undergo a routine brain MRI may be excluded from treatment. However, in practices with the required resources, imaging and treatment of such patients may be feasible, likely at 1.5T, provided that the ability to obtain emergent imaging in case of potential side effects is clarified. In these cases, coordinated care between the referring provider, patient, and radiologist will be needed to assess risk and benefit.

INTEGRATED CARE

Coordinated care among multidisciplinary providers will be important to provide the best patient care and streamline evaluation. In this article, we focused on the brain MRI, one of multiple tests expected to be performed to evaluate patient eligibility for anti-amyloid immunotherapy. In the setting of a coordinated evaluation, MRI would best be performed early in the evaluation, prior to amyloid status assessment, such that if there are exclusionary findings in the MRI the more costly and/or invasive amyloid PET or lumbar puncture may be avoided. Once the data is in hand, providers must determine patient eligibility for treatment, which will include integration of AD biomarker data, brain MRI findings, and clinical exam, among others. Multidisciplinary input may be particularly valuable as providers begin to navigate the application of the inclusion/exclusion criteria and appropriate use recommendations in real-world clinical practice. The degree to which such integration of care can be achieved will necessarily vary across different centers depending on availability of clinical as well as imaging resources.

ASNR ARIA SURVEY RESULTS

In July 2023, a survey was sent to all ASNR members with the goal to gauge the radiology community's preparedness and capacity to image patients receiving anti-amyloid immunotherapies. There was a total of 221 respondents of which, 154 (69.7%) practiced in academic medical centers. Respondents reported variable degrees of confidence in the ability to identify ARIA on a brain MRI (**Figure 4**). Less than half of respondents (39.4%) had specific MRI protocols in place for AD therapeutics imaging. For the practices with protocols in place, the majority planned to use 3T (90.2%) and 1.5T (70.7%) field strength scanners, and imaging sequences included in the protocol varied among practices. See the Supplemental Material and Figures for the full survey results.

CONCLUSION

The advent of disease modifying treatments for AD heralds a new era of hope for patients and families with mild cognitive impairment and early dementia due to AD. Treatment with anti-amyloid immunotherapy requires multiple brain MRIs. To assist radiology practices with these new demands, we have outlined three patient scenarios: baseline/enrollment, asymptomatic ARIA monitoring, and the symptomatic patient on therapy. In each of these three scenarios it is important to obtain three key brain MRI sequences (T2 FLAIR, T2* GRE, and DWI) that can be implemented in a standardized fashion to improve access to care and to standardize interpretation of results. In partnership with industry, these are now available from each of the major MRI vendors. We have also updated the prior ASNR recommendations to specifically address questions regarding workflows, reporting, communication of findings, specific patient scenarios which may require individualized care, and future directions for research. These efforts address the most pressing needs of the neuroradiology community, as indicated by our recent survey. As we continue to gain experience and knowledge with these therapies, we will share that information and update these imaging recommendations with the community via future publications and webinars.

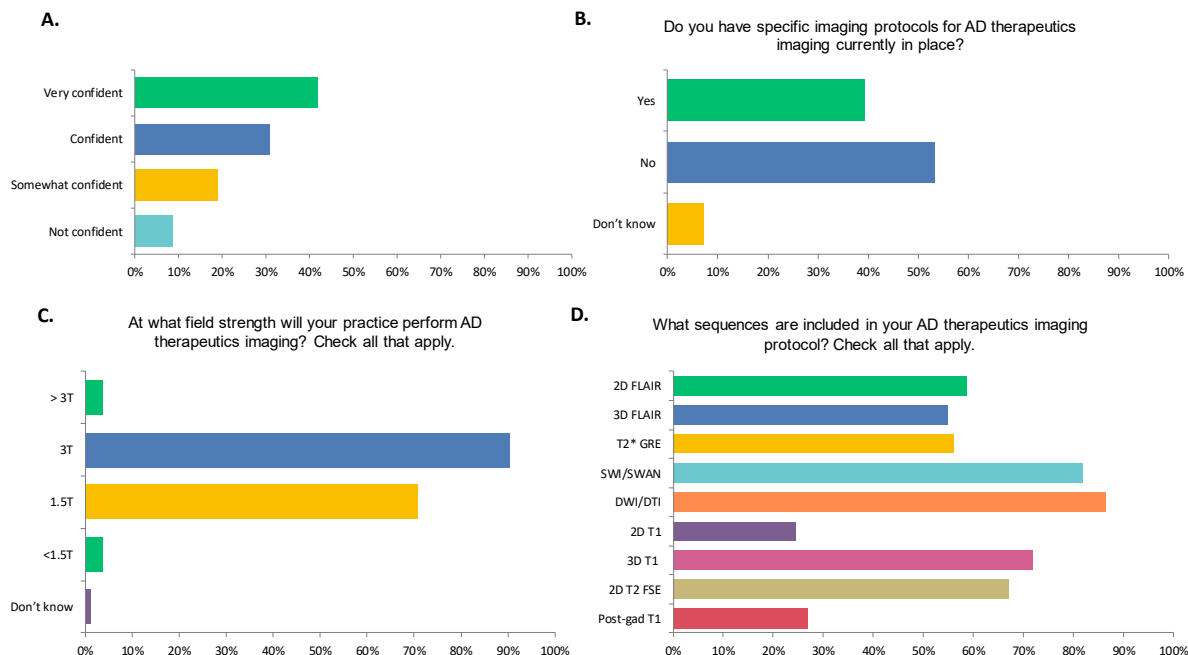


FIG 4. Selected results from the 2023 ASNR survey gauging practice readiness for AD therapeutics imaging. (A) How confident are you in your ability to identify ARIA on a brain MRI? (B) Do you (your practice) have specific imaging protocols in place for AD therapeutics imaging? (C) At what field strengths will your practice perform AD therapeutics imaging? (D) What sequences are including in your AD therapeutics imaging protocol?

ACKNOWLEDGEMENTS

We thank our colleagues at GE HealthCare, Philips, and Siemens Healthineers for their collaboration in providing standardized protocol for AD therapeutics imaging and Biogen and the Dominantly Inherited Alzheimer's Network (DIAN) for images.

REFERENCES

- Honce JM, Nagae L, Nyberg E. Neuroimaging of Natalizumab Complications in Multiple Sclerosis: PML and Other Associated Entities. *Multiple Sclerosis International* 2015;2015:e809252.
- Wattjes MP, Vennegoor A, Steenwijk MD, et al. MRI pattern in asymptomatic natalizumab-associated PML. *J Neurol Neurosurg Psychiatry* 2015;86:793–8.
- Rong L, Li N, Zhang Z. Emerging therapies for glioblastoma: current state and future directions. *Journal of Experimental & Clinical Cancer Research* 2022;41:142.
- Sperling RA, Jack CR, Black SE, et al. Amyloid Related Imaging Abnormalities (ARIA) in Amyloid Modifying Therapeutic Trials: Recommendations from the Alzheimer's Association Research Roundtable Workgroup. *Alzheimers Dement* 2011;7:367–85.
- Barakos J, Sperling R, Salloway S, et al. MR Imaging Features of Amyloid-Related Imaging Abnormalities. *American Journal of Neuroradiology* 2013;34:1958–65.
- Salloway S, Chalkias S, Barkhof F, et al. Amyloid-Related Imaging Abnormalities in 2 Phase 3 Studies Evaluating Aducanumab in Patients With Early Alzheimer Disease. *JAMA Neurology* <https://doi.org/10.1001/jamaneurol.2021.4161>.
- Salloway S, Sperling R, Fox NC, et al. Two Phase 3 Trials of Bapineuzumab in Mild-to-Moderate Alzheimer's Disease. *New England Journal of Medicine* 2014;370:322–33.
- Ostrowitzki S, Lasser RA, Dorflinger E, et al. A phase III randomized trial of gantenerumab in prodromal Alzheimer's disease. *Alzheimers Res Ther* 2017;9:95.
- Swanson CJ, Zhang Y, Dhadda S, et al. A randomized, double-blind, phase 2b proof-of-concept clinical trial in early Alzheimer's disease with lecanemab, an anti-A β protofibril antibody. *Alzheimer's Research & Therapy* 2021;13:80.
- Doody RS, Thomas RG, Farlow M, et al. Phase 3 Trials of Solanezumab for Mild-to-Moderate Alzheimer's Disease. *New England Journal of Medicine* 2014;370:311–21.
- van Dyck CH, Swanson CJ, Aisen P, et al. Lecanemab in Early Alzheimer's Disease. *New England Journal of Medicine* 2023;388:9–21.
- Mintun MA, Lo AC, Duggan Evans C, et al. Donanemab in Early Alzheimer's Disease. *New England Journal of Medicine* 2021;384:1691–704.
- Greenberg SM, Bacskai BJ, Hernandez-Guillamon M, et al. Cerebral amyloid angiopathy and Alzheimer disease — one peptide, two pathways. *Nat Rev Neurol* 2020;16:30–42.
- Zago W, Schroeter S, Guido T, et al. Vascular alterations in PDAPP mice after anti-A β immunotherapy: Implications for amyloid-related imaging abnormalities. *Alzheimer's & Dementia* 2013;9:S105–15.
- Carlson C, Siemers E, Hake A, et al. Amyloid-related imaging abnormalities from trials of solanezumab for Alzheimer's disease. *Alzheimer's & Dementia: Diagnosis, Assessment & Disease Monitoring* 2016;2:75–85.
- VandeVrede L, Gibbs DM, Koestler M, et al. Symptomatic amyloid-related imaging abnormalities in an APOE ϵ 4/ ϵ 4 patient treated with aducanumab.

- Alzheimer's & Dementia: Diagnosis, Assessment & Disease Monitoring 2020;12:e12101.
17. Reish NJ, Jamshidi P, Stamm B, et al. Multiple Cerebral Hemorrhages in a Patient Receiving Lecanemab and Treated with t-PA for Stroke. *N Engl J Med* 2023;388:478–9.
 18. Sevigny J, Chiao P, Bussière T, et al. The antibody aducanumab reduces A β plaques in Alzheimer's disease. *Nature* 2016;537:50–6.
 19. Cummings J, Apostolova L, Rabinovici GD, et al. Lecanemab: Appropriate Use Recommendations. *J Prev Alzheimers Dis* <https://doi.org/10.14283/jpad.2023.30>.
 20. Cummings J, Rabinovici GD, Atri A, et al. Aducanumab: Appropriate Use Recommendations Update. *J Prev Alzheimers Dis* <https://doi.org/10.14283/jpad.2022.34>.
 21. Cogswell PM, Barakos JA, Barkhof F, et al. Amyloid-Related Imaging Abnormalities with Emerging Alzheimer Disease Therapeutics: Detection and Reporting Recommendations for Clinical Practice. *AJNR Am J Neuroradiol* <https://doi.org/10.3174/ajnr.A7586>.
 22. Campbell MR, Ashrafzadeh-Kian S, Petersen RC, et al. P-tau/A β 42 and A β 42/40 ratios in CSF are equally predictive of amyloid PET status. *Alzheimers Dement (Amst)* 2021;13:e12190.
 23. Hansson O, Blennow K, Zetterberg H, et al. Blood biomarkers for Alzheimer's disease in clinical practice and trials. *Nat Aging* 2023;3:506–19.
 24. Pittock RR, Aakre JA, Castillo AM, et al. Eligibility for Anti-Amyloid Treatment in a Population-Based Study of Cognitive Aging. *Neurology* 2023;101:e1837–49.
 25. ADUHELM® (aducanumab-avwa) is FDA Approved | For Healthcare Professionals.
 26. Drugs@FDA: FDA-Approved Drugs.
 27. Ramanan VK, Armstrong MJ, Choudhury P, et al. Anti-amyloid Monoclonal Antibody Therapy for Alzheimer Disease: Emerging Issues in Neurology. *Neurology* <https://doi.org/10.1212/WNL.000000000000207757>.
 28. Nandigam RNK, Viswanathan A, Delgado P, et al. MR Imaging Detection of Cerebral Microbleeds: Effect of Susceptibility-Weighted Imaging, Section Thickness, and Field Strength. *AJNR Am J Neuroradiol* 2009;30:338–43.
 29. Kallmes DF, Hui FK, Mugler JP. Suppression of Cerebrospinal Fluid and Blood Flow Artifacts in FLAIR MR Imaging with a Single-Slab Three-dimensional Pulse Sequence: Initial Experience. *Radiology* 2001;221:251–5.
 30. Fazekas F, Chawluk J, Alavi A, et al. MR signal abnormalities at 1.5 T in Alzheimer's dementia and normal aging. *American Journal of Roentgenology* 1987;149:351–6.
 31. Polak D, Cauley S, Huang SY, et al. A highly-accelerated volumetric brain examination using optimized Wave-CAIPI encoding. *J Magn Reson Imaging* 2019;50:961–74.
 32. Bash S, Wang L, Airriess C, et al. Deep Learning Enables 60% Accelerated Volumetric Brain MRI While Preserving Quantitative Performance: A Prospective, Multicenter, Multireader Trial. *AJNR Am J Neuroradiol* 2021;42:2130–7.

SUPPLEMENTAL FILES

Example Reporting for AD Therapy Enrollment and AD Therapy Monitoring Exams

The below are examples of how the key findings for the AD Therapy Enrollment and AD Therapy Monitoring exams may be reported, based on use of the recommended reporting templates. These reports correspond to the findings shown in **Figure 3** of the main document.

(A, D) AD Therapy Enrollment:

Treatment relevant findings:

- Total microhemorrhages: 1 left occipital lobe (series 4, image 17)
- Superficial siderosis: None
- White matter hyperintensities: mild
- Infarcts: none

(B, E) AD Therapy Monitoring:

ARIA FINDINGS

ARIA-E

- Prior FLAIR hyperintensities concerning for ARIA-E: none
- New/incident FLAIR hyperintensities concerning for ARIA-E: New T2 hyperintense signal in the right occipital white matter measuring up to 1.2 cm and in the left occipital lobe measuring up to 3.6 cm.
- Total current regions of FLAIR hyperintensities concerning for ARIA-E: 2

ARIA-H Microhemorrhages

- Microhemorrhages at pre-treatment baseline: 1 left occipital lobe
- Prior treatment emergent microhemorrhages (ARIA-H): 0
- New microhemorrhages (ARIA-H): 13 left occipital lobe
- Total treatment emergent microhemorrhages (ARIA-H) = prior treatment emergent + new microhemorrhages: ≥ 10

ARIA-H Siderosis

- Prior treatment emergent siderosis (ARIA-H): none
- New siderosis (ARIA-H): none
- Total treatment emergent focal areas of superficial siderosis: 0

IMPRESSION:

- Findings of moderate ARIA-E.
- Findings of severe ARIA-H microhemorrhages.
- Findings of no ARIA-H siderosis.

(C,F) AD Therapy Monitoring:

ARIA FINDINGS

ARIA-E

- Prior FLAIR hyperintensities concerning for ARIA-E: right and left occipital
- New/incident FLAIR hyperintensities concerning for ARIA-E: none
- Total current regions of FLAIR hyperintensities concerning for ARIA-E: 0

ARIA-H Microhemorrhages

- Microhemorrhages at pre-treatment baseline: 1 left occipital
- Prior treatment emergent microhemorrhages (ARIA-H): 13 left occipital lobe
- New microhemorrhages (ARIA-H): 0
- Total treatment emergent microhemorrhages (ARIA-H) = prior treatment emergent + new microhemorrhages: ≥ 10

ARIA-H Siderosis

- Prior treatment emergent siderosis (ARIA-H): none
- New siderosis (ARIA-H): none
- Total treatment emergent focal areas of superficial siderosis: 0

IMPRESSION:

- Findings of no ARIA-E. Interval resolution of ARIA-E since the prior MRI.
- Findings of severe ARIA-H microhemorrhages, unchanged from prior MRI.
- Findings of no ARIA-H siderosis.

ASNR ARIA Survey Results

In July 2023, a survey was sent to all ASNR members with the goal to gauge the radiology community's preparedness and capacity to image patients receiving AD therapeutics.

There were a total of 221 respondents. Of these, 154 (69.7%) practiced in academic medical centers, 71 (32.1%) in academic outpatient practices, 43 (19.5%) in outpatient-based private practices, 41 (18.6%) in hospital-based private practices, and 13 (5.9%) respondents listed their practice setting as "other" (**Supplemental Figure 1**). The majority of respondents work at practices with 11-20 neuroradiologists (35.8%), followed by 5-10 neuroradiologists (28.5%), <5 neuroradiologists (22.6%), and >20 neuroradiologists (12.2%) (**Supplemental Figure 2**). Regarding MRI capacity, the majority of respondents work at practices with 11-20 MRI scanners (27.6%), followed by 5-10 MRI scanners (26.2%), >20 MRI scanners (22.6%), <5 scanners (20.4%), while 7 respondents (3.2%) were not certain of the number of MRI scanners at their practice (**Supplemental Figure 3**).

An overwhelming majority of the respondents (91.4%) were aware of ARIA as a diagnostic entity (**Supplemental Figure 4**). Furthermore, the majority of the respondents were confident in their ability to identify ARIA on diagnostic MRI studies (41.7% - very confident, 30.8% - confident, 19.0% - somewhat confident) (**Supplemental Figure 5**). These results are likely biased by those interested in and aware of ARIA being more likely to respond to the survey; we expect that a smaller percentage of neuroradiologists and general radiologists overall are aware of ARIA.

When an urgent outpatient MRI is needed, it may be obtained within 24 hours at many of these practices (43.0%), followed by 48 hours (19.9%), 72 hours (12.7%), while in only a minority of practices it takes >72 hours to obtain an urgent outpatient MRI (13.1%) (**Supplemental Figure 6**). Moreover, the majority of respondents were confident that their practice would be able to accommodate additional volumes of 20 MRI brain studies without contrast per week (21.7% - very confident, 25.3% - confident, 27.6% - somewhat confident) (**Supplemental Figure 7**). The greatest barriers to accommodating the anticipated increase in MRI volumes include MR scanner capacity (53.4%), technologist staffing (27.2%), neuroradiologist staffing (13.6%), and MR scanner capability (3.2%) (**Supplemental Figure 8**). Per the respondents, potential solutions that may be implemented to meet increased demand include expanded hours of MR operation (74.7%), additional permanent scanners (40.8%), use of CT for monitoring of asymptomatic patients (17.7%), mobile units (14.9%), and the use of low field units (12.2%) (**Supplemental Figure 9**). As expected, the results indicate the belief that growth in our imaging infrastructure, scanners, and personnel, may be needed to meet patient demands for AD therapeutics, among other entities. Another way to meet increased demands, overlooked in our prepopulated responses, but indicated in free text and in line with our imaging recommendations, is to use accelerated imaging sequences and truncated imaging protocols.

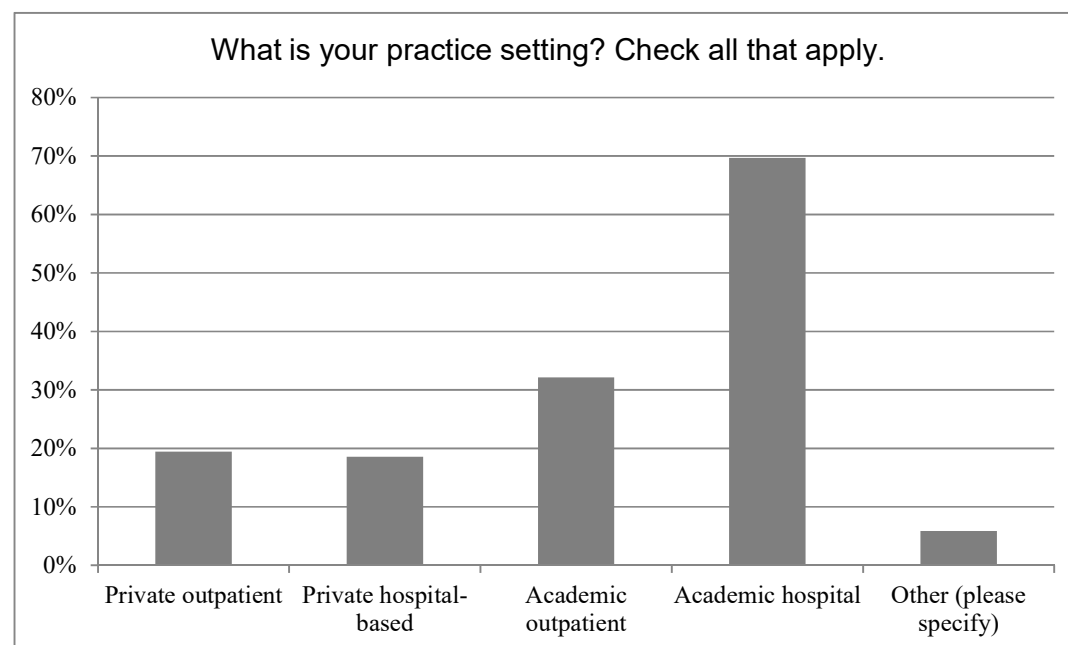
Currently, less than half of respondents (39.4%) have specific MRI protocols in place for AD therapeutics imaging (**Supplemental Figure 10**). For the practices with protocols in place, the majority will use 3T (90.2%) and 1.5T (70.7%) field strength scanners, followed by >3T (3.7%), <1.2T (2.4%), and 1.2T (1.2%) (**Supplemental Figure 11**). The sequences practices have

implemented for AD therapeutics imaging include DWI/DTI (86.6%), 3D susceptibility weighted imaging (81.7%), 3D T1 (72.0%), axial 2D T2 FSE (67.1%), 2D T2 FLAIR (58.5%), axial T2* GRE (56.10%), 3D T2 FLAIR (54.9%), post-gad T1 (26.8%), 2D T1 (24.4%), ASL (8.5%), MRA (4.9%), and vessel wall imaging (3.7%) (**Supplemental Figure 12**). These results highlight that the three key recommended sequences are not currently included in all practices' AD therapeutics imaging protocols, and there is a need for education and standardization of the assessment protocol. Note that respondents could mark all included sequences. Based on the numbers, we assume all practices will run either a 2D or 3D T2 FLAIR and a few may run both. Despite our recommendation for the use of GRE in the prior white paper, more practices plan to run SWI than GRE. Most, but not all, practices plan to include DWI/DTI. A surprisingly large percentage of practices plan to give gadolinium for AD therapeutics monitoring; as discussed, we do not recommend its use in asymptomatic monitoring.

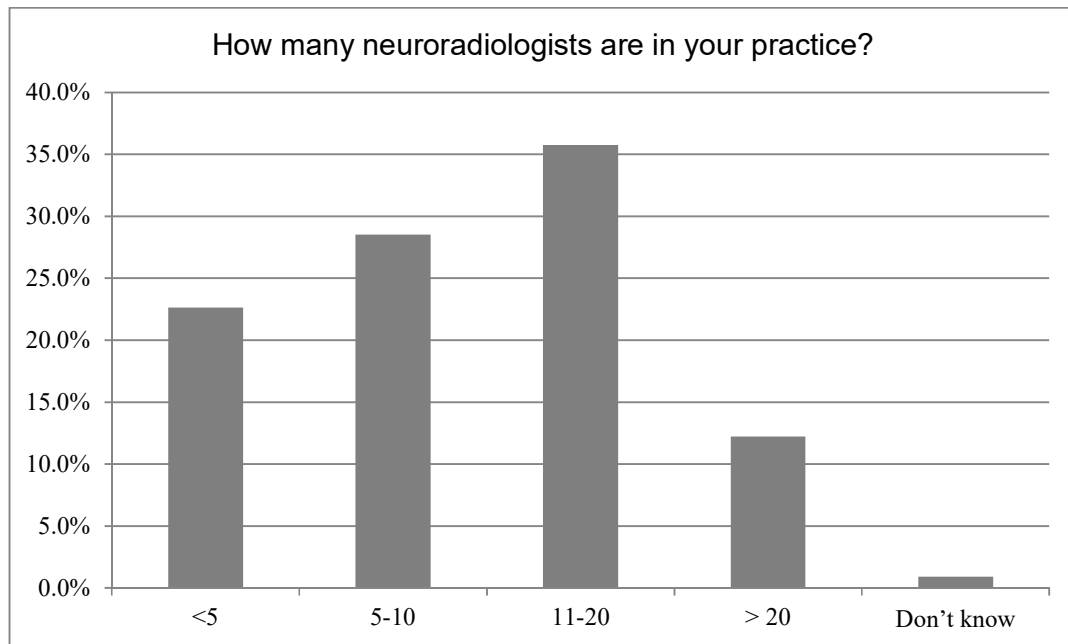
The majority of respondents would consider using proprietary computer aided diagnosis (CAD) tools for both ARIA-H (62.4%) and ARIA-E (63.3%) detection (**Supplemental Figures 14 and 14**). This is an area for further development and education in the future.

Per the respondents, the ASNR can best assist in preparation for AD therapeutic imaging by providing educational cases (80%), imaging protocols (70.5%), webinars (69.1%), reporting templates (68.6%), reimbursement advocacy (52.9%), and workflow education (37.1%) (**Supplemental Figure 15**). Meanwhile, industry can best provide support by providing protocol optimization (70.0%), automated detection/computer aided diagnosis (62.9%), educational cases (51.4%), technology – central protocols (51.0%), consistent protocol operation (46.2%), and financial support for education (37.6%) (**Supplemental Figure 16**). We have or will be addressing each of these areas. Education cases and webinars on ARIA education are currently on the ASNR website and publications (<https://www.asnr.org/education-resources/alzheimers-webinar-series/>). We have collaborated with the major MR vendors to provide imaging protocols, which are also available via the above website. We have updated the baseline MRI reporting template since the prior paper to include additional features of cerebrovascular disease that may be exclusionary. Workflow considerations were discussed in the August 2023 ASNR webinar and at the ASNR 2024 meeting session. Future work and collaborations with other societies are warranted to promote reimbursement advocacy.

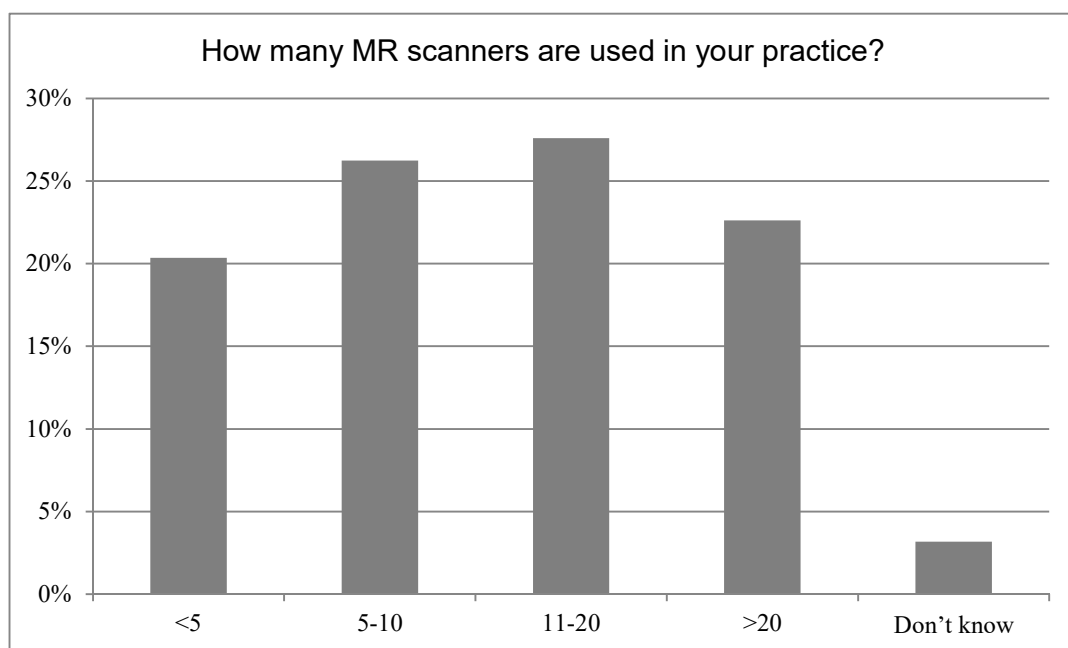
SUPPLEMENTAL FIGURES



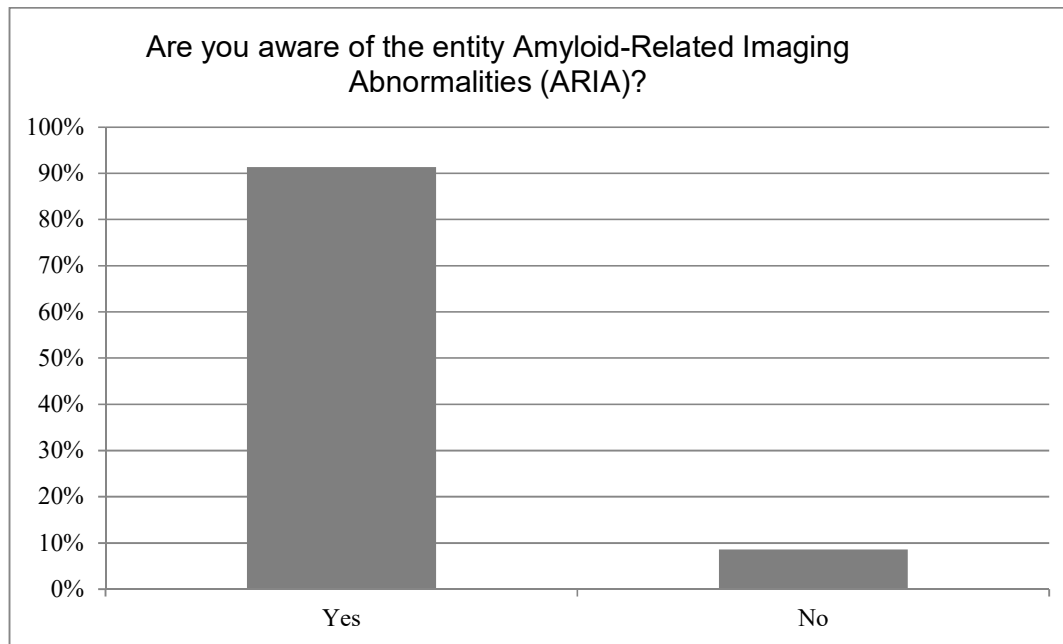
Supplemental Figure 1: Practice setting of the respondents.




Supplemental Figure 2: Number of neuroradiologists in the practices of the respondents.



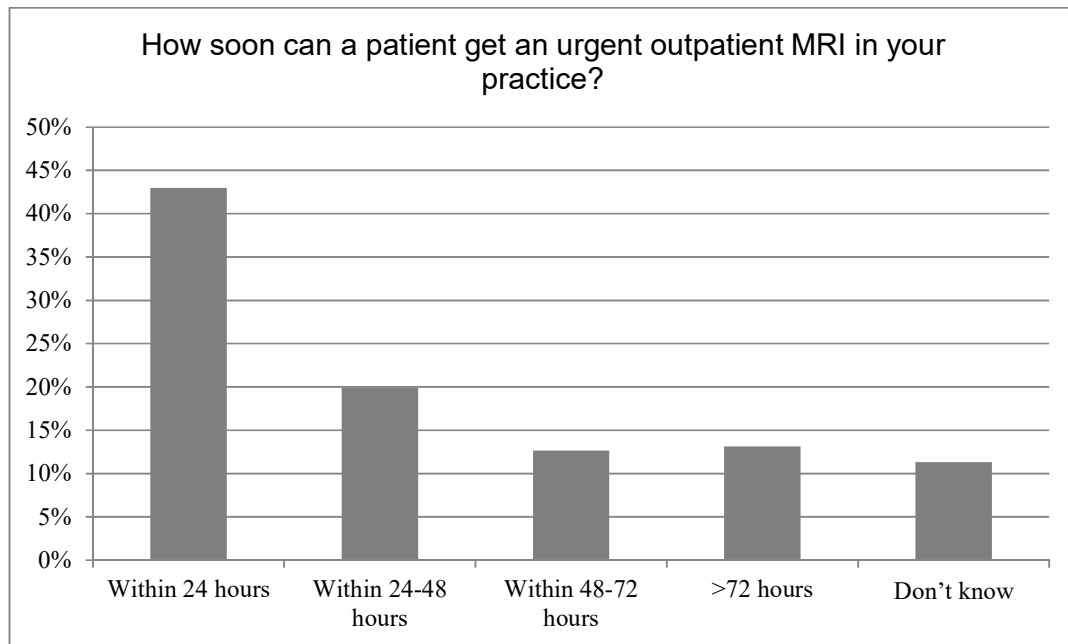
Supplemental Figure 3: Number of MRI scanners in the practices' of the respondents.



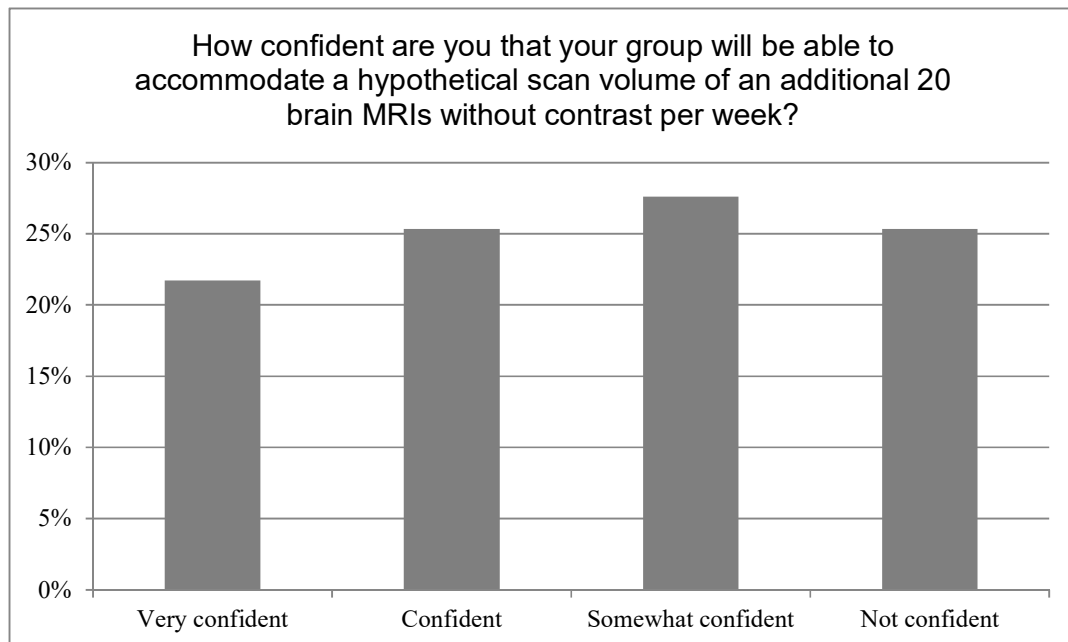
Supplemental Figure 4: Most of the respondents were aware of ARIA, which is likely reflective of bias towards those knowledgeable and interested in ARIA responding to the survey rather than the knowledge base of the overall neuroradiology community.



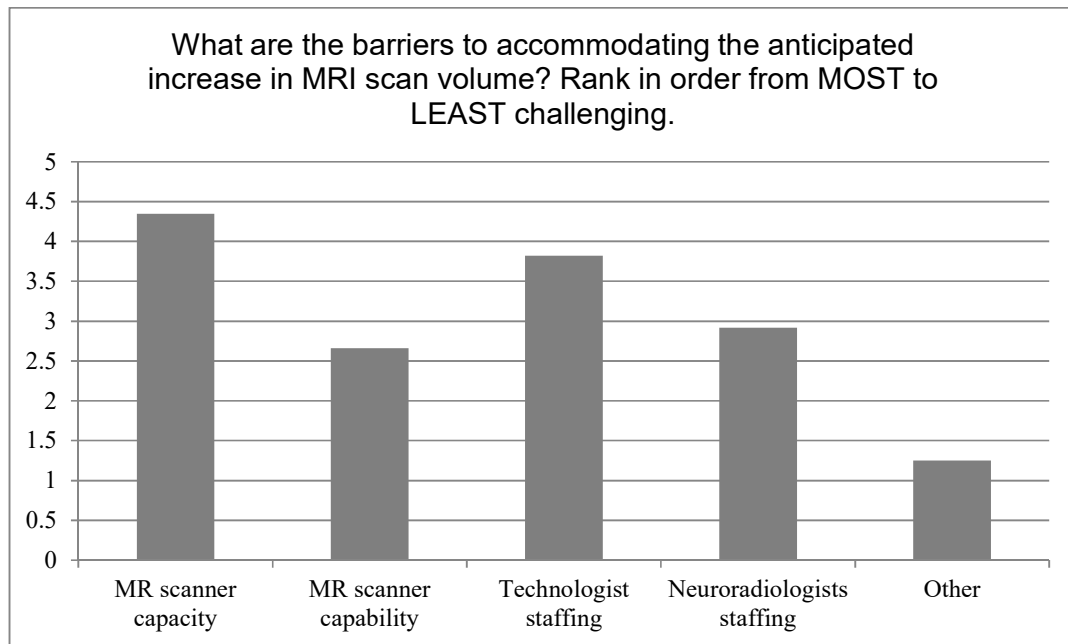
Supplemental Figure 5: Confidence in respondents ability to detect ARIA, skewed toward very confident also likely related to response rate bias.



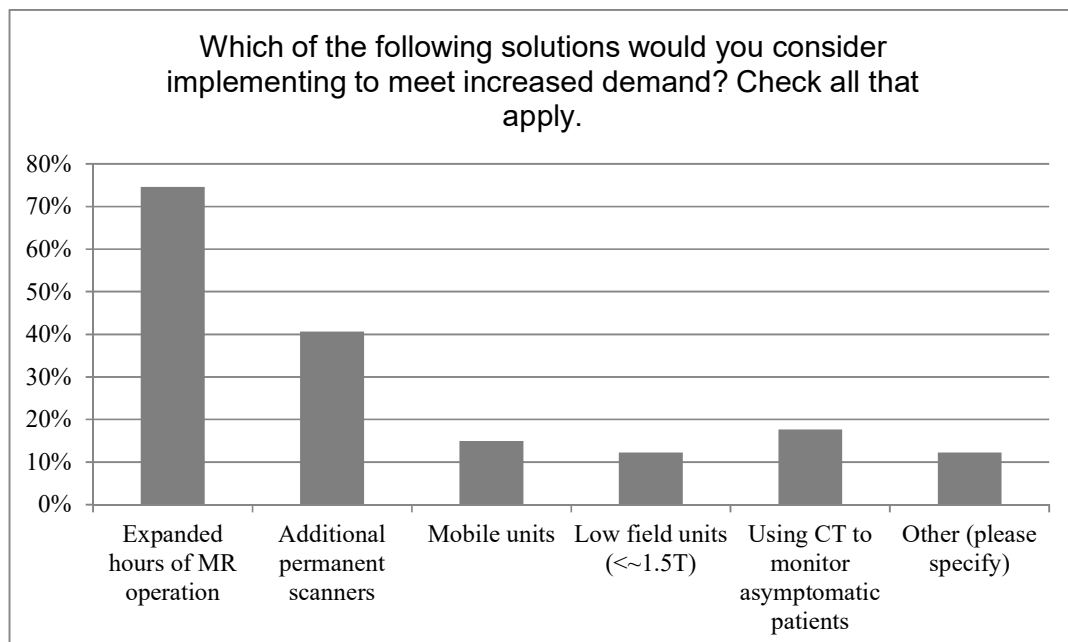
Supplemental Figure 6: Time within respondents estimate an urgent MRI can be obtained in their practice.



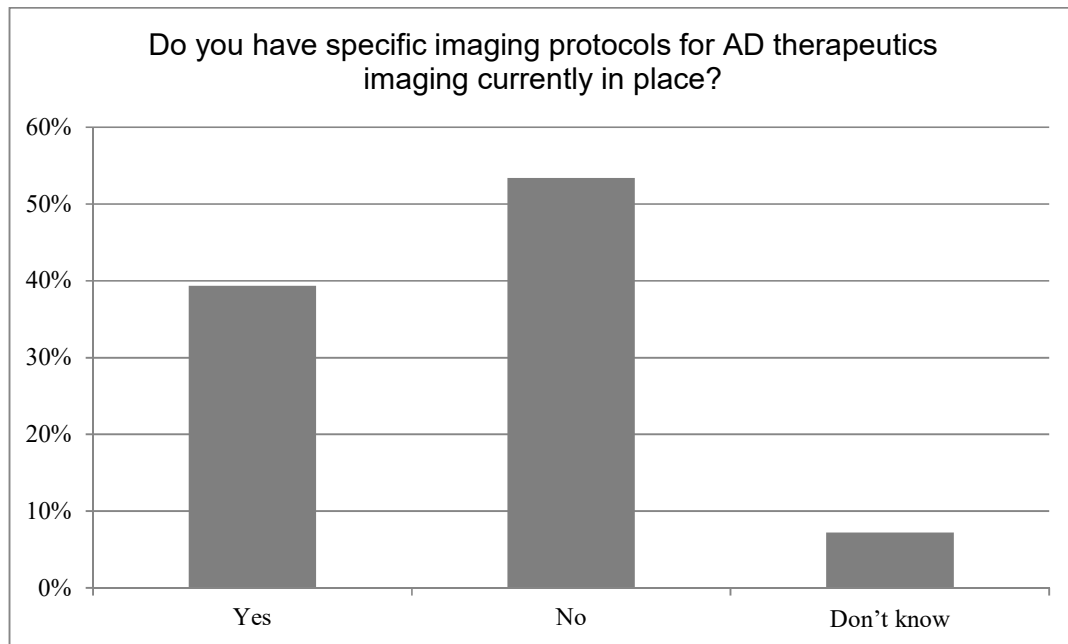
Supplemental Figure 7: Confidence of the respondents in the ability of their practice to accommodate increase MRI scan volumes.



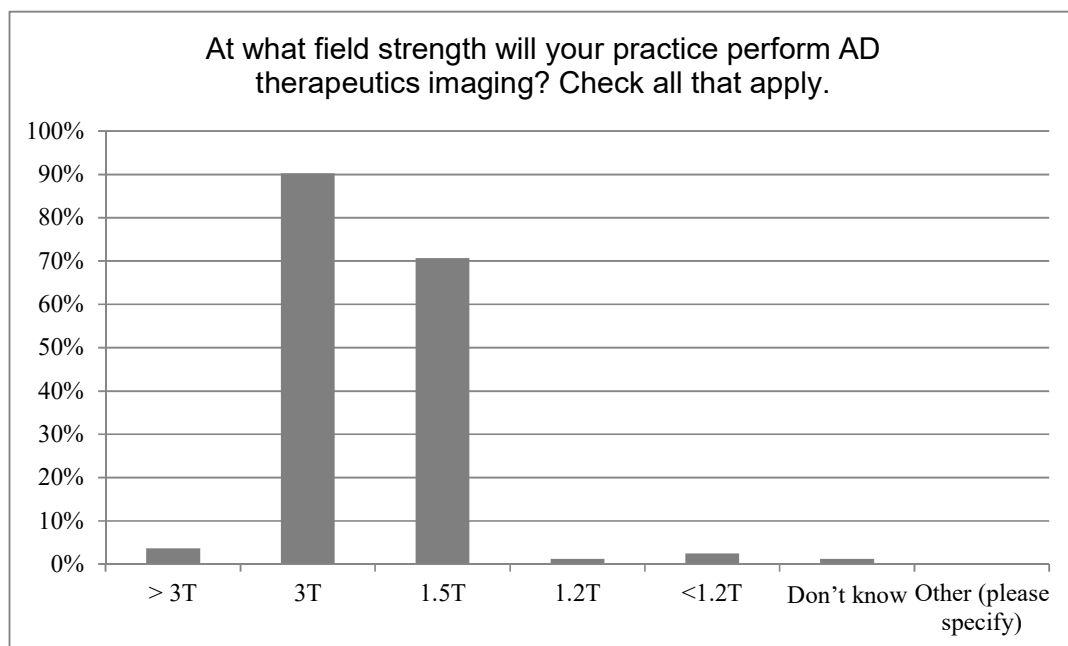
Supplemental Figure 8: Barriers to accommodating increase MRI scan volumes. A higher number indicates a perceived higher barriers with the greatest barriers being MR scanner capacity and technologist staffing.



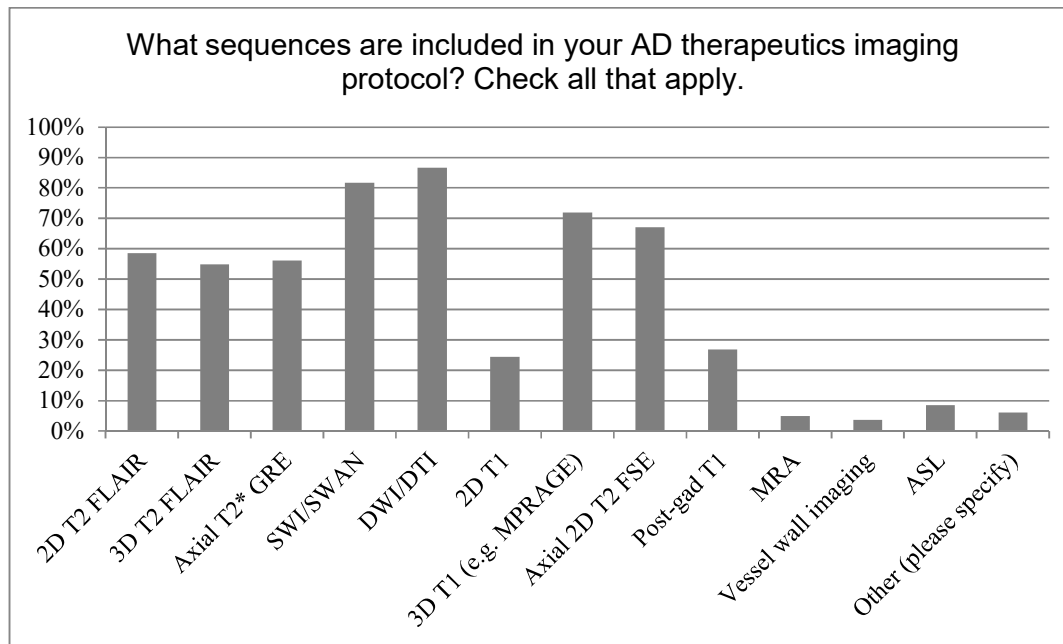
Supplemental Figure 9: Solutions to meet an increase in MRI scan volumes.



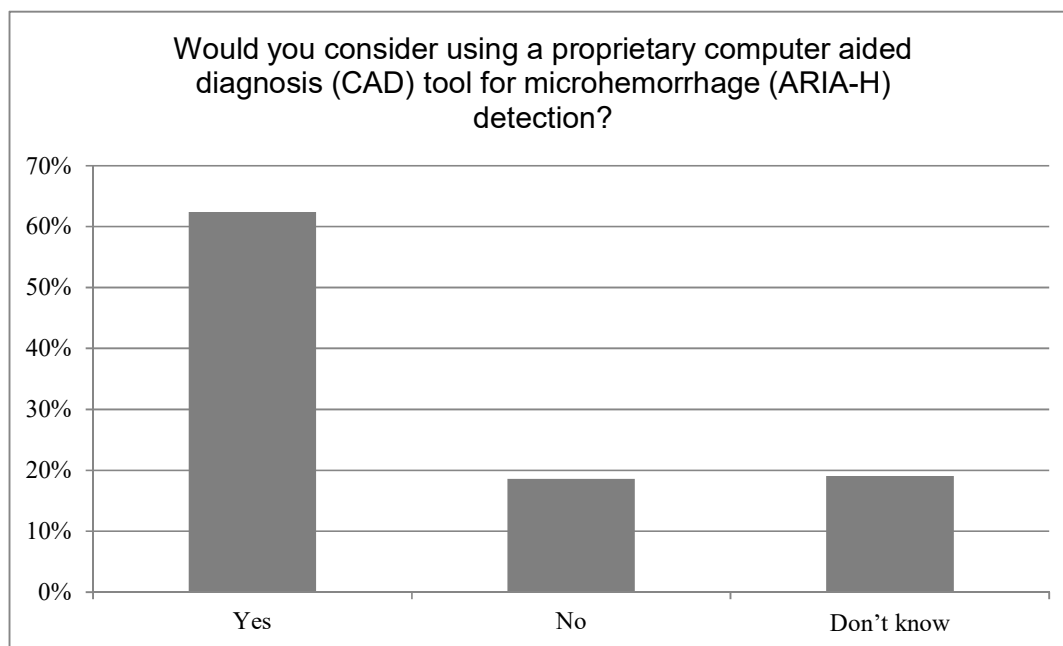
Supplemental Figure 10: AD therapeutics imaging protocols established in the respondents practice.



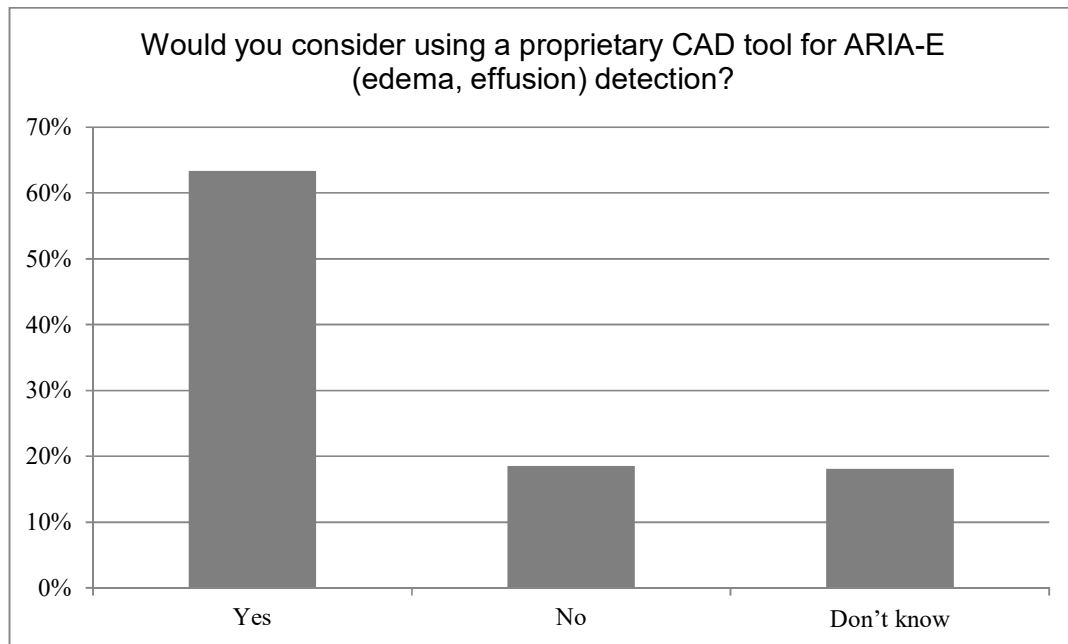
Supplemental Figure 11: Field strength at which AD therapeutics imaging will be performed, for those with protocols established.



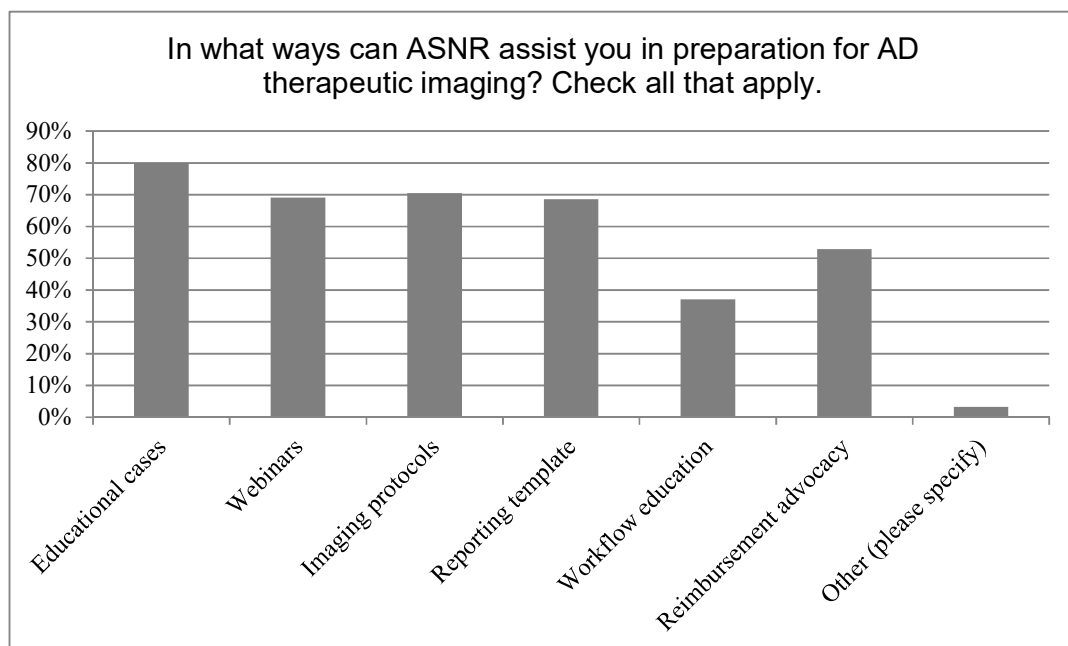
Supplemental Figure 12: Imaging sequences included in the AD therapeutics protocols, for those with protocols established.



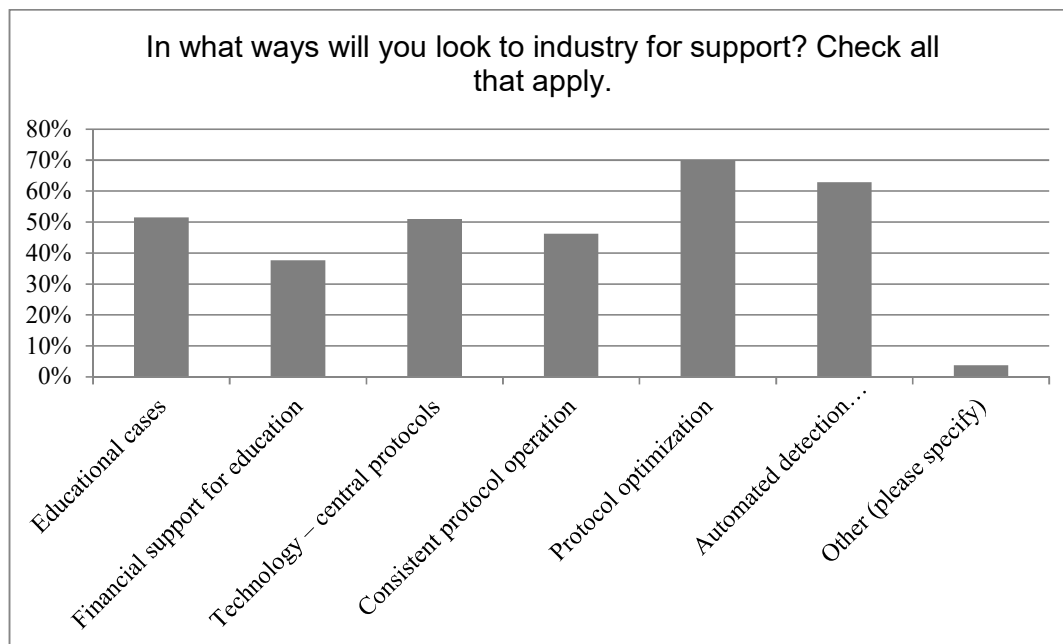
Supplemental Figure 13: Respondent interest in CAD tool for microhemorrhage detection.



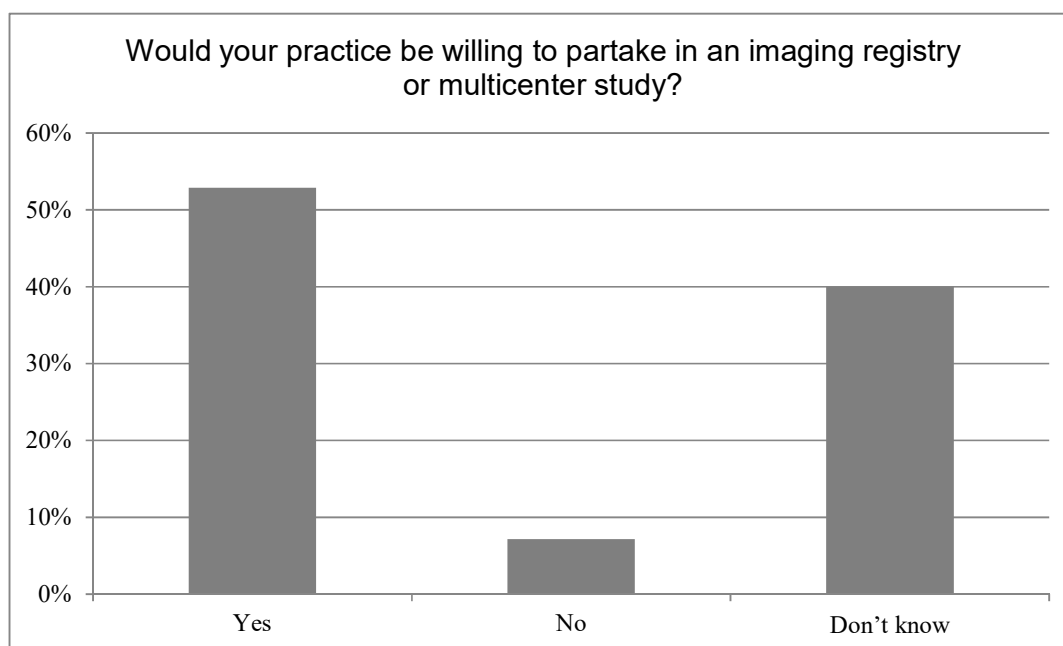
Supplemental Figure 14: Respondent interest in in CAD tool for ARIA-E detection.



Supplemental Figure 15: Ways that ASNR can assist in preparations for AD therapeutics imaging.



Supplemental Figure 16: Ways that industry can support AD therapeutics imaging in clinical practice.



Supplemental Figure 17: Willingness of the practice to partake in an imaging registry as gauged by the respondents.