

Quantification of T2-FLAIR mismatch in non-enhancing diffuse gliomas using digital subtraction

(Supplement submitted to American Journal of Neuroradiology)

Nicholas S. Cho¹⁻⁴, Francesco Sanvito^{1,2}, Viên Lam Le¹⁻³, Sonoko Oshima^{1,2}, Ashley Teraishi^{1,2},

Jingwen Yao^{1,2}, Donatello Telesca⁵, Catalina Raymond^{1,2}, Whitney B. Pope², Phioanh L.

Nghiemphu^{6,7}, Albert Lai^{6,7}, Timothy F. Cloughesy^{6,7}, Noriko Salamon²,

Benjamin M. Ellingson^{1-3, 8, 9, ¥}

¹ UCLA Brain Tumor Imaging Laboratory (BTIL), Center for Computer Vision and Imaging Biomarkers, University of California, Los Angeles, Los Angeles, CA, USA

² Department of Radiological Sciences, David Geffen School of Medicine, University of California, Los Angeles, Los Angeles, CA, USA

³ Department of Bioengineering, Henry Samueli School of Engineering and Applied Science, University of California, Los Angeles, Los Angeles, CA, USA

⁴ Medical Scientist Training Program, David Geffen School of Medicine, University of California, Los Angeles, Los Angeles, CA, USA

⁵ Department of Biostatistics, Fielding School of Public Health, University of California Los Angeles, Los Angeles, CA, USA

⁶ UCLA Neuro-Oncology Program, David Geffen School of Medicine, University of California, Los Angeles, Los Angeles, CA, USA

⁷ Department of Neurology, David Geffen School of Medicine, University of California, Los Angeles, Los Angeles, CA, USA

⁸ Department of Neurosurgery, David Geffen School of Medicine, University of California, Los Angeles, Los Angeles, CA, USA

⁹ Department of Psychiatry and Biobehavioral Sciences, David Geffen School of Medicine, University of California, Los Angeles, Los Angeles, CA, USA

[‡] Corresponding author

Benjamin M. Ellingson, Ph.D.

Director, UCLA Brain Tumor Imaging Laboratory (BTIL)

Professor of Radiology, Psychiatry, and Neurosurgery

Departments of Radiological Sciences, Psychiatry, and Neurosurgery

David Geffen School of Medicine

University of California, Los Angeles

924 Westwood Blvd., Suite 615

Los Angeles, CA 90024 (bellingson@mednet.ucla.edu)

Phone: 310-481-7572

Fax: 310-794-2796

Supplementary Tables

Supplementary Table 1. Contingency tables of percentage T2-FLAIR mismatch volume and tumor grade in IDH-mutant astrocytomas.

| ≥25% T2FM-Volume IDHm-A Distribution Across Cohorts | | | |
|---|-------------------------|-------------------------|------------------------|
| | <25% T2FM-Volume IDHm-A | ≥25% T2FM-Volume IDHm-A | Fisher’s Exact p-value |
| TCIA | 31 | 15 | P=0.03 |
| INST | 7 | 12 | |
| Tumor Grade Distribution Across Cohorts | | | |
| | IDHm-A Grade 2 | IDHm-A Grade 3-4 | Fisher’s Exact p-value |
| TCIA | 33 | 13 | P=0.38 |
| INST | 11 | 8 | |
| TCIA: Tumor Grade Distribution Based on 25% T2FM-Volume | | | |
| | IDHm-A Grade 2 | IDHm-A Grade 3-4 | Fisher’s Exact p-value |
| <25% T2FM-Volume | 24 | 7 | P=0.30 |
| ≥25% T2FM-Volume | 9 | 6 | |
| INST: Tumor Grade Distribution Based on 25% T2FM-Volume | | | |
| | IDHm-A Grade 2 | IDHm-A Grade 3-4 | Fisher’s Exact p-value |
| <25% T2FM-Volume | 6 | 1 | P=0.15 |

| | | | |
|------------------|---|---|--|
| ≥25% T2FM-Volume | 5 | 7 | |
|------------------|---|---|--|

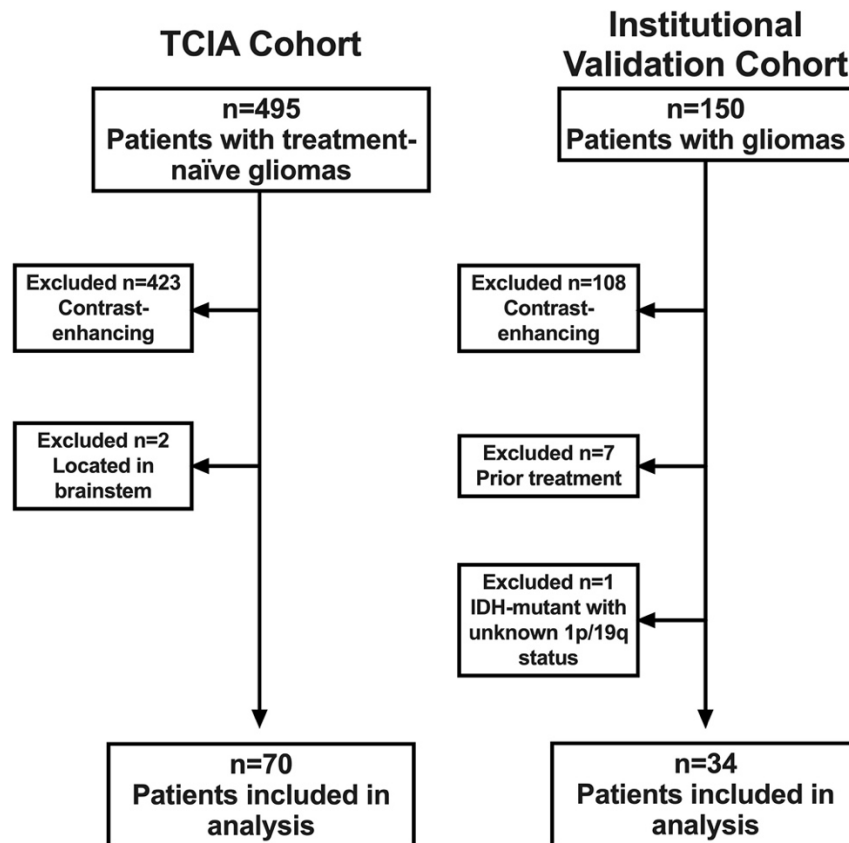
IDHm-A = isocitrate dehydrogenase mutant astrocytoma; TCIA = The Cancer Imaging Archive cohort; INST = institutional cohort

Supplementary Table 2. Pooled diagnostic performance of quantitative percentage T2-FLAIR mismatch volume and reader assessment of T2-FLAIR mismatch sign for classifying IDH-mutant astrocytoma.

| Classification Definition | Sensitivity | Specificity |
|--|-------------|-------------|
| ≥42% T2FM-volume | 23.1% | 100% |
| ≥25% T2FM-volume | 41.5% | 95% |
| ≥15% T2FM-volume | 50.8% | 90% |
| Patel <i>et al.</i> ¹ (Reader min–max) | 30.8–38.5% | 92.5–97.5% |
| Lasocki <i>et al.</i> ² (Reader min–max) | 41.5–55.4% | 85.0–92.5% |

T2FM = T2-FLAIR mismatch

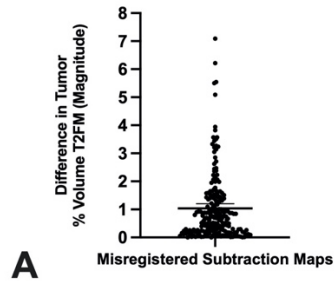
Supplementary Figures



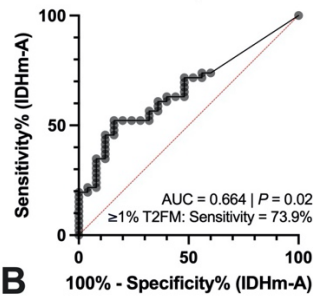
Supplementary Figure 1. Patient selection flowchart. TCIA = The Cancer Imaging Archive;

IDH = isocitrate dehydrogenase

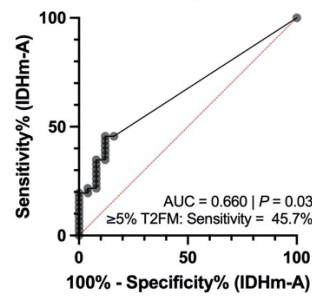
**Impact of Image Registration
on % T2FM-Volume:
2 mm Shift or 2 deg Rotation**



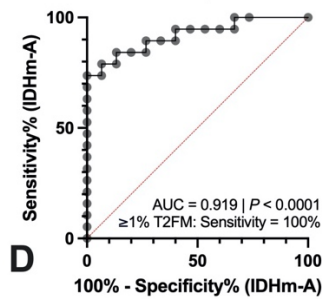
**[TCIA] ROC of % T2FM-Volume for
IDHm-A Classification (<1% Rounded to 0%)**



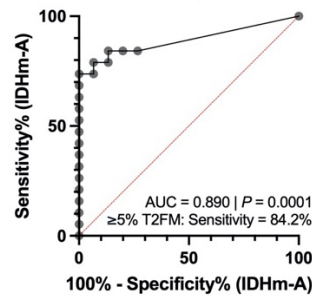
**[TCIA] ROC of % T2FM-Volume for
IDHm-A Classification (<5% Rounded to 0%)**



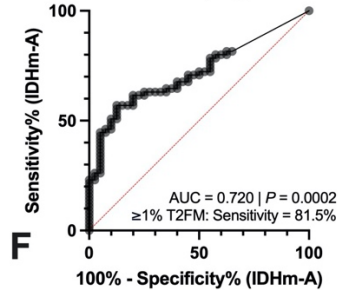
**[INST] ROC of % T2FM-Volume for
IDHm-A Classification (<1% Rounded to 0%)**



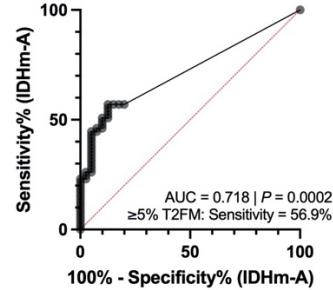
**[INST] ROC of % T2FM-Volume for
IDHm-A Classification (<5% Rounded to 0%)**



**[Pooled] ROC of % T2FM for
IDHm-A Classification (<1% Rounded to 0%)**

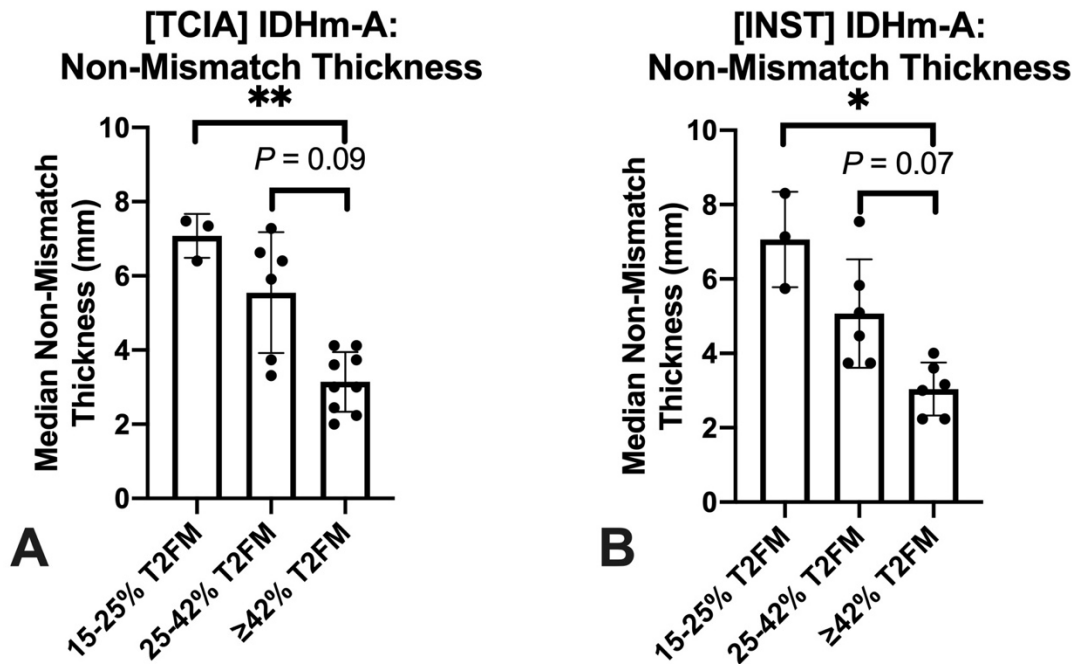


**[Pooled] ROC of % T2FM for
IDHm-A Classification (<5% Rounded to 0%)**



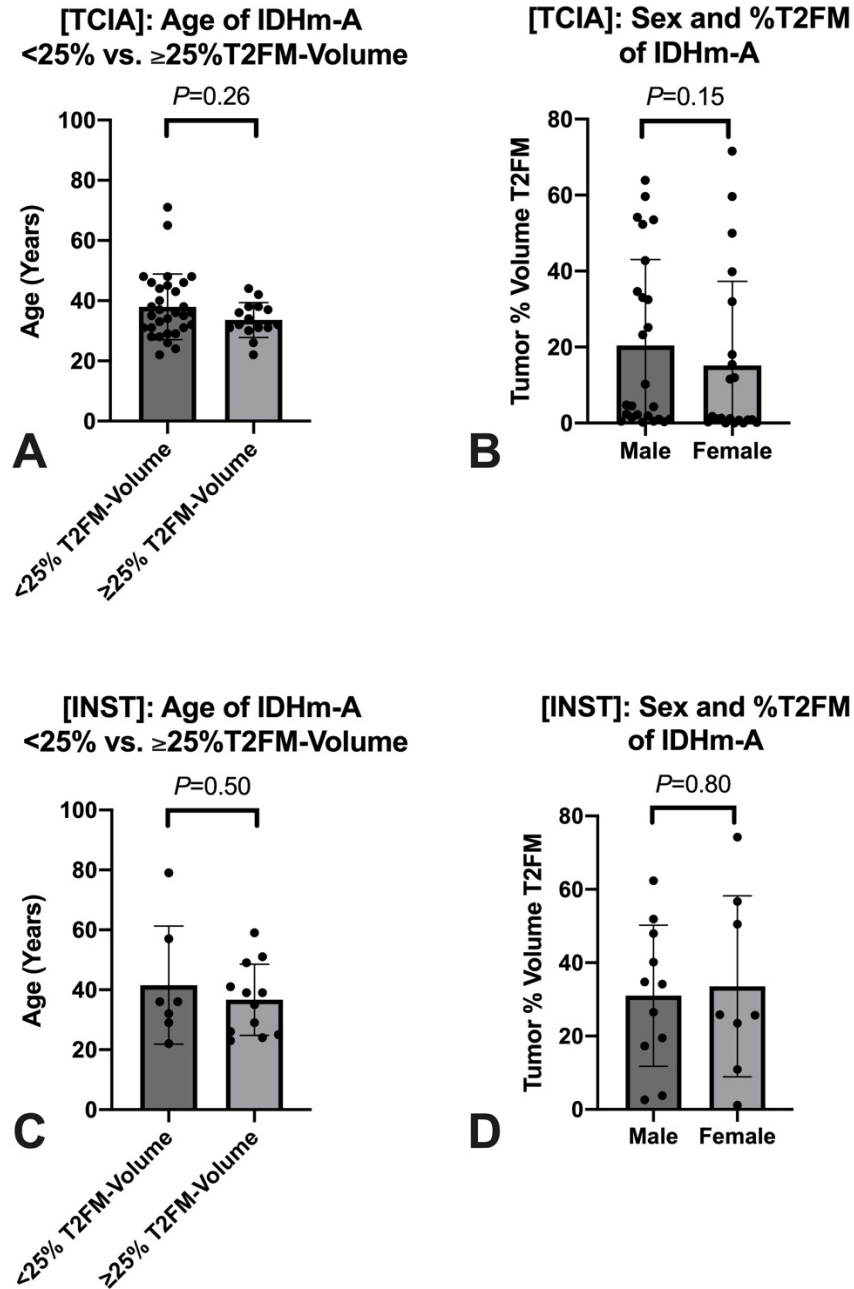
Supplementary Figure 2. Assessment of finite image misregistration and empiric “noise floors” of % T2-FLAIR mismatch volume on T2-FLAIR subtraction maps. (A) Finite 2 mm posterior translation or 2 degree counter-clockwise rotation misregistration resulted in an average magnitude difference of 1.04% T2-FLAIR mismatch (T2FM)-volume. In subsequent ROC curve analyses, **(B)** AUC in the TCIA cohort was 0.664 and **(C)** 0.660 for classifying IDH mutant astrocytoma when considering a $<1\% = 0\%$ T2FM-volume and a $<5\% = 0\%$ T2FM-volume noise floor, respectively. In the institutional cohort, **(D)** AUC was 0.919 and **(E)** 0.890 for classifying IDH mutant astrocytoma when considering a $<1\% = 0\%$ T2FM-volume and a $<5\% = 0\%$ T2FM-volume noise floor, respectively. In the pooled cohort, **(F)** AUC was 0.720 and **(G)** 0.718 for classifying IDH mutant astrocytoma when considering a $<1\% = 0\%$ T2FM-volume and a $<5\% = 0\%$ T2FM-volume noise floor, respectively.

TCIA = The Cancer Imaging Archive; INST = Institutional; ROC = Receiver-operating characteristic; AUC = Area under curve; T2FM = T2-FLAIR mismatch



Supplementary Figure 3. Differences in T2-FLAIR non-mismatch thickness in IDH-mutant astrocytomas grouped by % T2-FLAIR mismatch volume. T2-FLAIR non-mismatch (T2FNM)-subregion thickness was significantly different across 15–25% T2-FLAIR mismatch (T2FM)-volume, 25–42% T2FM-volume, and ≥42% T2FM-volume IDH mutant astrocytoma (IDHm-A) in the TCIA (**A**: $P=0.001$) and institutional cohorts (**B**: $P=0.001$). Post-hoc tests showed that ≥42% T2FM-volume IDHm-A had significantly thinner T2FNM subregions compared to 15–25% T2FM-volume IDHm-A in the TCIA (**A**: $P=0.007$) and institutional cohorts (**B**: $P=0.01$).

IDHm-A = Isocitrate dehydrogenase mutant astrocytoma; TCIA = The Cancer Imaging Archive; INST = Institutional; T2FM = T2-FLAIR Mismatch; * indicates $P < 0.05$, ** indicates $P < 0.01$



Supplementary Figure 4. Assessment of patient age and sex with percentage T2-FLAIR

mismatch volume. There were no significant relationships in age (A/C) or sex (B/D) with %T2FM-volume in either cohort.

IDHm-A = Isocitrate dehydrogenase mutant astrocytoma; TCIA = The Cancer Imaging Archive;

INST = Institutional; T2FM = T2-FLAIR Mismatch;

References

1. Patel SH, Poisson LM, Brat DJ, et al. T2–FLAIR Mismatch, an Imaging Biomarker for IDH and 1p/19q Status in Lower-grade Gliomas: A TCGA/TCIA Project. *Clinical Cancer Research* 2017;23:6078-6085
2. Lasocki A, Buckland ME, Drummond KJ, et al. Conventional MRI features can predict the molecular subtype of adult grade 2–3 intracranial diffuse gliomas. *Neuroradiology* 2022;64:2295-2305