



Providing Choice & Value

Generic CT and MRI Contrast Agents



**FRESENIUS
KABI**

CONTACT REP

AJNR

High-resolution MR Angiographic Cerebrovascular Findings in a Tri-Ethnic Population

Rafael Rehwald, Carole H. Sudre, Lorna Smith, Magdalena Sokolska, Therese Tillin, David Atkinson, Nishi Chaturvedi, Alun D. Hughes and Hans R. Jäger

This information is current as
of July 31, 2025.

AJNR Am J Neuroradiol published online 12 July 2024
<http://www.ajnr.org/content/early/2024/07/03/ajnr.A8402>

High-resolution MR Angiographic Cerebrovascular Findings in a Tri-Ethnic Population

Rafael Rehwald, Carole H. Sudre, Lorna Smith, Magdalena Sokolska, Therese Tillin, David Atkinson, Nishi Chaturvedi, Alun D. Hughes, and Hans R. Jäger

ABSTRACT

BACKGROUND AND PURPOSE: Incidental findings on brain MR and variation of the circle of Willis (CoW) are relatively common among the general population. Ethnic differences have been described before, but few studies have explored the prevalence of incidental intracranial cerebrovascular findings and CoW variants in the setting of a single multi-ethnic cohort. The purpose of this investigation is to describe both incidental cerebrovascular findings and the morphology of the CoW on high-resolution 3T time-of-flight MR angiography (ToF MRA) in a UK tri-ethnic population-based cohort and to present updated prevalence estimates and morphologic reference values.

MATERIALS AND METHODS: We studied participants from the UK Southall and Brent Revisited (SABRE) study who underwent 3T brain MRI between 2014-2018. ToF MRA images were assessed for the presence of incidental cerebrovascular imaging findings and used to determine CoW anatomy.

RESULTS: 750 participants (mean age: 71.28 ± 6.46 years, range [46-90], 337 female), 322 White Europeans, 253 South Asians, and 175 African Caribbeans, were included. Incidental cerebrovascular findings were observed in 84 subjects (11.2%, 95% CI [9.0-13.7]; 38 women, 45.24%, 95% CI [34.34-56.48]), cerebral aneurysms being the most frequent, followed by intracranial arterial stenoses (ICAS) with highest prevalence among South Asians compared to White European (OR: 2.72, 95% CI [1.22-6.08], $p = .015$) and African Caribbean subjects (OR: 2.79, 95% CI [1.00-7.82], $p = .051$). Other findings included arteriovenous malformations and infundibula. The CoW was found to be more often complete in women than in men (25.22% compared to 18.41%, $p = .024$), and in African Caribbean (34.86%), compared to White European (19.19%), and South Asian (14.23%) subjects ($p < 0.001$ each).

CONCLUSIONS: ICAS were independently associated with ethnicity after adjusting for vascular risk factors, having the highest prevalence among South Asians. The prevalence of aneurysms was higher than in previous population-based studies. We observed anatomical differences in the CoW configuration between women, men, and ethnicities.

ABBREVIATIONS: BP = Blood pressure; ICAS = Intracranial arterial stenoses; CoW = Circle of Willis; CVM = Cerebral vascular malformations; OR = Odds ratio; ToF MRA = Time-of-flight MR angiography.

Received month day, year; accepted after revision month day, year.

From the Department of Brain Repair and Rehabilitation, UCL Queen Square Institute of Neurology, London, United Kingdom (R.R., M.S., H.R.J.), MRC Unit for Lifelong Health and Ageing at UCL, Institute of Cardiovascular Science, University College London, London, United Kingdom (C.H.S., T.T., N.C., A.D.H.), Dementia Research Centre, UCL Queen Square Institute of Neurology, University College London, London, United Kingdom (C.H.S.), School of Biomedical Engineering, King's College, London, United Kingdom (C.H.S.), Centre for Medical Imaging, Division of Medicine, University College London, London, United Kingdom (L.S., D.A.), Department of Medical Physics and Biomedical Engineering, University College London Hospitals National Health Service (NHS) Foundation Trust, London, United Kingdom (M.S.), Lysholm Department of Neuroradiology, National Hospital for Neurology and Neurosurgery, Queen Square, Holborn, London, United Kingdom (H.R.J.).

The authors declare no conflicts of interest related to the content of this article.

Please address correspondence to Rafael Rehwald, MD MRes PhD, Department of Brain Repair and Rehabilitation, UCL Queen Square Institute of Neurology, Queen Square, London WC1N 3BG, United Kingdom; r.rehwald@ucl.ac.uk

SUMMARY SECTION

PREVIOUS LITERATURE: Detection of incidental findings on brain MRI and MRA examinations is not uncommon and ethnic differences in cerebrovascular diseases have been described previously. However large population-based studies exploring the prevalence of incidental cerebrovascular findings in multi-ethnic cohorts remain scarce. Previous investigations have also suggested some differences in the circle of Willis anatomy between sex and ethnicity, with partially contradictory and ultimately inconclusive findings. The aim of this investigation is a comprehensive assessment of the prevalence of incidental cerebrovascular findings and morphological variants of the circle of Willis in a healthy elderly tri-ethnic population using 3T ToF MRA.

KEY FINDINGS: South Asian ethnicity has been shown to be an independent predictor for incidental intracranial arterial stenoses on 3T ToF MRA after adjusting for vascular risk factors. Differences in circle of Willis anatomy were observed between sex and ethnic groups but showed no significant associations with the incidence or spatial distribution of cerebrovascular findings.

KNOWLEDGE ADVANCEMENT: This cohort study provides an update on the prevalence of incidental cerebrovascular findings and variants of the circle of Willis on 3T ToF MRA in three different ethnic groups. The results contribute to our understanding of both sex and ethnic differences in cerebrovascular diseases, and have the potential to improve risk factor profiling, screening, and therapeutic pathways.

INTRODUCTION

Advances in MR- and CT angiography allow non-invasive acquisition of high-resolution images of the intracranial vessels [1]. More widespread use of these techniques resulted in increasing detection of incidental vascular abnormalities such as intracranial arterial stenoses (ICAS), aneurysms or cerebral vascular malformations (CVM). Furthermore, these techniques allow non-invasive visualisation of the circle of Willis (CoW) and its anatomical variants, which have a bearing on the outcome in steno-occlusive disease of the neck vessels and stroke. The prevalence of incidental brain imaging findings varies, depending on the population studied, which may differ in age or ethnic origin, as well as on the specific imaging techniques used [2; 3]. While ethnic differences in the pathogenesis of cerebrovascular diseases have been described before, large population-based studies exploring the prevalence of incidental intracranial cerebrovascular findings in the setting of a single multi-ethnic cohort remain scarce.

Anatomical variants of the CoW been linked to the pathogenesis of several cerebrovascular diseases, including the risk of stroke or aneurysm formation [4-7]. For example, hypoplasia or agenesis of the A1 segment of the anterior cerebral artery (ACA) have been implicated as a risk factor for ischaemic stroke and aneurysms of the anterior communicating artery complex [7; 8]. In the presence of a fetal-type posterior communicating artery (PCoA) most of the ipsilateral posterior cerebral artery (PCA) territory is supplied by the anterior circulation, which is important for the correct interpretation of arterial territories involved in the setting of acute stroke, as are other variants of the circle of Willis [9]. Several investigators have postulated that the morphological variations of the CoW differ between ethnic groups, as well as between sexes, which may partially explain the varying prevalence of cerebrovascular disease in different populations. With contradictory reports on the prevalence of CoW variations further clarification of this topic is warranted. Previous efforts have been complicated by methodological challenges, particularly concerning the non-comparability of in vivo and post-mortem studies as well as the heterogeneity of the respective study populations [10-13].

With this large population-based study of an elderly tri-ethnic population using standardized high-resolution 3T time-of-flight MR angiography (ToF MRA) we aim to assess the prevalence of incidental cerebrovascular findings and morphological variants of the CoW, establishing a robust reference in an older multi-ethnic population.

MATERIALS AND METHODS

Study Setting

The sociodemographic and neuroradiological imaging data used were obtained from the Southall and Brent REvisited (SABRE) study, follow-up visit 3, a prospective UK population-based cohort study investigating cardiovascular disease amongst people of self-identified European, South Asian, and African Caribbean origin. The cohort profile update, objectives, and study design have been reported in detail previously [14]. Ethics committee approval was obtained from the London Fulham Research Ethics Committee under reference number 14/LO/108.

Image Acquisition

All MR scans were acquired in a single clinical centre, the University College London Hospitals NHS Foundation Trust, using a 3T whole-body MR system (3T Achieva, Philips Healthcare, Koninklijke Philips N.V., Amsterdam, the Netherlands) fitted with an 8-channel SENSE Head phased array receiver-coil (SENSE Head 8, Philips Healthcare, Koninklijke Philips N.V., Amsterdam, the Netherlands). The MRI scanning protocol was uniform for all participants and consisted of ten different high-resolution sequences (T2 FFE; T1 3D TFE; FLAIR 3D IR TSE; DTI EPI; ToF MRA; pCASL EPI; T2 3D TSE, B0 3D FFE) with an overall scanning time of 33 min and 30 s.

For the ToF MRA, a 3D gradient echo sequence was used to acquire 140 axial slices over a 200×200×70 mm FOV (RL×AP×FH). The scan acquired data in 4 chunks and to reduce venetian blind artifacts, a linearly varying flip angle over each chunk ("TONE") was used with a starting flip angle of 17 degrees. A saturation slab was positioned superiorly to suppress venous blood. The acquired voxel sizes were 0.70×0.40×0.50 mm, reconstructed to a 560×560 in-plane matrix giving reconstructed voxel sizes of 0.36×0.36×0.50 mm. The TR/TE were 25/3.5ms, nominal flip angle 20 degrees, RF spoiling was used for T1 weighted contrast, and the sequence duration was 6 min 0 s.

Image Analysis

The ToF MRA sequences were assessed independently by a neuroradiologist and a radiologist (H.R.J. with 28 years and R.R. with 5 years of experience), with differences resolved by consensus. H.R.J. assessed the MRI studies for both vascular and non-vascular incidental findings using a structured report. Actionable incidental findings were defined in the study protocol and were communicated to relevant clinical specialists or the general practitioners. R.R. subsequently performed an independent reading for incidental cerebrovascular imaging findings and the characterisation of the CoW.

Significant ICAS was defined as a 50–99% focal narrowing of the major intracranial arteries as in previous studies [15]. Saccular aneurysms were distinguished from infundibula by the clear visualisation of a vessel originating from the apex of an outpouching.

The CoW was assessed using the ToF MRA images, utilising the source images as well as the respective 3D MIP reconstructions according to the reference classification established by Krabbe-Hartkamp et al [4], while rare morphological variants were categorised based on the work of Dimmick and Faulder [16].

Data Analysis

All findings are presented as counts and percentages where appropriate. Confidence intervals, with reporting restricted to the main outcomes of the study, have been estimated at the 95% level (bootstrap 95% CI, 1000 iterations). The prevalence of the findings was compared across women and men as well as ethnicity using Pearson's chi-squared test (χ^2), odds ratios (OR) were obtained from logistic

regression models, adjusted for age and sex as well as the vascular risk factors diabetes, hypertension, and LDL-hyperlipidemia where appropriate (Online Supplemental Data and supplementary table 2). Kappa values were calculated to assess interrater reliability. Statistical software (Stata 15.1; Stata Corp., College Station, Texas, USA, and R; version 4.1.0, R Foundation, Vienna, Austria) was used to perform all analyses.

RESULTS
Population Demographics

Basic demographic and lifestyle characteristics are shown in Online Supplemental Data. Inclusion and exclusion criteria are detailed in figure 1.

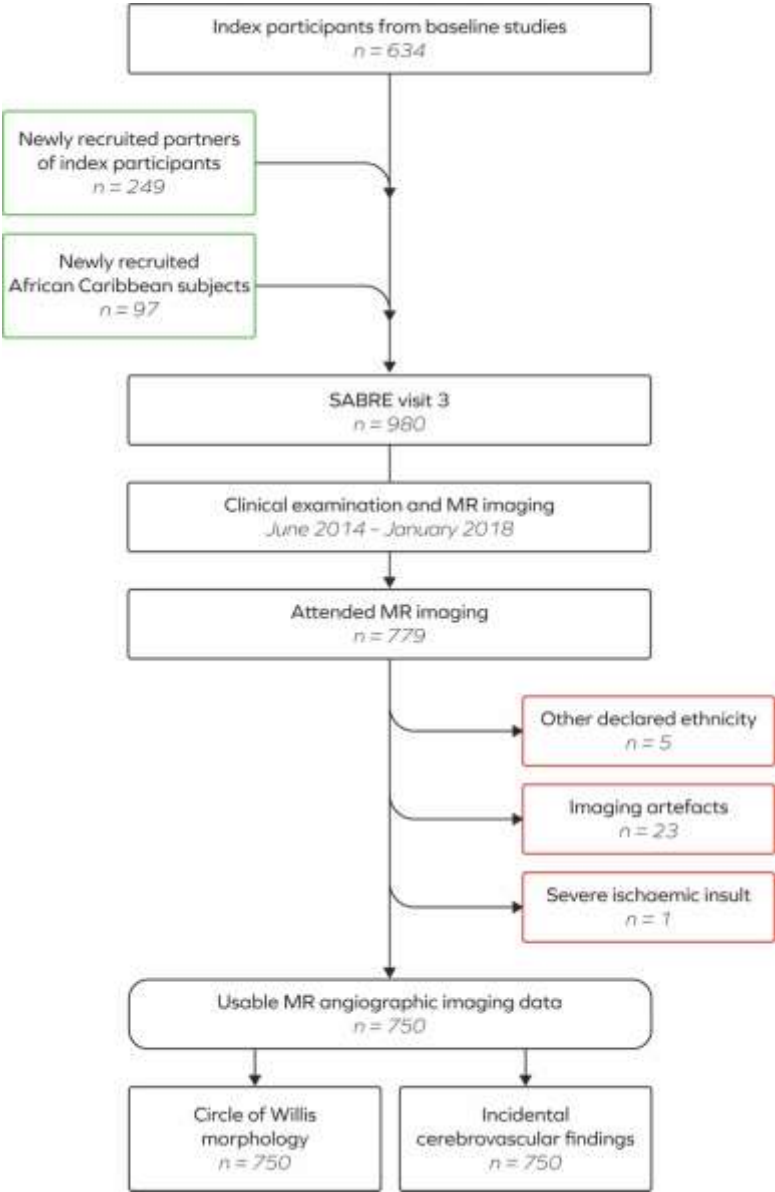


FIG 1. Study inclusion and exclusion flowchart. SABRE = Southall and Brent REvisited study.

Incidental Cerebrovascular Findings

Interobserver Agreement

Interobserver agreement for incidental cerebrovascular findings was overall very high (kappa 0.987). Over a total of 84/750 subjects with incidental findings, there were 3 cases of disagreement between the raters: one small saccular aneurysm was missed, the degree of a <50% stenosis of the terminal ICA was overestimated, and one infundibulum was misinterpreted as an aneurysm. These discrepancies were resolved by consensus.

Prevalence and Spatial Distribution

Of the 750 study volunteers, incidental cerebrovascular findings were found in a total of 84 subjects (11.20%, 95% CI [9.03–13.68]), of whom 38 were women (45.24%, 95% CI [34.34–56.48]) and 47 men (55.95%, 95% CI [44.69–67.78]). Incidental cerebrovascular findings were observed in 38/322 White Europeans (11.80%, 95% CI [8.49–15.84]), 30/253 South Asians (11.86%, 95% CI [8.15–16.49]), and among 16/175 study participants of African Caribbean descent (9.14%, 95% CI [5.32–14.42]). In 11 subjects (1.47%; 95% CI [0.8–2.6]), a second incidental finding of the same type, respectively, was observed, resulting in an overall prevalence of approximately 127 per 1000 cases.

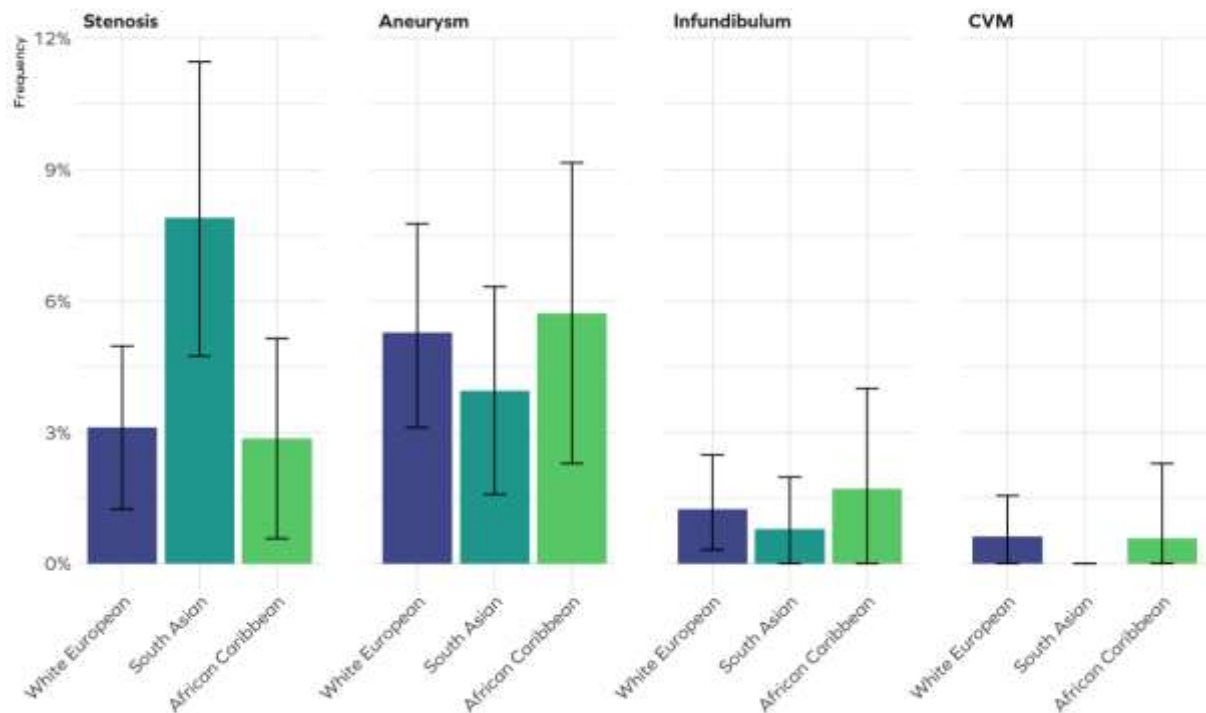


FIG 2. Barplots showing the frequency and 95% CI of the incidental cerebrovascular imaging findings on 3T ToF MR angiography by ethnicity. CVM = Cerebral vascular malformation.

Overall, cerebral aneurysms were the most common incidental finding, with a prevalence of 37/750 subjects (4.93%, 95% CI [3.50–6.73]) and a mean maximum diameter of 2.87 ± 1.36 mm (range 1.00–6.60). Primary cerebral aneurysms were most commonly located in the ICA ($n = 20$, 54.05%, 95% CI [36.92–70.51]), with 9 (45.00%) in the left and 11 in the right ICA (55.00%). The second most common site of incidentally discovered cerebral aneurysms was the middle cerebral artery (MCA), with a total of 7 cases (18.92%, 95% CI [7.96–35.16]), of which 4 were in the left (57.14%) and 3 in the right (42.86%) hemisphere, followed by the anterior cerebral artery (ACA), in which a total of 4 aneurysms (10.81%, 95% CI [3.03–25.42]) were identified (1 left [25.00%], 3 right [75%]). For the basilar artery (BA) and anterior communicating artery (ACoM), 2 aneurysms were identified in each vessel (5.41% [0.66–18.19]), and 1 aneurysm was observed in both the left PCA and left PComA (2.70%, 95% CI [0.01–14.16]). Two subjects had 2 aneurysms, (BA and left MCA; left ICA and right ACA). A detailed summary of the respective aneurysm sites is shown in figure 3. No evidence for relevant differences between White Europeans and South Asians (OR: 0.84, 95% CI [0.38–1.90], $p = .682$) or African Caribbeans (OR: 1.28, 95% CI [0.55–2.96], $p = .569$), women and men (OR: 0.69, 95% CI [0.34–1.40], $p = .309$) has been found.

The second most common incidental finding were ICAS of presumed arteriosclerotic origin, with a prevalence of 35/750 participants (4.67%, 95% CI [3.27–6.43]), and in 9 of these subjects (25.74%, 95% CI [12.49–43.26]) a second stenotic lesion was identified. In 1 subject (0.13%, 95% CI [0.00–0.74]), a White European woman (78 years old), a complete intracranial arterial occlusion was also observed. Within the individual ethnic groups, ICAS was observed among 10/322 subjects of White European origin (3.10%, 95% CI [1.50–5.64], 1 woman), 20/253 South Asian subjects (7.90%, 95% CI [4.90–11.94], 7 women), and 5/180 African Caribbean participants (2.86%, 95% CI [0.93–6.54], 4 women), showing a higher prevalence of ICAS among South Asians compared to White European (OR: 2.72, 95% CI [1.22–6.08], $p = .015$) and African Caribbean subjects (OR: 2.79, 95% CI [1.00–7.82], $p = .051$; Figure 2). There was no evidence for differences between women and men (OR: 1.33, 95% CI [0.61–2.87], $p = .475$).

In the subjects for whom an ICAS was found, the lesions were observed in the ICA in 24/35 cases (68.57%, 95% CI [50.71–83.15]), of which 7 (29.17%) were found in the left and 17 (70.83%) in the right ICA. In the MCA, stenotic lesions were found in a total of 5 subjects (14.29%, 95% CI [4.81–30.26]), with 2 (40.00%) lesions located in the left and 3 (60.00%) in the right cerebral hemisphere. A further 4 stenotic lesions (11.43%, 95% CI [3.20–26.74]) were found in the PCA (1 left [25.00%], 3 right [75.00%]), while 1 stenosis was found in both the BA and the left VA (2.86%, 95% CI [0.07–14.92]), respectively).

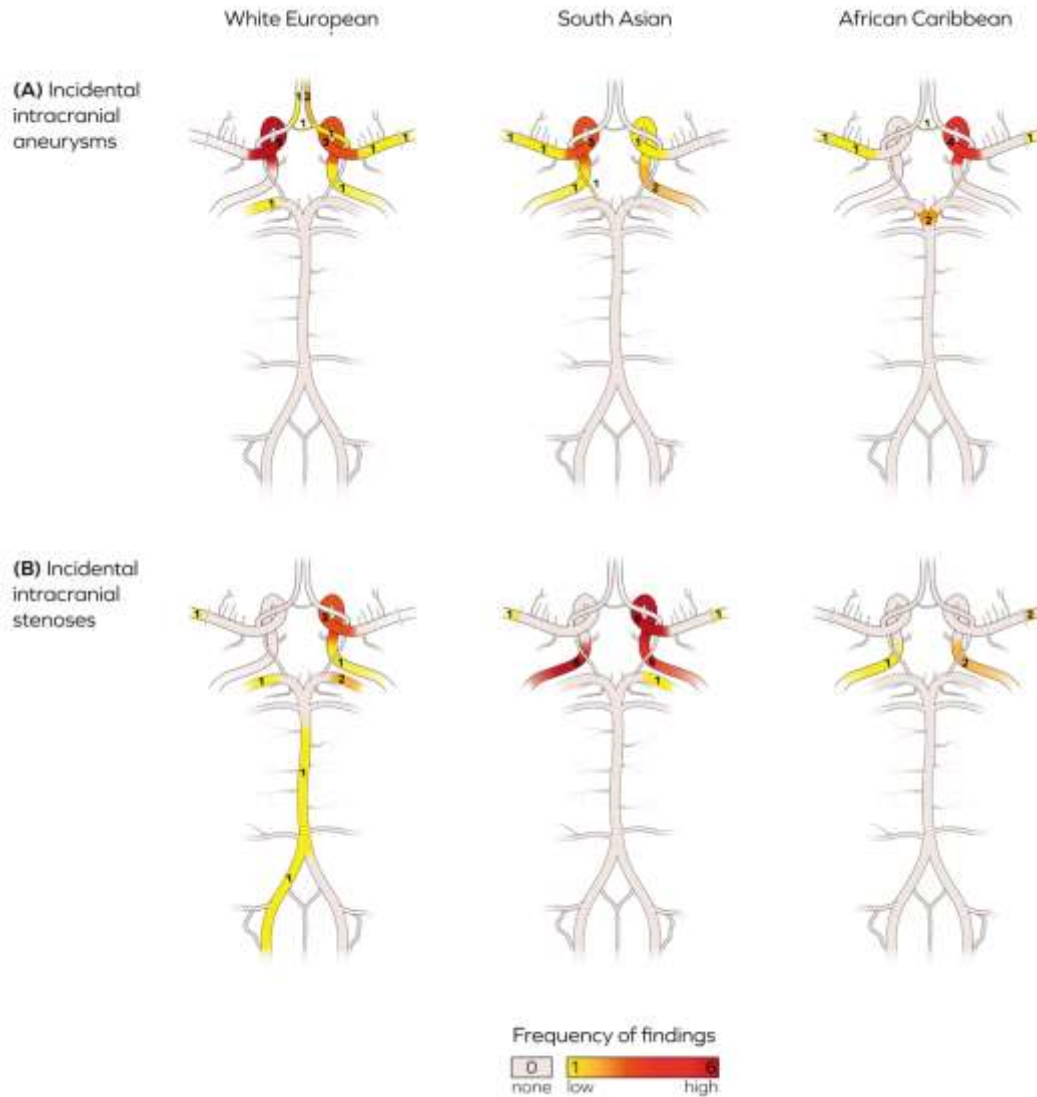


FIG 3. Schematic illustrations of the major intracranial arterial structures detailing the spatial distribution and frequency of identified (A) incidental and (B) stenotic lesions by ethnicity.

Intracranial aneurysms were found in 4/322 White European subjects (1.24%, 95% CI [0.33–3.15]), 2/253 South Asians (0.79%, 95% CI [0.00–2.83]), and 3/175 African Caribbean participants (1.71%, 95% CI [0.35–4.93]) and most frequently observed at the origin of the PComA (3/9 cases (33.33%)). Other locations were the superior cerebellar artery (SCA) and PCA (2 each; 22.11%), the MCA and ophthalmic artery (OA), with 1 aneurysmal outpouching identified in each of these sites (11.11%). No evidence for differences between White European and South Asian (OR: 0.66, 95% CI [0.12–3.72], $p = .636$), African Caribbean (OR: 1.31, 95% CI [0.27–6.43], $p = .740$) or women and men (OR: 0.61, 95% CI [0.15–2.50], $p = .489$) has been found.

CVMs were found in 3/750 subjects (0.40%, 95% CI [0.08–1.16]). Of these, 2 subjects (0.26%, 95% CI [0.03–0.96]), both White European men, aged 68 and 76 years old, had an CVM and 1 (0.13%, 95% CI [0.00–0.74]), an African Caribbean woman (72 years old), had a dural fistula. The CVMs identified were located in the superior vermis and the left cerebellar hemisphere respectively, and the dural fistula was located in the right transverse sinus.

Circle of Willis Anatomy

The observed CoW variants and their overall frequency are detailed in figure 4 and supplementary table 1.

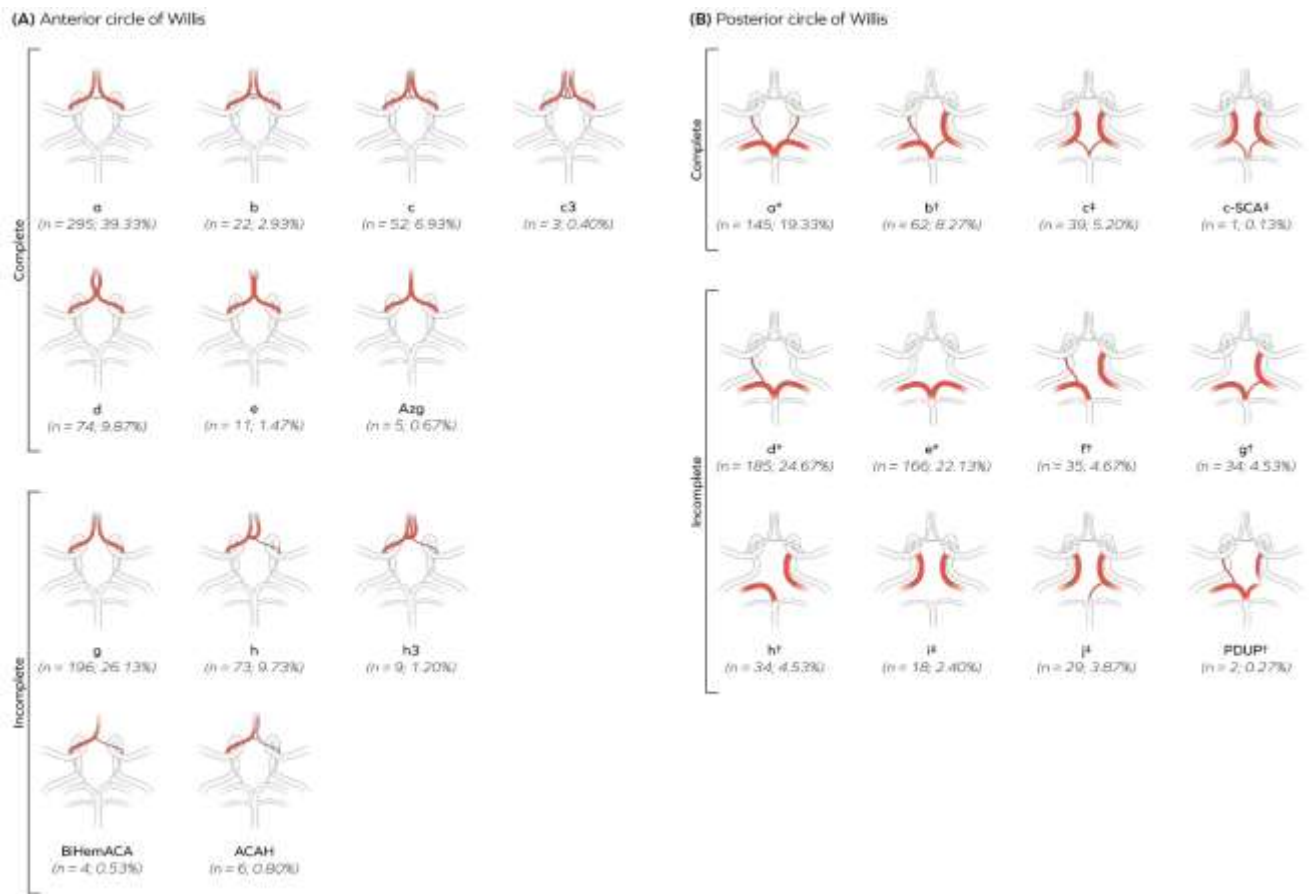


FIG 4. Illustration of the observed anatomical variants of the (A) anterior and (B) posterior circle of Willis with numbers and overall frequency. Upper panel shows functionally complete, lower panel functionally incomplete variants, respectively. c-SCA = PCA P1 segment arising from the ipsilateral SCA; PDUP = Ipsilateral duplication of the PCA. Azg = Azygos ACA; BiHemACA = Bihemispheric ACA; ACAH = Unilateral ACA hypoplasia; c3 = Duplication of the median artery of the corpus callosum; h3 = Unilateral ACA trifurcation. * Normal PCA anatomy; † Unilateral fetal-type PCA; ‡ Bilateral fetal-type PCA.

The CoW as a whole was significantly more often found to be complete in women than in men (25.22% compared to 18.41%, $p = .024$), while also most often complete in African Caribbean (34.86%), compared to White European (19.19%), and South Asian (14.23%) subjects ($p < .001$ each; figure 5).

Regarding the completeness of the anterior CoW in the overall cohort, there was no evidence of differences between women and men ($p = .488$) or by ethnicity (figure 4). However, looking at women only, a complete anterior circle was more common among White European compared to South Asian and African Caribbean women (70.09% compared to 52.78% and 57.14%; $p = .008$ and $p = .042$). In the posterior circulation, a complete CoW was found significantly more often in men than in women (71.91% compared to 61.13%, $p = .002$). The frequency of a complete posterior CoW was also significantly higher in the African Caribbean population than in either the White European or South Asian populations ($p < .001$ each; figure 4), while White Europeans were found to have a complete posterior circle significantly more often than South Asians ($p = .003$; figure 4).

In relation to ethnic variation for each sex separately, similar results regarding a complete posterior CoW were found for men (31.22% in White European compared to 15.17% in South Asian and 47.62% in African Caribbean men, $p = .001$ and $p = .017$; South Asian compared to African Caribbean, $p < .001$). For women, a complete posterior CoW was also significantly more frequently observed in African Caribbean (52.68%) compared to White European (34.89%) and South Asian (29.63%) women ($p = .005$ and $p = .001$), while the difference between White European and South Asian females was much less pronounced ($p = .464$).

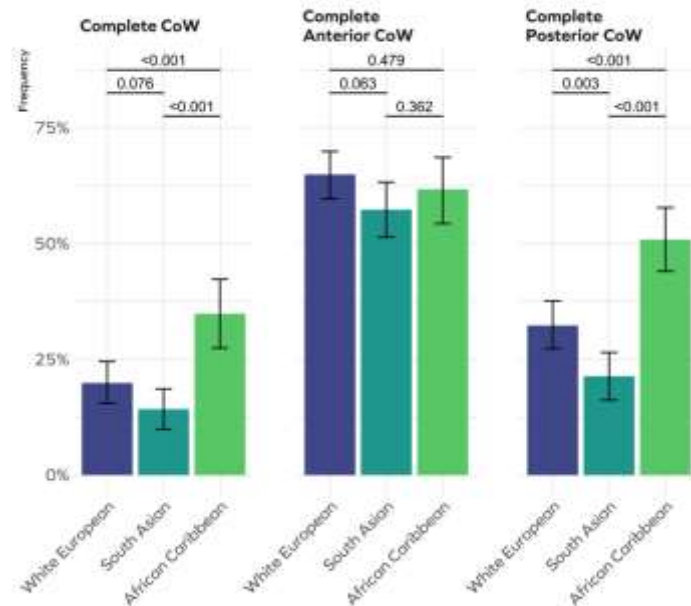


FIG 5. Barplots showing the frequency and 95% CI an overall complete circle of Willis, a complete anterior and complete posterior circle of Willis by ethnicity. Group-differences have estimated using Pearson's chi-squared test. CoW = Circle of Willis.

While there was no difference between women and men overall regarding the fetal-type configuration of the PCA ($p = .363$), a bilateral fetal PCA was found significantly more often in the African Caribbean population (17.14%) than the White European (11.49%) or South Asian populations (7.91%; $p = .008$ and $p < .001$). For women, no differences were found between the ethnic populations regarding the prevalence of either anatomical variant of the posterior CoW ($p = .932$). However, a bilateral fetal PCA was significantly more common among African Caribbean men (22.22%) than among either White European (10.24%) or South Asian men (4.83%; $p = .014$ and $p < .001$), while a bilateral normal PCA anatomy was more prevalent in South Asian (74.48%) compared to African Caribbean men (58.73%; $p = .024$). Furthermore, neither for the anterior, posterior, or combined anatomical variation of the circle of Willis significant evidence for an association between the occurrence of an aneurysm or its location has been found.

DISCUSSION

With a mean age of 71.28 ± 6.46 years (range 46–90 years), the volunteers in this study represent an elderly general population sample, comparable to the MRA-based analysis by Krabbe-Hartkamp et al [4] or the Insight 46 birth cohort and are slightly older than other population-based cohorts, such as the Rotterdam Scan Study [2; 3; 17].

This cohort represents a uniquely diverse sample of three different ethnic populations which is yet unmatched in the existing literature in the context of using high-resolution ToF MRA to investigate cerebrovascular imaging findings. White European subjects (42.93%) were relatively overrepresented compared to South Asian (33.73%) or African Caribbean subjects (23.33%).

Cerebral aneurysms were the most common incidental finding with no differences in prevalence between the three ethnic groups. The observed overall prevalence of 4.93% and particularly the prevalence among White Europeans (5.28%) is higher than that reported in other studies [3; 18].

Studies exploring the prevalence of intracranial aneurysms in African populations or African diaspora communities are rare: initial reports dealing with treatment of ruptured intracranial aneurysms appeared to show a lower incidence of intracranial aneurysms compared to Western populations [19]. More recent reports demonstrated however that intracranial aneurysms are not uncommon among African populations, a likely explanation being the wider availability of non-invasive neuroimaging [19-23]. This is, to our knowledge, the first study using 3T ToF MRA to report the prevalence of incidental unruptured intracranial aneurysms, and adjusting the OR for cerebrovascular risk factors, in an elderly African Caribbean sub-group (5.71%), thereby establishing an important reference for future investigations.

One might conjecture that the higher prevalence of intracranial aneurysms in this study could be related to the relatively advanced age of the study population. A comprehensive meta-analysis by Vlak et al [24] found, however, no significant relationship between age and unruptured intracranial aneurysms, except for a lower prevalence in subjects aged below 30 years of age [25; 26]. A more likely explanation for the higher prevalence of aneurysms in this study is the use of high-resolution 3T ToF MRA. Whereas medium and large size aneurysms can easily be detected on standard MRI sequences, small aneurysms may only be visible on 3T MRA imaging which has a higher diagnostic yield for aneurysms [27-29].

The second most common incidental cerebrovascular finding were ICAS (4.67%). Only a few reports mention the prevalence and epidemiology of ICAS in the general population accounting for additional vascular risk factors: Vernooij et al [3] observed large vessel stenosis in 9 patients (0.5%, 1.5T MRI) in an elderly Dutch cohort, while the US 'Atherosclerosis Risk in Communities' study found ICAS

prevalent in 31% of the study population, (67–90 years; 3T MRA), and estimated the US prevalence of ICAS >50% to be 8% for Whites and 12% for African-Americans aged 65–90 years old [30].

Ethnic disparities regarding the incidence and spatial distribution of arteriosclerotic cerebrovascular lesions were first reported in 1962 [31]. The significantly higher prevalence of ICAS > 50% in the South Asian population in our study – compared to both White and African Caribbean subjects – is not entirely unexpected, given the results from previous investigations [32–34]. In contrast to some previous reports, we did not observe a significant difference between African Caribbean and White European individuals, which is in line with some earlier findings [31; 33; 35]. The higher prevalence of ICAS among different ethnic groups has been explored in previous investigations, as it is a major cause of stroke in Asian and African populations, a fact that has been linked to genetic predisposition, morphological characteristics of the cerebral arteries, and divergent risk factor profiles [34; 36].

Regarding the overall prevalence of the morphological variants of the circle of Willis, types ‘a’ (39.33%) and ‘g’ (26.13%) were most commonly observed in the anterior CoW, and types ‘d’ (24.67%), ‘e’ (22.13%) and ‘a’ (19.33%) were the most common variants in the posterior compartment, which compares well to the results of previous investigations using the same classification [4; 37]. The most frequently found combinations of the anterior and posterior CoW types are hence in accordance with the existing literature. Considering the anatomical variability of the CoW in its entirety, a unilaterally absent PComA (posterior CoW type ‘d’) in combination with anterior CoW type ‘a’, was marginally more frequent ($n = 82$, 10.93%, 95% CI [8.79–13.39]) than type ‘a’, the haemodynamically ‘ideal’ arterial anatomy in both the anterior and posterior division ($n = 68$, 9.07%, 95% CI [7.11–11.35]). The topographical pattern of the CoW is determined during embryogenesis and it seems unlikely that any processes later in life can influence its configuration [6]. In adulthood, an absent or non-functional PComA, although asymptomatic under normal conditions, implies a less robust collateral circulation between the vertebrobasilar and internal carotid arterial systems [4; 6; 12]. Hence, in cases of a unilateral missing or non-functional PComA, a coincident AComA – as the dominant contributor to interhemispheric blood flow – is haemodynamically advantageous and key to preventing low-flow or borderzone infarcts in ipsilateral ICA stenoses or occlusions [38–41].

A study involving 1131 individuals with acute ischaemic stroke and 662 controls showed a higher prevalence of anatomical variations in the circle of Willis among stroke patients compared to controls, with the most prevalent variants identified were hypoplastic A1 segments and fetal-type PComA [5]. Another study found a less favourable prognosis in stroke patients with an incomplete circle of Willis [42].

In our study, significant differences in CoW anatomy were observed between women and men as well as between the different ethnic groups. These morphological differences do not relate to a single vascular configuration only but were observed in the overall structure of the entire circle, in the anterior and posterior divisions separately, and in relation to the configuration of the PCA. The present findings provide evidence for ethnic differences in the prevalence of an overall complete circle, as a complete CoW was more common in the African Caribbean compared to South Asian and White European populations overall.

Possible explanations for the high degree of variability in the CoW are developmental, partially transient, modifications or a genetic pattern for the CoW variations with recent evidence indicating a hereditary predisposition to incomplete PComA variants [11; 43–45]. Clinically, these results could contribute to an understanding of both sex and ethnic differences in cerebrovascular diseases, including stroke subtypes, risk of aneurysm formation, and distribution and volume of white matter hyperintensities [46–48].

There are some potential limitations to the present study. Unenhanced ToF MRA has some limitations in depicting turbulent or slow flow. The degree of ICAS may have potentially been overestimated due to intravoxel spin dephasing in turbulent flow and the prevalence of absent and hypoplastic AComA and PComA may have been slightly overestimated due to non-visualisation of slow flow in these vessels [4]. The effects of turbulent and slow flow were however mitigated by using an optimised high-resolution imaging protocol at 3T, significantly improving the signal-to-noise ratio, and allowing for a more detailed visualisation of smaller vessels secondary to prolonged T1 relaxation [49]. Sensitivity for detection of aneurysm with ToF MRA at 3T has been shown to be very high compared to DSA as gold standard [50]. Therefore, the chance of missing any potential small aneurysms is likely to be very low. We did not find a link between CoW anatomical variants and the observed incidental vascular pathologies, however, this could be attributed, at least partially, to the small number of specific incidental findings. A further potential limitation is the advanced age of SABRE participants; therefore, no comments can be made on the incidence arterial stenosis and aneurysm in younger age groups. Finally, as the main purpose of this investigation was to describe ethnic differences in the prevalence of incidental pathological cerebrovascular imaging findings and configurations of the CoW, we did not perform an exhaustive data collection on further possible arterial variants, such as for example persistent carotid-vertebrobasilar anastomoses, and abnormal origins of the ophthalmic or middle meningeal arteries.

CONCLUSIONS

In this large tri-ethnic population-based study we explored ethnic differences in the prevalence of incidental cerebrovascular imaging and CoW morphology. Ethnic differences were only found for ICAS with a higher prevalence in South Asians. Overall prevalence of aneurysm tended to be higher than in previous population-based studies which is likely to reflect the use of 3T high-resolution ToF MRA, allowing for better detection of small aneurysms. We furthermore observed differences in CoW configurations between women and men and ethnicities.

REFERENCES

1. Jäger HR, Grieve JP (2000) Advances in non-invasive imaging of intracranial vascular disease. *Annals of the Royal College of Surgeons of England* 82:1–5
2. Bos D, Poels MMF, Adams HHH et al (2016) Prevalence, Clinical Management, and Natural Course of Incidental Findings on Brain MR Images: The Population-based Rotterdam Scan Study. *Radiology* 281:507–515
3. Vernooij MW, Ikram MA, Tanghe HL et al (2007) Incidental Findings on Brain MRI in the General Population. *New England Journal of Medicine*

357:1821-1828

4. Krabbe-Hartkamp MJ, van der Grond J, de Leeuw FE et al (1998) Circle of Willis: morphologic variation on three-dimensional time-of-flight MR angiograms. *Radiology* 207:103-111
5. De Caro J, Ciacciarelli A, Tessitore A et al (2021) Variants of the circle of Willis in ischemic stroke patients. *Journal of Neurology* 268:3799-3807
6. Menshawi K, Mohr JP, Gutierrez J (2015) A Functional Perspective on the Embryology and Anatomy of the Cerebral Blood Supply. *Journal of Stroke* 17:144-158
7. Rinaldo L, McCutcheon BA, Snyder KA et al (2019) A1 segment hypoplasia associated with cerebral infarction after anterior communicating artery aneurysm rupture. *Journal of Neurosurgical Sciences* 63:359-364
8. Chuang YM, Liu CY, Pan PJ, Lin CP (2007) Anterior cerebral artery A1 segment hypoplasia may contribute to A1 hypoplasia syndrome. *European Neurology* 57:208-211
9. Hartkamp NS, Hendrikse J, De Cocker LJ, de Borst GJ, Kappelle LJ, Bokkers RP (2016) Misinterpretation of ischaemic infarct location in relationship to the cerebrovascular territories. *Journal of Neurology, Neurosurgery and Psychiatry* 87:1084-1090
10. Puchades-Orts A, Nombela-Gomez M, Ortuño-Pacheco G (1976) Variation in form of circle of Willis: some anatomical and embryological considerations. *Anatomical Record* 185:119-123
11. Lazorthes G, Gouazé A, Santini JJ, Salamon G (1979) Le cercle artériel du cerveau (circulus arteriosus cerebri). *Anatomia Clinica* 1:241-257
12. Riggs HE, Rupp C (1963) Variation in form of circle of Willis. The relation of the variations to collateral circulation: anatomic analysis. *Archives of Neurology* 8:8-14
13. Eftekhari B, Dadmehr M, Ansari S, Ghodsi M, Nazparvar B, Ketabchi E (2006) Are the distributions of variations of circle of Willis different in different populations? – Results of an anatomical study and review of literature. *BMC Neurology* 6:22
14. Jones S, Tillin T, Park C et al (2020) Cohort profile update: Southall and Brent revisited (SABRE) study: a UK population-based comparison of cardiovascular disease and diabetes in people of European, South Asian and African Caribbean heritage. *International Journal of Epidemiology*. 10.1093/ije/dyaa135
15. Chimowitz MI, Lynn MJ, Howlett-Smith H et al (2005) Comparison of warfarin and aspirin for symptomatic intracranial arterial stenosis. *New England Journal of Medicine* 352:1305-1316
16. Dimmick SJ, Faulder KC (2009) Normal Variants of the Cerebral Circulation at Multidetector CT Angiography. *Radiographics* 29:1027-1043
17. Keuss SE, Parker TD, Lane CA et al (2019) Incidental findings on brain imaging and blood tests: results from the first phase of Insight 46, a prospective observational substudy of the 1946 British birth cohort. *BMJ Open* 9:e029502
18. Sunny DE, Amoo M, Al Breiki M, Teng EDW, Henry J, Javadpour M (2022) Prevalence of incidental intracranial findings on magnetic resonance imaging: a systematic review and meta-analysis. *Acta Neurochirurgica* 164:2751-2765
19. Thioub M, Mbaye M, Thiam AB et al (2018) Microsurgical Treatment of Ruptured Intracranial Aneurysms in Sub-Saharan Africa: A Series of 102 Consecutive Cases Treated in Senegal. *World Neurosurgery* 110:226-231
20. Mudjir BD, Quenum K, Boutarbouch M et al (2006) Les anévrismes cérébraux ne sont pas rares au Maroc et probablement en Afrique. Notre expérience sur une série de 354 cas. *Neurochirurgie* 52:471
21. Nabaweesi-Batuka J, Kitunguu PK, Kiboi JG (2016) Pattern of Cerebral Aneurysms in a Kenyan Population as Seen at an Urban Hospital. *World Neurosurgery* 87:255-265
22. Ogeng'o JA, Otieno BO, Kilonzi J, Sinkeet SR, Muthoka JM (2009) Intracranial aneurysms in an African country. *Neurology India* 57:613-616
23. Ohaegbulam S, Dujovny M, Ausman J, Diaz F, Malik G (1990) Ethnic distribution of intracranial aneurysms. *Acta Neurochirurgica* 106:132-135
24. Vlak MHM, Algra A, Brandenburg R, Rinkel GJE (2011) Prevalence of unruptured intracranial aneurysms, with emphasis on sex, age, comorbidity, country, and time period: a systematic review and meta-analysis. *The Lancet Neurology* 10:626-636
25. Imaizumi Y, Mizutani T, Shimizu K, Sato Y, Taguchi J (2018) Detection rates and sites of unruptured intracranial aneurysms according to sex and age: an analysis of MR angiography-based brain examinations of 4070 healthy Japanese adults. *Journal of Neurosurgery* 130:573-578
26. Juvela S, Porras M, Heiskanen O (1993) Natural history of unruptured intracranial aneurysms: a long-term follow-up study. *Journal of Neurosurgery* 79:174-182
27. Kapsalaki EZ, Rountas CD, Fountas KN (2012) The Role of 3 Tesla MRA in the Detection of Intracranial Aneurysms. *International Journal of*
28. Sailer AM, Wagemans BA, Nelemans PJ, de Graaf R, van Zwam WH (2014) Diagnosing intracranial aneurysms with MR angiography: systematic review and meta-analysis. *Stroke* 45:119-126
29. Li MH, Li YD, Gu BX et al (2014) Accurate diagnosis of small cerebral aneurysms ≤ 5 mm in diameter with 3.0-T MR angiography. *Radiology* 271:553-560
30. Suri MF, Qiao Y, Ma X et al (2016) Prevalence of Intracranial Atherosclerotic Stenosis Using High-Resolution Magnetic Resonance Angiography in the General Population: The Atherosclerosis Risk in Communities Study. *Stroke* 47:1187-1193
31. Bauer RB, Sheehan S, Wechsler N, Meyer JS (1962) Arteriographic study of sites, incidence, and treatment of arteriosclerotic cerebrovascular lesions. *Neurology* 12:698-698
32. Inzitari D, Hachinski VC, Taylor DW, Barnett HJM (1990) Racial Differences in the Anterior Circulation in Cerebrovascular Disease: How Much Can Be Explained by Risk Factors? *Archives of Neurology* 47:1080-1084
33. Sacco RL, Kargman DE, Gu Q, Zamanillo MC (1995) Race-ethnicity and determinants of intracranial atherosclerotic cerebral infarction. The Northern Manhattan Stroke Study. *Stroke* 26:14-20
34. Kim JS, Kim YJ, Ahn SH, Kim BJ (2018) Location of cerebral atherosclerosis: Why is there a difference between East and West? *International Journal of Stroke* 13:35-46
35. Wityk RJ, Lehman D, Klag M, Coresh J, Ahn H, Litt B (1996) Race and Sex Differences in the Distribution of Cerebral Atherosclerosis. *Stroke* 27:1974-1980
36. Liu M, Gutierrez J (2020) Genetic Risk Factors of Intracranial Atherosclerosis. *Current Atherosclerosis Reports* 22:13
37. El-Barhoun EN, Gledhill SR, Pitman AG (2009) Circle of Willis artery diameters on MR angiography: an Australian reference database. *Journal of Medical Imaging and Radiation Oncology* 53:248-260
38. Lopez-Bresnahan MV, Kears LA, Jr., Yanez P, Young TI (1993) Anterior communicating artery collateral flow protection against ischemic change during carotid endarterectomy. *Journal of Neurosurgery* 79:379-382
39. Miralles M, Dolz JL, Cotillas J et al (1995) The role of the circle of Willis in carotid occlusion: assessment with phase contrast MR angiography and transcranial duplex. *European Journal of Vascular and Endovascular Surgery* 10:424-430
40. Schomer DF, Marks MP, Steinberg GK et al (1994) The anatomy of the posterior communicating artery as a risk factor for ischemic cerebral infarction. *New England Journal of Medicine* 330:1565-1570
41. Liebeskind DS (2003) Collateral circulation. *Stroke* 34:2279-2284

42. Lin E, Kamel H, Gupta A, RoyChoudhury A, Girgis P, Glodzik L (2022) Incomplete circle of Willis variants and stroke outcome. *European Journal of Radiology* 153:110383
43. Sánchez van Kammen M, Moomaw CJ, van der Schaaf IC et al (2018) Heritability of circle of Willis variations in families with intracranial aneurysms. *PloS One* 13:e0191974
44. Stehbens WE (1989) Etiology of intracranial berry aneurysms. *Journal of Neurosurgery* 70:823-831
45. van Overbeeke JJ, Hillen B, Tulleken CA (1991) A comparative study of the circle of Willis in fetal and adult life. The configuration of the posterior bifurcation of the posterior communicating artery. *Journal of Anatomy* 176:45-54
46. Hoksbergen AW, Legemate DA, Csiba L, Csati G, Siro P, Fulesdi B (2003) Absent collateral function of the circle of Willis as risk factor for ischemic stroke. *Cerebrovascular Diseases* 16:191-198
47. Gulli G, Rutten-Jacobs LC, Kalra L, Rudd AG, Wolfe CD, Markus HS (2016) Differences in the distribution of stroke subtypes in a UK black stroke population - final results from the South London Ethnicity and Stroke Study. *BMC Medicine* 14:77
48. Saba L, Sanfilippo R, Porcu M et al (2017) Relationship between white matter hyperintensities volume and the circle of Willis configurations in patients with carotid artery pathology. *European Journal of Radiology* 89:111-116
49. Schmitz BL, Aschoff AJ, Hoffmann MHK, Grön G (2005) Advantages and Pitfalls in 3T MR Brain Imaging: A Pictorial Review. *American Journal of Neuroradiology* 26:2229-2237
50. Li MH, Li YD, Tan HQ et al (2011) Contrast-free MRA at 3.0 T for the detection of intracranial aneurysms. *Neurology* 77:667-676

SUPPLEMENTAL FILES

Online Supplemental Data: Participant characteristics, overall, by sex and ethnicity.

		Total			White European			South Asian			African Caribbean		
		n	Mean \pm SD	range	n	Mean \pm SD	range	n	Mean \pm SD	range	n	Mean \pm SD	range
Age (years)	Total	750	71.28 \pm 6.56	46-90	322	72.44 \pm 5.94	46-90	253	71.04 \pm 6.09	49-90	175	69.49 \pm 7.40	54-90
	Women	337	69.05 \pm 6.77	46-89	117	70.57 \pm 6.69	46-88	108	68.25 \pm 6.18	49-83	112	68.23 \pm 7.17	54-89
	Men	413	73.09 \pm 5.51	57-90	205	73.50 \pm 5.18	64-90	145	73.11 \pm 5.14	65-90	63	71.71 \pm 7.35	57-90
		n	Prevalence	%	n	Prevalence	%	n	Prevalence	%	n	Prevalence	%
Normal BP* (systolic <130, diastolic <80)	Total	750	423	56.40	322	196	60.87	253	147	58.10	175	80	45.71
	Women	337	191	56.68	117	78	66.67	108	58	54.70	112	55	49.11
	Men	413	232	56.17	205	118	57.56	145	89	61.38	63	25	39.68
Stage 1 hypertension* (systolic <140, diastolic <90)	Total	750	206	27.47	322	81	25.16	253	66	26.09	175	59	33.71
	Women	337	94	27.89	117	25	21.37	108	35	32.41	112	34	30.36
	Men	413	112	27.12	205	56	27.32	145	31	21.38	63	25	39.68
Stage 2 hypertension* (systolic >140, diastolic >90)	Total	750	121	16.13	322	45	13.98	253	40	15.81	175	36	20.57
	Women	337	52	15.43	117	14	11.97	108	15	13.89	112	23	20.54
	Men	413	69	16.71	205	31	15.12	145	25	17.24	63	13	20.63
Diabetes	Total	748	162	21.66	322	42	13.04	253	73	28.85	173	47	27.17
	Women	335	72	21.49	117	12	10.26	108	26	24.07	110	34	30.91
	Men	413	90	21.79	205	30	14.63	145	47	32.41	63	13	20.63
Hypercholesterinaemia (LDL > 3mmol/l; 116 mg/dl)	Total	750	210	28.00	322	95	29.50	253	62	24.51	175	53	30.29
	Women	337	112	33.23	117	48	41.03	108	30	27.78	112	34	30.36
	Men	413	98	23.73	205	47	22.93	145	32	22.07	63	19	30.16

Note: Values (n) are number of subjects. BP = blood pressure.

*American College of Cardiology (ACC)/American Heart Association (AHA) guideline on high blood pressure (2017).

Supplementary Table 1: Frequency of CoW variants

Posterior CoW							Anterior CoW						Total
	a	b	c	c3	d	e	Azg.	g*	h*	h3*	BiHemACA*	ACAHA*	
a	68	4	11	0	15	2	3	32	7	1	1	1	145
b	28	3	4	0	1	1	0	16	8	0	0	1	62
c	13	2	2	0	4	0	0	12	5	0	1	0	39
c-SCA	0	0	0	0	0	0	0	1	0	0	0	0	1
d	82	4	10	0	17	4	2	48	16	2	0	0	185
e*	57	8	13	2	11	3	0	52	14	2	1	3	166
f*	13	0	5	0	4	0	0	7	4	1	0	1	35
g*	9	1	3	0	6	1	0	8	6	0	0	0	34
h*	9	0	1	0	7	0	0	7	6	3	1	0	34
i*	6	0	0	0	4	0	0	6	2	0	0	0	18
j*	9	0	3	1	5	0	0	7	4	0	0	0	29
PDUP*	1	0	0	0	0	0	0	0	1	0	0	0	2
Total	295	22	52	3	74	11	5	196	73	9	4	6	750

Note: CoW = Circle of Willis; ACAHA = Unilateral anterior cerebral artery hypoplasia, Azg. = Azygous anterior cerebral artery, BiHemACA = Bihemispheric anterior cerebral artery, PDUP = Ipsilateral duplication of the posterior cerebral artery, c-SCA = Posterior cerebral artery P1 segment arising from the ipsilateral superior cerebellar artery, c3 = Duplication of the median artery of the corpus callosum, h3 = Unilateral anterior cerebral artery trifurcation, * Incomplete.

Supplementary Table 2: Multivariate logistic regression models used to estimate the odds ratios for incidental cerebrovascular findings.

	Model 1			Model 2			Model 3		
	ICAS			ICAS			Aneurysm		
	OR	95% CI	p value	OR	95% CI	p value	OR	95% CI	p value
<i>Female</i>	<i>1</i>	<i>[1, 1]</i>	.	<i>1</i>	<i>[1, 1]</i>	.	<i>1</i>	<i>[1, 1]</i>	.
Male	1.325	[0.612, 2.872]	0.475	1.325	[0.612, 2.872]	0.475	0.693	[0.342, 1.404]	0.309
<i>White European</i>	<i>1</i>	<i>[1, 1]</i>	.	<i>1.027</i>	<i>[0.332, 3.177]</i>	<i>0.963</i>	<i>1</i>	<i>[1, 1]</i>	.
South Asian	2.720*	[1.218, 6.076]	0.015	2.794	[0.998, 7.823]	0.051	0.844	[0.375, 1.901]	0.682
African Caribbean	0.974	[0.315, 3.012]	0.963	<i>1</i>	<i>[1, 1]</i>	.	1.277	[0.551, 2.962]	0.569
<i>Hypercholesterolemia: No</i>	<i>1</i>	<i>[1, 1]</i>	.	<i>1</i>	<i>[1, 1]</i>	.	<i>1</i>	<i>[1, 1]</i>	.
Hypercholesterolemia: Yes (LDL > 3mmol/l; 116 mg/dl)	1.260	[0.555, 2.861]	0.580	1.260	[0.555, 2.861]	0.580	0.864	[0.390, 1.913]	0.718
<i>Normal BP[†]</i> (systolic <130, diastolic <80)	<i>1</i>	<i>[1, 1]</i>	.	<i>1</i>	<i>[1, 1]</i>	.	<i>1</i>	<i>[1, 1]</i>	.
Stage 1 hypertension[†] (systolic <140, diastolic <90)	1.882	[0.893, 3.969]	0.097	1.882	[0.893, 3.969]	0.097	1.096	[0.512, 2.348]	0.813
Stage 2 hypertension[†] (systolic >140, diastolic >90)	0.374	[0.084, 1.665]	0.197	0.374	[0.084, 1.665]	0.197	0.697	[0.231, 2.105]	0.522
Age (years)	1.053	[0.991, 1.118]	0.094	1.053	[0.991, 1.118]	0.094	1.064*	[1.007, 1.123]	0.026
<i>Diabetes: No</i>	<i>1</i>	<i>[1, 1]</i>	.	<i>1</i>	<i>[1, 1]</i>	.	<i>1</i>	<i>[1, 1]</i>	.
Diabetes: Yes	2.140*	[1.017, 4.503]	0.045	2.140*	[1.017, 4.503]	0.045	0.531	[0.200, 1.409]	0.203
Observations	748			748			748		
p	0.005			0.005			0.348		

Note: ICAS = Intracranial arterial stenoses. Model 1, ICAS: White European ethnicity used as base category. Model 2, ICAS: African Caribbean ethnicity used as base category. Model 3, Aneurysm: White European ethnicity used as base category. OR = Odds ratio; Exponentiated coefficients; 95% confidence intervals in brackets. Italics identify base category. * $p < 0.05$, ** $p < 0.01$, *** $p < 0.001$ [†]American College of Cardiology (ACC)/American Heart Association (AHA) guideline on high blood pressure (2017).