



## Discover Generics

Cost-Effective CT & MRI Contrast Agents



WATCH VIDEO

# AJNR

## Pressure Cooker Technique for Endovascular Treatment of Spinal Arteriovenous Fistulas: Experience in 15 Cases

F. Clarençon, C.P. Stracke, E. Shotar, M. Wallocha, P.J. Mosimann, A.-L. Boch, N. Sourour and R. Chapot

This information is current as of June 16, 2025.

*AJNR Am J Neuroradiol* published online 25 March 2021  
<http://www.ajnr.org/content/early/2021/03/25/ajnr.A7078>

# Pressure Cooker Technique for Endovascular Treatment of Spinal Arteriovenous Fistulas: Experience in 15 Cases

 F. Clarençon,  C.P. Stracke,  E. Shotar,  M. Wallocha,  P.J. Mosimann,  A.-L. Boch,  N. Sourour, and  R. Chapot



## ABSTRACT

**BACKGROUND AND PURPOSE:** Spinal arteriovenous fistulas are challenging to cure by endovascular means, with a risk of incomplete occlusion or delayed recurrence. The authors report herein their preliminary experience using the pressure cooker technique for the embolization of spinal arteriovenous fistulas.

**MATERIALS AND METHODS:** Fifteen patients (8 men; mean age, 60.3 years) underwent an endovascular treatment of a spinal arteriovenous fistula (12 dural spinal arteriovenous fistulas and 3 epidural spinal arteriovenous fistulas) in 2 different institutions using the pressure cooker technique. Two microcatheters could be navigated in the segmental artery in all patients using 2 guiding catheters. A proximal plug was achieved with highly concentrated cyanoacrylate  $\pm$  coils. The liquid embolic agent injected to cure the fistula was diluted cyanoacrylate ( $n = 11$ ) or ethylene-vinyl alcohol ( $n = 4$ ). Technical and clinical complications were systematically recorded. Clinical and angiographic outcomes were systematically evaluated at follow-up.

**RESULTS:** One (6.7%) procedure-related complication was recorded, which consisted of a transient radicular deficit, related to nerve root ischemia. Clinical improvement was observed in 10/14 (71%) patients for whom clinical follow-up was available. Complete spinal arteriovenous fistula occlusion on a follow-up angiography was observed in 11/12 patients (91.7%) for whom angiographic follow-up was available. One patient (8.3%) presented with a delayed recurrence at 29 months.

**CONCLUSIONS:** The pressure cooker technique is feasible, with either glue or ethylene-vinyl alcohol, for the embolization of spinal arteriovenous fistulas. Our results suggest the safety and effectiveness of this technique.

**ABBREVIATIONS:** EVOH = ethylene-vinyl alcohol; IQR = interquartile range; PCT = pressure cooker technique; SAVF = spinal arteriovenous fistula

Spinal arteriovenous fistulas (SAVFs) are rare vascular malformations involving the spinal cord and corresponding to an abnormal arteriovenous shunt between spinal dural arteries and a radicular vein or the epidural venous plexus, which “contaminates” secondarily the spinal venous drainage.<sup>1,2</sup> Most of these SAVFs are clinically revealed by a venous congestion, responsible for progressive sensory and/or motor deficits of the inferior limbs, often associated with sphincter disturbance (ie, urinary/fecal incontinence, sexual impotence).<sup>3</sup>

The best treatment option for SAVFs is still a matter of debate because no randomized controlled trial has compared endovascular treatment and surgery. Even if it is minimally invasive, the main drawback of the endovascular treatment is the risk of incomplete occlusion of the shunt point, which may lead to treatment failure or recurrence.<sup>4</sup>

The pressure cooker technique (PCT) has been developed to improve the penetration of liquid embolic agents in the embolization of brain AVMs, increasing the occlusion rate in the endovascular treatment of brain AVMs.<sup>5</sup>

The purpose of our study was to report our experience with the PCT for the endovascular treatment of SAVFs.

## MATERIALS AND METHODS

### Patient Selection


All patients treated for an SAVF in 2 institutions (Alfried Krupp Krankenhaus, Essen, Germany, and Pitié-Salpêtrière Hospital, Paris, France) from 2012 to 2020 by endovascular means were systematically reviewed. Patient demographics (age, sex) as well

Received October 26, 2020; accepted after revision January 12, 2021.

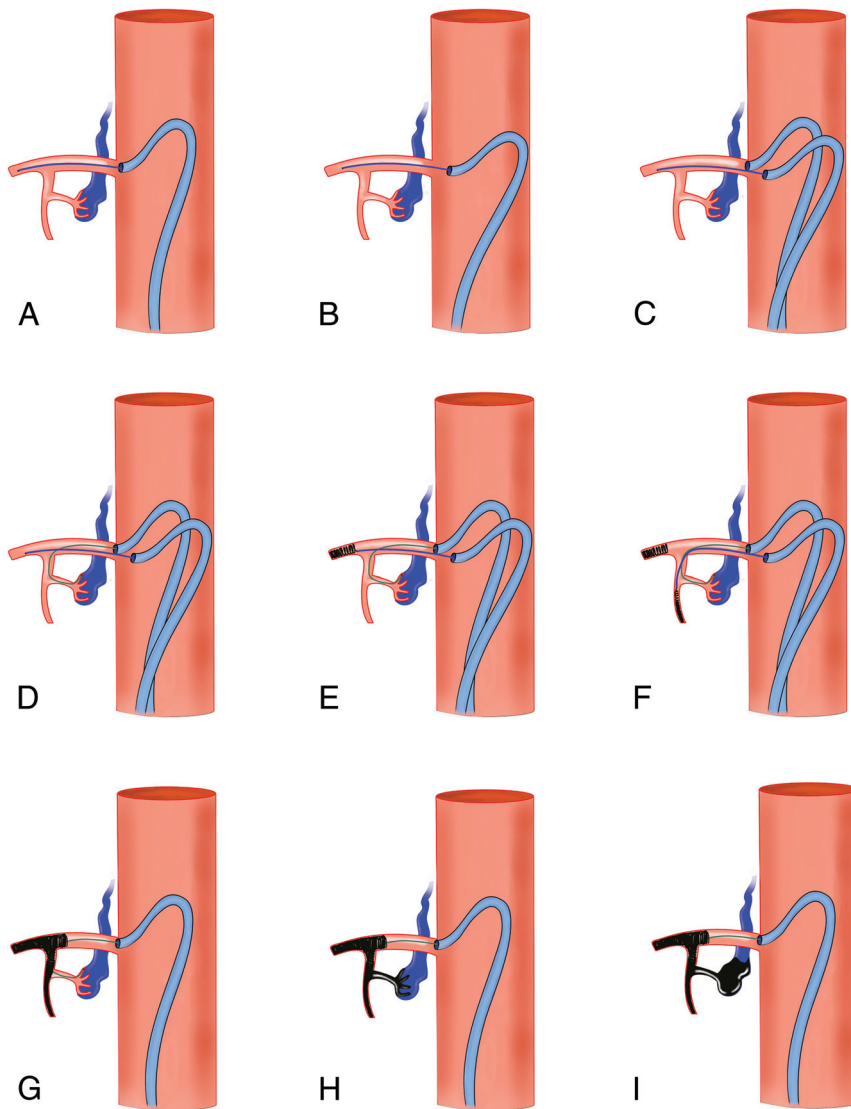
From the Departments of Neuroradiology (F.C., E.S., N.S.) and Neurosurgery (A.-L.B.), Assistance Publique-Hôpitaux de Paris, Pitié-Salpêtrière Hospital, Paris, France; Sorbonne University (F.C.), Paris, France; Groupe de Recherche Clinique BIOFAST (F.C.), Paris VI University, Paris, France; and Department of Interventional Neuroradiology (C.P.S., M.W., P.J.M., R.C.), Alfried Krupp Krankenhaus, Essen, Germany.

Data are available upon request from the corresponding author.

Please address correspondence to Frédéric Clarençon, MD, PhD, Department of Neuroradiology, Pitié-Salpêtrière Hospital, 47, Boulevard de l'Hôpital, 75013, Paris, France; e-mail: frederic.clarencon@aphp.fr

 Indicates article with online supplemental data.

<http://dx.doi.org/10.3174/ajnr.A7078>



**FIG 1.** Drawing summarizing the different steps for the PCT in spinal vascular malformation embolization. A, Positioning the microcatheter No. 1 (for coiling) distally in the main trunk of the segmental artery, via the guiding catheter No. 1. B, The guiding catheter No. 1 is disengaged from the segmental artery ostium. C, The guiding catheter No. 2 is subsequently positioned at the ostium of the segmental artery. D, The microcatheter No. 2 (dedicated to the liquid embolic agent injection for the arteriovenous fistula treatment) is navigated via the guiding catheter No. 2 as close as possible to the shunt point. E, Coiling of the main trunk is performed via microcatheter No. 1 until occlusion. F and G, The dorsal branch and then the dorsospinal trunk are subsequently coiled until occlusion via the microcatheter No. 1 to obtain the proximal plug of the pressure cooker. H and I, Liquid embolic injection via the microcatheter No. 2 is performed until the filling of the origin of the draining vein.

as clinically revealing symptoms and the time interval between symptom onset and endovascular treatment were systematically recorded.

### Clinical Evaluation

A pretreatment clinical examination was systematically performed by a neurologist who was not directly involved in the endovascular treatment. Clinical symptoms, as well as the duration between symptom appearance and SAVF diagnosis,

were systematically recorded. Symptom severity was evaluated using the Aminoff-Logue instability scale.<sup>6</sup>

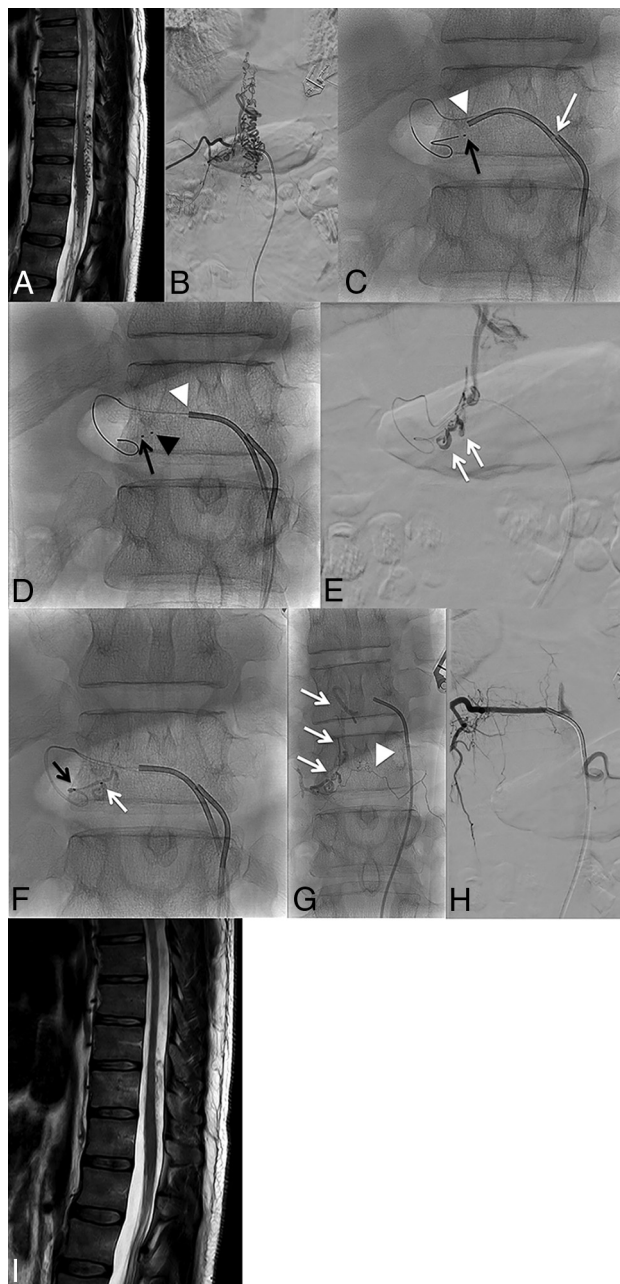
### Endovascular Procedures

All patients were treated under general anesthesia, via a bilateral 5F femoral access under full anticoagulation. A first 5F catheter (usually a Cobra Small catheter; Cook or a Simmons [1 or 2] catheter; Merit Medical) was positioned at the ostium of the segmental artery feeding the SAVF. A microcatheter (1.2F or 0.017 inch) was navigated into the segmental artery. The 5F catheter was then disengaged from the ostium of the segmental artery but kept at that level. A second 5F guiding catheter was positioned at the ostium of the same segmental artery. A second microcatheter was then navigated into the segmental and later into the radiculomeningeal artery as close as possible to the shunt point. To reduce the risk of embolic agent migration, we placed coils through the first microcatheter in the main trunk of the segmental artery, distal to the origin of the dorsospinal trunk and/or the dorsal branch of the segmental artery. Afterward, a proximal plug was performed using high-concentrated *n*-BCA (ie, 50% *n*-BCA in combination with Lipiodol; Guerbet) (Fig 1). The fistula was then occluded by injection of low-concentrated *n*-BCA (20% *n*-BCA, 80% Lipiodol) (*n* = 11) (Fig 2) or an ethylene-vinyl alcohol (EVOH) copolymer (*n* = 4) (Fig 3) through the second microcatheter. Injection was maintained until occlusion of the origin of the draining vein.

For SAVFs embolized with the PCT using glue as a liquid embolic agent, microcatheters without detachable tip were used (Echelon 10 [Medtronic] or the Marathon [Medtronic]). On the contrary, when EVOH was used to occlude the fistula, a detachable-tip microcatheter was systematically used (Apollo Medtronic).

### Feasibility and Safety

Technical failures and complications were systematically recorded. Complications were systematically assessed and graded using the Cardiovascular and Interventional Radiological Society of Europe and Society of Interventional Radiology complication guidelines.<sup>7</sup> Briefly, this classification is a 6-scale grading system evaluating the severity of the complication: grade 3 being a complication requiring



**FIG 2.** Patient in his or her 40's presenting with lower limb paresthesia, constipation, and bladder disturbance lasting for 36 months. *A*, Spinal cord MR imaging. T2WI, sagittal section, shows the hyperintense signal of the spinal cord extending up to T8 and multiple flow void signals in the enlarged spinal veins. *B*, Spinal DSA. Right T11 angiogram in a postero-anterior projection shows a spinal arteriovenous fistula with both ascending and descending venous drainage. *C*, Navigation of the microcatheter No. 1 (dedicated to the PCT plug) (black arrow). Then, the guiding catheter No. 1 is disengaged from the right T11 intercostal artery (white arrow). The guiding catheter No. 2 is subsequently positioned at the ostium of the segmental artery (white arrowhead). *D*, Navigation of the second microcatheter (No. 2) (black arrowhead) from the guiding catheter No. 2 (white arrowhead) as close as possible to the shunt point. Note the tip of microcatheter No. 1, located proximal to the tip of microcatheter No. 2. *E*, Ultrasensitive angiogram in a postero-anterior projection from microcatheter No. 2. The origin of the main draining vein (radicular vein) is clearly seen (double white arrow). *F*, PCT. Injection of 50% *n*-BCA through microcatheter No. 1 to create the proximal plug (black arrow). Then, injection of a 20% dilution of *n*-BCA is performed to embolize the fistula (white arrow). *G*, Plain x-ray in a postero-anterior projection shows the glue cast. Note the filling of the origin of the radicular vein (white arrows) and also progression of the liquid embolic agent through the retrocorporeal anastomosis (white arrowhead). *H*, Right T11 angiogram at the end of the procedure shows complete occlusion of the fistula. *I*, Spinal cord MR imaging 14 months after embolization. T2WI, sagittal section, shows complete resolution of the spinal cord edema.

additional postprocedural therapy or prolonged hospital stay (48 hours) but with no sequelae; grade 4 being a complication causing permanent mild sequelae; and grade 5 being a complication causing permanent severe sequelae.

### Clinical and Imaging Follow-up

The clinical examination was performed  $\geq 3$  months after the procedure, in most cases by the operator who performed the procedure. Spinal DSA was performed systematically at  $\geq 3$  months to rule out a SAVF recurrence.

### Statistical Analysis

Data were reported as mean [SD] for continuous variables and median with interquartile range (IQR) for noncontinuous variables. All tests were calculated using STATA software (Stata/IC 13.1 for Mac; StataCorp); *P* values  $< .05$  were considered statistically significant.

### Ethics Statement

The choice to treat these patients by endovascular means was made through a multidisciplinary meeting, including neurosurgeons and interventional neuroradiologists. Patients were informed before each treatment of the strategy that was chosen and gave an oral consent.

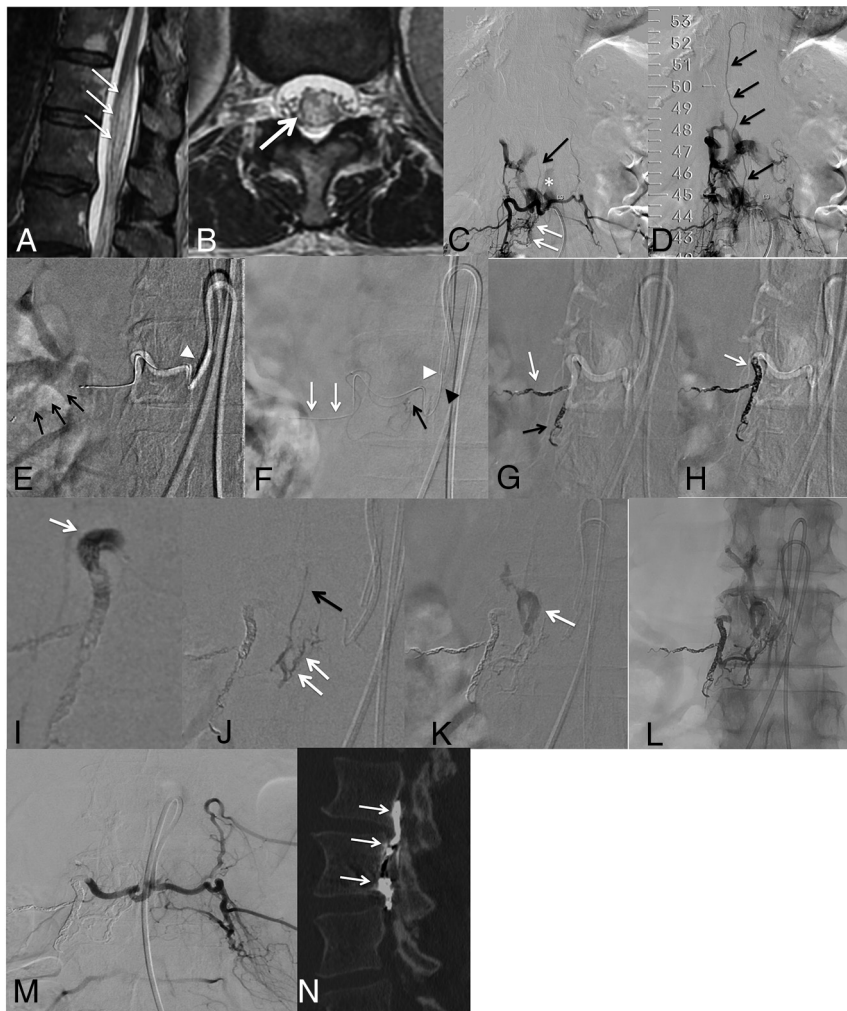
This work received approval from both institutional review board (institutional review approval No. HH 16\_4\_20b). The need for patients' informed consent for retrospective analyses of records and imaging data was waived by our institutional review board. This work adheres to the World Medical Association's Declaration of Helsinki.

## RESULTS

### Patient Demographics

Among the patients treated for a spinal arteriovenous fistula in the 2 institutions during the inclusion period, 15 patients (8 men [53%]; mean age, 60.3 [SD, 16.7] years) were treated using the PCT (Online Supplemental Data). The PCT was chosen in these patients due to the inability to bring the microcatheter into a wedge flow position with a risk of poor progression of the liquid embolic agent beyond the shunt. In 2/15 cases





**FIG 3.** Patient in his or her 60's presenting with a 4-year history of paresthesia of the inferior limbs, bladder disturbance, and constipation. Spinal cord MR imaging. T2WI, sagittal (A) and axial (B) slices show a centromedullar hyperintense signal (white arrows) and lumbar spinal cord enlargement. Spinal DSA. Right L3 selective angiogram in a postero-anterior projection at an early phase (C) and intermediate phase (D). Numerous dural branches from the right L3 spinal trunk are depicted (C, white arrows), with abnormal connection with the right aspect of the epidural plexus (C, asterisk). Reflux from the anterior epidural plexus to a radicular vein is seen (C and D, black arrows), with an ascending drainage. E, Navigation of a 0.017-inch microcatheter via a 5F Simmons 1 catheter (white arrowhead). The microcatheter is stabilized by deploying a Catch Mini stent retriever (black arrows); then the guiding catheter is gently pulled away from the right L3 ostium. F, An Apollo (5-cm detachable tip) microcatheter is then navigated in the spinal trunk of the right L3 artery, as close as possible to the shunt point (black arrow). Selective DSA via the Apollo microcatheter in a postero-anterior projection. Note the guiding catheter (5F Simmons 1) at the ostium of the right L3 artery (black arrowhead), while the second one is stabilized in front of it (white arrowhead). Note the second 0.017-inch microcatheter that has been left in the main trunk of right L3 artery (white arrows). Coiling, via the 0.017-inch microcatheter, of the main L3 trunk (G, white arrow), then the dorso-spinal trunk (G, black arrow) and the arterial segment before arising from the dorso-spinal trunk (H, white arrow) to obtain the proximal plug of the pressure cooker. Finally, a 50% dilution *n*-BCA injection was performed at the proximal aspect of the cast of the coils through the 0.017-inch microcatheter (I, white arrow) to ensure that the proximal plug would be occlusive. Then, Squid 12 (Balt) was injected under a blank roadmap through the Apollo catheter until occlusion of the shunt point along the anterior epidural venous plexus (J and K, white arrows) and filling of the origin of the radicular vein (J, black arrow). L, Plain x-ray in a postero-anterior projection at the end of the Squid 12 injection shows the EVOH cast. M, Final control DSA in a postero-anterior projection via the common trunk feeding both the right and left L3 arteries, showing complete occlusion of the fistula. N, Postprocedural unenhanced CT scan, bone windowing. Sagittal reconstruction shows the EVOH cast in the anterior epidural venous plexus (white arrows).

(13.3%), the embolization was performed after a recurrence in patients previously treated by *n*-BCA injection without the PCT. Most interesting, 2 patients (13.3%) were previously treated surgically for a spinal canal stenosis.

In 60% of the patients (9/15), sensory symptoms (paresthesia, dysesthesia) were recorded; genitourinary dysfunction (fecal and/or urinary retention) was observed in 53.3% of the cases (8/15). Inferior limb motor weakness was observed in 40% of the cases (6/15). Finally, in 2 cases (13.3%), lumbar pain was recorded, for which there was no clear relationship with the SAVF.

The median Aminoff-Logue disability scale<sup>6</sup> score before exclusion treatment was 3 (IQR, 2–4.5) (sensory signs: median = 2 [IQR, 1.5–2.5]; micturition: median = 1 [IQR, 0–2]).

### Angiographic Features of the SAVF

Most SAVFs were dural AVFs (12/15, 80%); the 3 remaining patients (20%) had epidural AVFs (Online Supplemental Data). Most SAVFs were located at the thoracic level (9/15, 60%), 3 SAVFs (20%) were located at the lumbar level, and 3 (20%) were sacral dural AVFs. In 46.7% of the patients (7/15), the venous drainage was purely ascending; in 7/15 patients (46.7%), it was both ascending and descending; and in the remaining one (7%), it was purely descending.

### Feasibility and Safety

No catheterization failure was recorded. Two guiding catheters could be successively placed in the segmental artery, and a microcatheter was further navigated in all patients. The embolic agent could be brought up to the vein in 14/15 patients (93.3%). The retrieval of all microcatheters was uneventful. Specifically, no glued microcatheter or reflux of embolic agent in the aorta was reported.

No major complication was recorded in our series. Only 1 minor complication (grade 3 in the Cardiovascular and Interventional Radiological Society of Europe/Society of Interventional Radiology classification<sup>7</sup>) was observed, which consisted of an L3 nerve root lesion revealed by pain and motor deficit

in an L3 epidural AVF. This complication was reversible; the patient recovered under anti-inflammatory medication with no sequelae.

### **Immediate Angiographic Outcome/Imaging Follow-up**

Immediate complete occlusion of the SAVF was observed in 15/15 patients. No residual shunt was depicted at the end of the procedure in any case. Follow-up spinal DSA was available in 12/15 patients (80%) at a mean time interval of 6.7 [SD, 7.6] months from the procedure (range, 3–29 months). Complete persistent occlusion of the AVF was observed 11/12 patients (91.7%).

### **Clinical Follow-up**

Clinical follow-up was available in 14/15 patients (93.3%), with a mean time interval of 7.3 [SD, 8.4] months (range, 3–29 months). One patient died at 1 month from a myocardial infarction.

Patients experienced clinical improvement in 71.4% (10/14) of cases. Three patients (21.4%) were stable, and 1 patient (7.2%) presented with a delayed clinical worsening at 29 months, related to a SAVF recurrence, which was subsequently treated by microsurgery.

The median Aminoff-Logue distability scale<sup>6</sup> score at clinical follow-up was 2.5 (IQR, 1–4.5) (sensory signs: median = 1.5 [IQR, 0.25–2.75]; micturition: median = 0 [IQR, 0–1.75]).

## **DISCUSSION**

Embolization of dural/epidural arteriovenous fistulas may be challenging. The 2 major drawbacks for SAVF embolization are the following: 1) the noncontrolled embolic agent migration into a radiculomedullary artery, potentially responsible for neurologic complications, and 2) incomplete occlusion of the shunt point, with an unrecognized persistent SAVF and clinical worsening. This delay may finally hamper the recovery of the patient's symptoms.<sup>8</sup> A recent meta-analysis<sup>9</sup> showed that among patients treated for SAVFs, a surgical operation had better results in terms of complete occlusion and clinical outcome compared with endovascular embolization. Indeed, SAVF recurrence was observed, ranging up to 3.7% of patients with surgical treatment versus up to 40% with embolization.<sup>9</sup> Additionally, in patients treated by endovascular means, the same meta-analysis showed that the risk of failure/late recurrence was higher with EVOH than with *n*-BCA (OR = 3.87; 95% CI, 1.73–8.68;  $P < .001$ ).<sup>9</sup> Indeed, the chance to penetrate distally when using EVOH is lower (without using a PCT) because important reflux is often seen, toward the aorta, prompting the operator to stop the injection, despite non-occlusion of the shunt point. These results lead some interventional neuroradiologists to discourage the endovascular option as a first-line treatment and to prefer an a surgical operation.<sup>10</sup> Our experience in the embolization of intracranial vascular malformations using the PCT led us to use this technique in SAVF.

The pressure cooker technique was first described for the embolization of intracranial vascular malformations.<sup>5</sup> Its principle is to combine 2 liquid embolic agents that do not interact. The goal is first to avoid an excessive and uncontrolled retrograde reflux of embolic agent and second to increase the distal diffusion of the embolic agent. The potential of the PCT for the embolization of spinal vascular malformations (SVM) has been assessed only in oral presentations up to now.<sup>11</sup>

Unlike in the initial description of the PCT, we did not use only EVOH but also low-concentrated *n*-BCA as an embolic agent for the SVM. This was left to the discretion of the operator. The advantage of using the EVOH copolymer is its better visibility under a blank roadmap. On the other hand, the advantage of using *n*-BCA is that there is no need for dimethyl-sulfoxide; thus, non-dimethyl-sulfoxide-compatible microcatheters like Magic 1.2 (Balt Extrusion) can be used for embolization. In our opinion, the type of embolic agent used for the fistula embolization is not of major importance, as long as it does not dissolve the plug and has a high ability to diffuse, as with EVOH or low-concentrated *n*-BCA.

For SAVFs embolized with the PCT using glue as a liquid embolic agent, no detachable-tip microcatheters were used. The retrieval of microcatheters in the segmental arteries was uneventful, without elongation of arteries and high retraction forces. Neither excessive force nor rupture of the microcatheter tip occurred when retrieving the nondetachable microcatheters, despite the proximal plug of polymerized high-concentrated *n*-BCA. In our previous experience using the pressure cooker technique outside pial cerebral vessels, we noticed that retrieval of microcatheters was uneventful, such as in the meningeal or occipital arteries. We attribute the ease of retrieval to the combination of a short length of the plug and a straight course of the microcatheter. The Echelon microcatheter is braided but the Marathon is not, so ease of retrieval cannot be attributed to the braiding. On the contrary, a detachable-tip microcatheter should be used systematically for PCT in the pial branches. Indeed, the cerebral gyri are responsible for the tortuous course of the cerebral pial arteries. This course is straightened during the retraction of a microcatheter, even more so if its tip has been trapped by EVOH or *n*-BCA, potentially inducing bleeding from ruptured transmedullary arteries.

For SAVFs treated with EVOH, detachable-tip microcatheters were used to avoid trapping, because the EVOH was injected during a long time period, with a significant proximal reflux.

The main technical drawback for the use of the PCT in SAVFs is the need for 2 microcatheters. Because the segmental arteries are usually too narrow to allow cannulation with a regular 6F guiding catheter, which would allow 2 microcatheters, two 5F-guiding catheters are required for the PCT. Thus, after placement of the first microcatheter in the segmental artery, the guiding catheter has to be disengaged from the ostium for the second guiding catheter to be positioned at the origin of the segmental artery for navigation with the second microcatheter (Fig 1). The use of a Catch Mini stent retriever (Balt), compatible with a 0.017-inch microcatheter, was helpful to stabilize the first microcatheter and the first guiding catheter in some patients (Fig 3).

The use of a dual-lumen balloon may be an alternative to PCT for SAVF embolization.<sup>12</sup> It may help to overcome the limitation of using 2 guiding catheters. However, the dual-lumen balloons available on the market may be difficult to navigate in small and tortuous vessels, as can be the case with the segmental arteries. Smaller dual-lumen balloons with a low profile may help overcome this limitation.

### **Feasibility, Safety, and Effectiveness**

Embolization of SAVFs was feasible using the PCT in all cases; no technical failure was recorded. It was possible to navigate 2

microcatheters in all patients, including elderly patients up to 91 years of age. It was possible to fill the origin of the main draining vein in 14/15 patients (93.3%). Only 1 minor complication (6.6%) was recorded, consisting of a transient nerve root lesion, probably related to an ischemic mechanism. No major complication was recorded. Occlusion of the fistula was observed in all cases (15/15) at the end of the procedure.

At angiographic follow-up (available in 12/15 patients, 80%; average time interval, 6.7 [SD, 7.6] months), a persistent complete occlusion was found in 11/12 (91.7%) patients. A recurrence occurred only in the patient with an epidural SAVF in whom the embolic agent did not completely reach the vein.

The filling of the origin of the draining vein with embolic agent seems, therefore, to be the main criterion to assess an endovascular cure.

The avoidance of reflux, as achieved with the PCT, allows an increased diffusion of the embolic agent. The ability to see the opening of anastomoses is reduced by respiratory artifacts, which alter the quality of the blank roadmap used during injection. Therefore, additional precautions, such as for prolonged apnea, may be taken during injection. This is especially important in case of a spinal artery arising from the contralateral segmental artery or from a segmental artery 1 level below or above the SAVF. In these situations, migration of embolic agent toward a radiculomedullary artery may occur because retrocorporeal or intersegmental anastomoses are always present.<sup>13</sup> To prevent such uncontrolled embolic agent migration, preventive selective coiling of these anastomoses may be performed before liquid embolic agent injection.

### Limitations of the Study

The main limitations of our study are the retrospective design and the limited number of patients and centers included. Additionally, comparison with the standard therapy (ie, microsurgery) for the curative treatment of SVMs is lacking. Moreover, the SVMs treated in our series were heterogeneous, including both dural and epidural AVFs. Techniques used were also slightly heterogeneous because in some patients, the liquid embolic agent used was diluted *n*-BCA and in others, EVOH. Moreover, angiographic follow-up missing in 20% of the patients is another limitation of our study.

### CONCLUSIONS

The PCT to treat spinal arteriovenous fistulas, either with glue or EVOH, may improve the rate of complete endovascular cure. A prospective head-to-head comparison with microsurgery appears warranted.

### ACKNOWLEDGMENT

The authors kindly thank Mme Bénédicte Ibert-Clarençon for her help in the editing the drawings.

Disclosures: Frédéric Clarençon—UNRELATED: Board Membership: Arterdrone; Grants/Grants Pending: Assistance Publique-Hôpitaux de Paris, Comments: national grant for the Emprotect trial\*; Payment for Lectures Including Service on Speakers Bureaus: Medtronic, Guerbet, Balt Extrusion, Penumbra. Christian P. Stracke—UNRELATED: Consultancy: Acandis, Comments: consultancy agreement; Expert Testimony: Balt; Payment for Lectures Including Service on Speakers Bureaus: MicroVention, Rapid Medical. Nader Sourour—RELATED: Consulting Fee or Honorarium: Medtronic, Balt. Rene Chapot—UNRELATED: Payment for Lectures Including Service on Speakers Bureaus: Balt, Medtronic, MicroVention, Siemens, Stryker; Travel/Accommodations/Meeting Expenses Unrelated to Activities Listed: Stryker, Balt, Siemens. \*Money paid to the Institution.

### REFERENCES

1. Krings T, Geibprasert S. **Spinal dural arteriovenous fistulas**. *AJNR Am J Neuroradiol* 2009;30:639–48 [CrossRef Medline](#)
2. Lenck S, Nicholson P, Tymianski R, et al. **Spinal and paraspinal arteriovenous lesions**. *Stroke* 2019;50:2259–69 [CrossRef Medline](#)
3. Donghai W, Ning Y, Peng Z, et al. **The diagnosis of spinal dural arteriovenous fistulas**. *Spine (Phila Pa 1976)* 2013;38:E546–53 [CrossRef Medline](#)
4. Bakker NA, Uyttenboogaart M, Luijckx GJ, et al. **Recurrence rates after surgical or endovascular treatment of spinal dural arteriovenous fistulas: a meta-analysis**. *Neurosurgery* 2015;77:137–44; discussion 44 [CrossRef Medline](#)
5. Chapot R, Stracke P, Velasco A, et al. **The pressure cooker technique for the treatment of brain AVMs**. *J Neuroradiol* 2014;41:87–91 [CrossRef Medline](#)
6. Aminoff MJ, Logue V. **Clinical features of spinal vascular malformations**. *Brain* 1974;97:197–210 [CrossRef Medline](#)
7. Filippidis DK, Binkert C, Pellerin O, et al. **Cirse Quality Assurance Document and Standards for Classification of Complications: the Cirse Classification System**. *Cardiovasc Intervent Radiol* 2017;40:1141–46 [CrossRef Medline](#)
8. Bretonnier M, Henaux PL, Gaberel T, et al. **Spinal dural arteriovenous fistulas: clinical outcome after surgery versus embolization: a retrospective study**. *World Neurosurg* 2019;127:e943–49 [CrossRef Medline](#)
9. Goyal A, Cesare J, Lu VM, et al. **Outcomes following surgical versus endovascular treatment of spinal dural arteriovenous fistula: a systematic review and meta-analysis**. *J Neurol Neurosurg Psychiatry* 2019;90:1139–46 [CrossRef Medline](#)
10. Houdart E. **The debate on the technique of treatment of spinal dural AVFs: Almost all must be treated by surgery**. In: *Proceedings of the Annual Meeting of the World Federation of Interventional and Therapeutic Neuroradiology Congress*, Naples, Italy. October 21–24, 2019
11. Chapot R, Stracke P. **Use of the pressure cooker technique in a spinal dural fistula: case report**. In: *Proceedings of the Annual Meeting of ABC WIN: Anatomy-Biology-Clinical correlations-Working group in Interventional Neuroradiology*, Val d'Isère, France. January 18–23, 2015
12. Nakae R, Nagaishi M, Hyodo A, et al. **Embolization of a spinal dural arteriovenous fistula with ethylene-vinyl alcohol copolymer (Onyx) using a dual-lumen microballoon catheter and buddy wire technique**. *Surg Neurol Int* 2017;8:166 [CrossRef Medline](#)
13. Lasjaunias P, Berenstein A, Ter Brugge K. **Spinal and spinal cord arteries and veins**. In: *Clinical Vascular Anatomy and Variations*. Springer-Verlag; 2001; 89–92