



Discover Generics

Cost-Effective CT & MRI Contrast Agents



FRESENIUS
KABI

WATCH VIDEO

AJNR

Coil Embolization Versus Clipping for Ruptured Intracranial Aneurysms: A Meta-Analysis of Prospective Controlled Published Studies

G. Lanzino, M.H. Murad, P.I. d'Urso and A.A. Rabinstein

This information is current as of June 27, 2025.

AJNR Am J Neuroradiol published online 11 April 2013
<http://www.ajnr.org/content/early/2013/04/11/ajnr.A3515>

Coil Embolization Versus Clipping for Ruptured Intracranial Aneurysms: A Meta-Analysis of Prospective Controlled Published Studies

G. Lanzino, M.H. Murad, P.I. d'Urso, and A.A. Rabinstein



ABSTRACT

BACKGROUND AND PURPOSE: Coil embolization is an alternative to clipping for intracranial aneurysms. However, controversy exists regarding the best therapeutic strategy in patients with ruptured aneurysms, and there is great center- and country-related variability in the rates of clipping versus coiling. We performed a meta-analysis of prospective controlled trials of clipping versus coil embolization for ruptured aneurysms.

MATERIALS AND METHODS: We performed a search of the English literature for published prospective controlled trials comparing surgical clipping with endovascular coil embolization for ruptured intracranial aneurysms. Data were abstracted from the identified references. Outcomes of interest were the proportion of patients with a poor outcome at 1 year and episodes of rebleeding from the index treated aneurysm after the allocated treatment.

RESULTS: There were 3 prospective controlled trials eligible for inclusion. These studies enrolled 2723 patients. Meta-analysis of these studies showed that the rate of poor outcome at 1 year was significantly lower in patients allocated to coil embolization (risk ratio, 0.75; 95% confidence interval, 0.65–0.87). This relative effect is consistent with an absolute risk reduction of 7.8% and a number needed to treat of 13. The effect on mortality was not statistically different across the 2 treatments. Rebleeding rates within the first month were higher in patients allocated to endovascular coil embolization.

CONCLUSIONS: On the basis of the analysis of the 3 high-quality prospective controlled trials available, there is strong evidence to indicate that endovascular coil embolization is associated with better outcomes compared with surgical clipping in patients amenable to either therapeutic strategy.

ABBREVIATIONS: RCT = randomized clinical trials; GDC = Guglielmi detachable coil; GOS = Glasgow Outcome Scale; ISAT = International Subarachnoid Aneurysm Trial; BRAT = Barrow Ruptured Aneurysm Trial

Rebleeding from a ruptured aneurysm is a deadly complication. Early treatment of the ruptured aneurysm has been proved to reduce the risk of early rebleeding¹ and has been the standard strategy for the treatment of patients with subarachnoid hemorrhage over the past 3 decades.² With the development of neuroendovascular techniques, endovascular coil embolization has become a valid and increasingly used alternative to surgical clip obliteration in patients with ruptured intracranial aneu-

rysms.³ However, the best therapeutic approach in a patient with a ruptured aneurysm continues to be debated, and rates of clipping versus coiling vary greatly across countries and single centers.

Since the approval by the FDA of the GDC in 1995, endovascular coil embolization has been compared with surgical clip occlusion in high-quality prospective controlled studies.^{4–7} We performed a meta-analysis of published prospective controlled studies to evaluate the comparative efficacy of both treatment modalities.

MATERIALS AND METHODS

We searched Medline, Embase, and the Cochrane Library for randomized trials and prospective controlled studies comparing surgical clipping and endovascular coil embolization for ruptured intracranial aneurysms. The electronic databases were searched by use of the OVID interface for trials on human subjects published in English between 2004–2011. A high-quality systematic

Received July 12, 2012; accepted after revision December 27.

From the Department of Neurosurgery (G.L.), Department of Preventive Medicine (M.H.M.), and Department of Neurology (A.A.R.), Mayo Clinic, Rochester, Minnesota; and Department of Neurosurgery (P.I.d'U.), King's College Hospital, London, United Kingdom.

Please address correspondence to Giuseppe Lanzino, Department of Neurosurgery, Mayo Clinic, 200 First St SW, Rochester, MN 55905; e-mail: lanzino.giuseppe@mayo.edu

Evidence-Based Medicine Level 1.

<http://dx.doi.org/10.3174/ajnr.A3515>

Table 1: Summary of published randomized clinical trials of surgery versus coiling for ruptured aneurysms

	Kuopio	ISAT	BRAT
Period	February 1995 to August 1997	1997 to September 2002	March 2003 to January 2007
Single-center/multicenter	Single	Multicenter	Single
Enrollment	<72 hours	<28 days	<14 days
Total patients screened	242	9559	725
Patients enrolled	109	2143	471
Mean age (years)			
Endovascular	49	52	54
Surgery	50	52	53
No. of patients allocated endovascular	52	1073	233
No. of patients allocated surgery	57	1070	238
Good grade, <i>n</i> (% of total)	93 (85.3)	2018 (94.2)	380 (80.7)
Poor grade, <i>n</i> (% of total)	16 (13.7)	94 (5.8)	91 (19.3)
Crossovers			
From endovascular to surgery	12	9	75
From surgery to endovascular	4	38	4

review previously published provided references before 2004.⁸ Only studies in which patients had been either randomly assigned or prospectively alternatively allocated to surgery and to endovascular treatment were considered. Noncontrolled or retrospective studies comparing clinical results with surgical clipping or endovascular coiling and studies evaluating the effect of drugs or other therapeutic procedures on surgical or endovascular patients were excluded. The key words used, singly or in combination, included aneurysmal subarachnoid hemorrhage, cerebral aneurysm, cerebral aneurysms, clip/clips, coil/coils, clipping, coiling, endovascular, coil embolization, embolization, endovascular coil embolization, endovascular treatment, intracranial aneurysm, intracranial aneurysms, neurosurgical clipping, ruptured aneurysm, ruptured aneurysms, ruptured intracranial aneurysm, ruptured intracranial aneurysms, subarachnoid hemorrhage, and subarachnoid haemorrhage.

One hundred five potentially relevant references were identified on the basis of their titles; 88 were excluded after screening the abstract, and an additional 16 were excluded after reading the full text. The search yielded 1 new prospective controlled study with alternate prospective allocation since 2004.⁷ Eventually, 3 studies were included in the present analysis.

The primary outcome of interest was the percentage of patients with poor outcome at 1 year. The secondary outcome was rebleeding in the first year after treatment.

Data Collection

With the use of a standardized collection data form, data were extracted from all of the eligible trials. These data included:

Descriptive Data. Interval period during which the study was conducted, maximum time allowed from the index SAH, number of patients screened, study size, number of patients in each arm, patient mean age, and completeness of follow-up at 1 year.

Methodologic Data. Single-center or multicenter study, method for outcome assessment at 1 year, and definition of poor outcome.

Outcome Data. Proportion of patients with a poor outcome at 1 year and episodes of rebleeding from the index treated aneurysm during the first year after treatment.

Statistical Analysis. Random effects model was used to pool relative risks (risk ratios) and 95% confidence intervals across studies.⁹ Heterogeneity was evaluated by using the I^2 statistic.¹⁰

RESULTS

Three prospective controlled studies were eligible for inclusion in this analysis. Table 1 summarizes the main study characteristics, methodology, and enrollment. These studies enrolled 2723 patients. Only patients with aneurysms amenable to either surgical or endovascular treatment were enrolled in 2 of the trials,^{4,6} whereas in the remaining trial, all consecutive patients with SAH (including nonaneurysmal SAH) who

agreed to participate in the study were randomly assigned to 1 of the 2 treatment modalities in an alternating fashion.⁷ Functional outcome at 1 year was reported in the 3 studies.

This was performed by use of the GOS (poor outcome defined by GOS 1–3) rated by 1 of the investigators in 1 study^{4,5}; by use of modified Rankin Scale (poor outcome defined by modified Rankin Scale score 3–6) assessed by the patients in a mailed questionnaire (or a caretaker if the patient was unable to complete it) in 1 study⁶; and by use of modified Rankin Scale rated by a research nurse in 1 study.⁷ Methods of assessment of outcome at 1 year, rates of poor outcome according to treatment allocation, and episodes of rebleeding are summarized in Table 2.

Meta-analysis of these studies showed that the rate of poor outcome at 1 year was significantly lower in patients allocated to coil embolization (risk ratio, 0.75; 95% confidence interval, 0.65–0.87) (Fig 1). This difference represents an absolute risk reduction of 7.8% and translates into a number needed to treat of 13 (ie, 13 patients treated by coiling to prevent poor outcome in 1 patient). The effect on mortality was not statistically different across the 2 treatments. Rebleeding rates within the first month were higher in patients allocated to endovascular coil embolization, but the difference was not significant at 1 year (Fig 2). Heterogeneity across studies was minimal (<25%).

DISCUSSION

Since the introduction of GDCs into clinical practice in 1992, 2 randomized trials and 1 prospective controlled clinical trial have been published comparing functional outcome at 1 year after coil embolization versus surgical clip ligation for ruptured intracranial aneurysms. Our meta-analysis of these published trials shows that the odds of poor outcome are higher after surgical treatment than after endovascular treatment, despite a higher early risk of rebleeding from the target aneurysm after coil embolization. Furthermore, subgroup analyses from these clinical trials have indicated that the risks of seizures,¹¹ delayed cerebral ischemia,¹² ischemic lesions on MR imaging,¹³ and in-hospital complications¹⁴ are lower after coil embolization than after surgical clip ligation. A subgroup analysis of patients enrolled in the ISAT also showed improved cognitive outcome after coiling compared with surgery.¹⁵ These observations provide convincing evidence that endovascular coil embolization should be

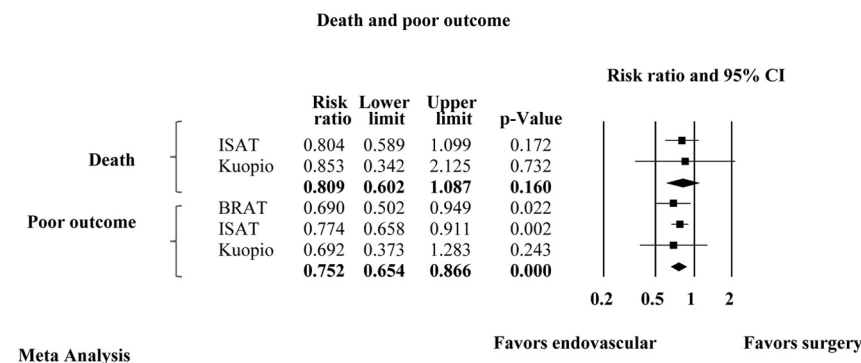
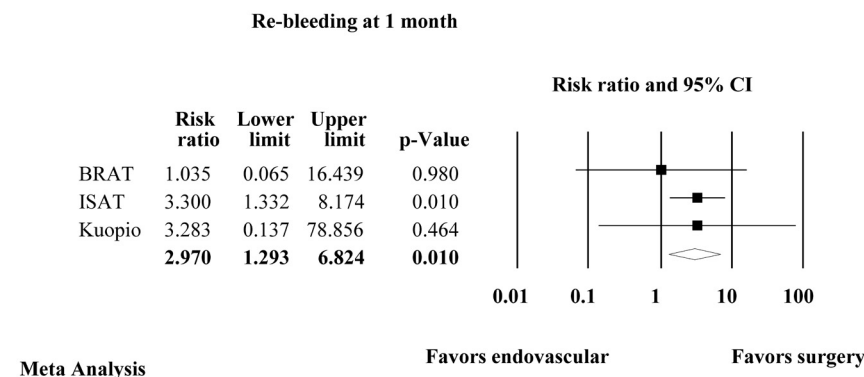
Table 2: Clinical outcome at 1 year (intent-to-treat analysis)

	Kuopio	ISAT	BRAT
Outcome assessment 1 year	Single neurosurgeon	Postal questionnaire filled out by patients	Research nurse
Definition poor outcome	GOS	mRS 3–6	mRS 3–6
Poor outcome			
Endovascular	12/52 (23%)	250/1063 (23.5%)	46/198 (23%)
Surgery	19/57 (33%)	326/1055 (30.9%)	69/205 (34%)
Death			
Endovascular	7/52 (13%)	85/1063 (8.0%)	NA
Surgery	9/57 (16%)	105/1055 (9.9%)	NA
Rebleeding			
Endovascular			
Day 1–30	1	20	1 ^a
Day 31–365	0	6	0
>1 year	0	10	0
Surgery			
Day 1–30	0	6	1
Day 31–365	0	4	0
>1 year	0	3*	0
One-year follow-up complete			
Endovascular	100% ^b	1063/1073 (99%)	198/233 (85%)
Surgery		1055/1070 (98.6%)	205/238 (86%)

Note:—mRS indicates modified Rankin scale; NA, not available.

^a Intent-to-treat analysis;

^b 2 patients excluded after random assignment.

**FIG 1.** Meta-analysis of death and rate of poor functional outcome at 1 year.**FIG 2.** Meta-analysis of rebleeding from the treated aneurysm during the first month after treatment.

strongly considered as the preferred treatment technique for a ruptured aneurysm amenable to either therapeutic technique (surgery or endovascular coiling).

The “Kuopio” study was the first of the 3 published prospective controlled studies of coil embolization versus clip ligation for

ruptured intracranial aneurysms.^{4,5} This trial was a single-center study conducted in Kuopio, Finland, between 1995–1997 shortly after the introduction of endovascular treatment in that center. The study enrolled patients with aneurysms amenable to either surgical or endovascular treatment; patients requiring urgent hematoma evacuation or with a geometry not amenable to coil embolization were excluded.⁵ Overall, 109 patients were randomly assigned to surgery (57 patients) or endovascular treatment (52 patients).^{4,5} Primary clinical outcome at 1 year (measured by the GOS) was not significantly different between the 2 groups (intent-to-treat analysis), though there was a trend toward a lower rate of poor outcome in patients undergoing endovascular treatment (23% versus 33% in those allocated to surgery).⁵ There was 1 episode of early rebleeding after incomplete coil embolization, but no episodes of rebleeding were observed after discharge during a mean follow-up of >4 years.⁵

ISAT was a large, multicenter, randomized trial to assess the effectiveness of coil embolization compared with surgical clip ligation. The study was conducted between 1997–2002, and it was halted prematurely after enrollment of 2143 patients because of a significant outcome difference between the 2 groups favoring endovascular coil embolization.⁶ In ISAT, the proportion of patients with a poor outcome at 1 year (defined as a modified Rankin Scale score of >2) was 23.5% among patients assigned to coil embolization versus 30.9% in those allocated to clip ligation ($P = .0019$). Intrinsic to the ISAT study was the concept of “equipoise”: to be enrolled into the trial, the ruptured aneurysm had to be judged amenable to either surgical or endovascular treatment by specialists in the 2 disciplines. Therefore, of more than 9000 patients screened at the participating centers during the interval of the study, only 2143 were eventually enrolled in the trial. As a result of the selection criteria,

most patients in ISAT were patients in good clinical grade (94% World Federation of Neurosurgical Societies grades 1–3) with small anterior circulation aneurysms (>90%). The high representation of patients with good grade aneurysmal SAH and anterior circulation aneurysms in ISAT may have been the result of pa-

tients with poor grade SAH and posterior circulation aneurysms being treated preferentially by coil embolization in ISAT centers.

Publication of the results of ISAT changed practice patterns for the treatment of ruptured aneurysms. However, several questions remained unanswered. Given the relatively high number of screened patients who were not considered candidates to participate in ISAT, some questioned the applicability of the ISAT results to patients with aneurysmal SAH at large. Moreover, questions were raised whether the ISAT results could apply to North American centers, where a supposedly higher degree of subspecialization exists among cerebrovascular surgeons dedicated to the care of patients with ruptured intracranial aneurysms.

In response to these concerns, investigators at the Barrow Neurological Institute in Phoenix, Arizona, launched BRAT in 2002.⁷ To assess results in a “real-world” situation, the BRAT investigators randomly assigned in an alternate fashion every patient with SAH admitted to their center during the period of the study who agreed to participate. As a consequence of this design, many patients with nonaneurysmal SAH were entered in the trial. Similarly, a large number of patients allocated to endovascular treatment crossed over to surgical treatment because patients could be enrolled regardless of whether the aneurysm was amenable to both treatment modalities. As a consequence, aneurysms that could not safely be treated with coiling because of technical reasons (ie, very small aneurysms) or clinical considerations (ie, aneurysms associated with intraparenchymal hematomas necessitating surgical evacuation) were originally assigned to embolization. Despite this high rate of crossover, the BRAT study confirmed the ISAT conclusions: outcomes at 1 year were better after coil embolization than after surgical clipping. The proportion of patients with a poor outcome (defined by modified Rankin Scale score >2) was 33.7% in the surgical group versus 23.2% ($P = .02$, intention-to-treat analysis) in the endovascular group. As-treated analysis yielded similar results, with 33.9% of patients in the surgical group and 20.4% in the endovascular group with a poor outcome at 1 year ($P = .01$).

Endovascular coil embolization of ruptured intracranial aneurysms is associated with better outcomes, but the risk of aneurysm recurrence, the need for retreatment, and the risk of rebleeding from the index aneurysm are higher after coil embolization.^{6,7,16} Among patients enrolled in ISAT, 17.4% of those undergoing endovascular treatment required re-treatment because of recurrence/residual aneurysm.¹⁶ Likewise, the risk of rebleeding was higher after endovascular coil embolization. Rates of rebleeding were 3.0% during the first year⁶ and 0.3% per year between post-treatment years 2 and 6, with no episodes of rebleeding after year 6.¹⁷ Despite the higher risk of rebleeding, the initial beneficial effect on functional outcome remained present up to 7 years after treatment,¹⁷ except in the subgroup of very young patients (<40 years).¹⁸

It is possible that the clinical results from endovascular treatment and the degree of long-term protection afforded by coil embolization have improved over the last decade, (ie, since the completion of ISAT) because of increasing operator experience and development of better devices. This argument is supported by the fact that there were no episodes of rebleeding reported in BRAT for up to 2 years after endovascular therapy.⁷ Similarly,

results of prospective studies comparing different coil designs have recently reported better outcomes after coil embolization than those reported in ISAT.¹⁹

Although this meta-analysis of the 3 published randomized clinical trials unequivocally indicates that outcomes at 1 year are better with endovascular treatment, there continue to be patients who are better candidates for surgical clip ligation. Very small aneurysms are often challenging to treat with an endovascular approach.²⁰ Similarly, many middle cerebral artery aneurysms have an unfavorable geometry for primary coiling, and they are often better treated with surgical clipping.²¹ Moreover, very young patients with ruptured anterior circulation aneurysms (especially those who may be noncompliant with follow-up imaging) may also be better candidates for surgical treatment rather than endovascular coil embolization.¹⁸ Despite the evidence from randomized clinical trials, the decision on what is the best treatment for a ruptured aneurysm in a given patient should be individualized by taking into consideration aneurysm-related and patient-specific factors.^{21,22}

We acknowledge that our meta-analysis has limitations. The methodologic quality of the trials included was variable. Only ISAT fulfilled all the criteria of a high-quality randomized controlled trial. Entry criteria and outcome assessment differed across studies. Yet, the finding that all trials produced consistent results favoring the endovascular arm reassures us that these methodologic differences do not negate the validity of the meta-analysis.

CONCLUSIONS

This meta-analysis of published prospective controlled trials of surgical clipping versus endovascular coil embolization for patients with ruptured intracranial aneurysms provides convincing evidence that functional outcome at 1 year is better after endovascular treatment despite a higher risk of rebleeding from the index aneurysm after coil embolization. Hence, when technically feasible, endovascular coil embolization should be the preferred technique for the treatment of ruptured intracranial aneurysms.

Disclosures: Giuseppe Lanzino—UNRELATED: Consultancy: ev3/Covidien; * Expert Testimony: ev3/Covidien; * Grants/Grants Pending: ev3/Covidien, Synthes. Alejandro Rabinstein—UNRELATED: Consultancy: Boehringer Ingelheim, Comments: Participation in a single Advisory Board Meeting; Grants/Grants Pending: CardioNet; * Royalties: Elsevier, Oxford, Comments: For authored books (*Money paid to institution).

REFERENCES

1. Haley EC Jr, Kassell NF, Torner JC. **The International Cooperative Study on the Timing of Aneurysm Surgery: the North American experience.** *Stroke* 1992;23:205–14
2. Rabinstein AA, Lanzino G, Wijdicks EF. **Multidisciplinary management and emerging therapeutic strategies in aneurysmal subarachnoid haemorrhage.** *Lancet Neurol* 2010;9:504–19
3. Leake CB, Brinjikji W, Kallmes DF, et al. **Increasing treatment of ruptured cerebral aneurysms at high-volume centers in the United States.** *J Neurosurg* 2011;115:1179–83
4. Vanninen R, Koivisto T, Saari T, et al. **Ruptured intracranial aneurysms: acute endovascular treatment with electrolytically detachable coils—a prospective randomized study.** *Radiology* 1999;211:325–36
5. Koivisto T, Vanninen R, Hurskainen H, et al. **Outcomes of early endovascular versus surgical treatment of ruptured cerebral**

- aneurysms: a prospective randomized study. *Stroke* 2000;31:2369–77
6. Molyneux A, Kerr R, Stratton I, et al. **International Subarachnoid Aneurysm Trial (ISAT) of neurosurgical clipping versus endovascular coiling in 2143 patients with ruptured intracranial aneurysms: a randomised trial.** *Lancet* 2002;360:1267–74
 7. McDougall CG, Spetzler RF, Zabramski JM, et al. **The Barrow Ruptured Aneurysm Trial.** *J Neurosurg* 2012;116:135–44
 8. van der Schaaf I, Algra A, Wermer M, et al. **Endovascular coiling versus neurosurgical clipping for patients with aneurysmal subarachnoid haemorrhage.** *Cochrane Database Syst Rev* 2005; CD003085
 9. DerSimonian R, Laird N. **Meta-analysis in clinical trials.** *Control Clin Trials* 1986;7:177–88
 10. Higgins JP, Thompson SG, Deeks JJ, et al. **Measuring inconsistency in meta-analyses.** *BMJ* 2003;327:557–60
 11. Molyneux AJ, Kerr RS, Yu LM, et al. **International Subarachnoid Aneurysm Trial (ISAT) of neurosurgical clipping versus endovascular coiling in 2143 patients with ruptured intracranial aneurysms: a randomised comparison of effects on survival, dependency, seizures, rebleeding, subgroups, and aneurysm occlusion.** *Lancet* 2005;366:809–17
 12. Dorhout Mees SM, Kerr RS, Rinkel GJ, et al. **Occurrence and impact of delayed cerebral ischemia after coiling and after clipping in the International Subarachnoid Aneurysm Trial (ISAT).** *J Neurol* 2011;259:679–83
 13. Bendel P, Koivisto T, Kononen M, et al. **MR imaging of the brain 1 year after aneurysmal subarachnoid hemorrhage: randomized study comparing surgical with endovascular treatment.** *Radiology* 2008;246:543–52
 14. Vergouwen MD, Fang J, Casaubon LK, et al. **Higher incidence of in-hospital complications in patients with clipped versus coiled ruptured intracranial aneurysms.** *Stroke* 2011;42:3093–98
 15. Scott RB, Eccles F, Molyneux AJ, et al. **Improved cognitive outcomes with endovascular coiling of ruptured intracranial aneurysms: neuropsychological outcomes from the International Subarachnoid Aneurysm Trial (ISAT).** *Stroke* 2010;41:1743–47
 16. Campi A, Ramzi N, Molyneux AJ, et al. **Retreatment of ruptured cerebral aneurysms in patients randomized by coiling or clipping in the International Subarachnoid Aneurysm Trial (ISAT).** *Stroke* 2007;38:1538–44
 17. Molyneux AJ, Kerr RS, Birks J, et al. **Risk of recurrent subarachnoid haemorrhage, death, or dependence and standardised mortality ratios after clipping or coiling of an intracranial aneurysm in the International Subarachnoid Aneurysm Trial (ISAT): long-term follow-up.** *Lancet Neurol* 2009;8:427–33
 18. Mitchell P, Kerr R, Mendelow AD, et al. **Could late rebleeding overturn the superiority of cranial aneurysm coil embolization over clip ligation seen in the International Subarachnoid Aneurysm Trial?** *J Neurosurg* 2008;108:437–42
 19. Coley S, Sneade M, Clarke A, et al. **Cerecyte Coil Trial: procedural safety and clinical outcomes in patients with ruptured and unruptured intracranial aneurysms.** *AJNR Am J Neuroradiol* 2012;33:474–80
 20. Brinjikji W, Lanzino G, Cloft HJ, et al. **Endovascular treatment of very small (3 mm or smaller) intracranial aneurysms: report of a consecutive series and a meta-analysis.** *Stroke* 2010;41:116–21
 21. Lanzino G, Fraser K, Kanaan Y, et al. **Treatment of ruptured intracranial aneurysms since the International Subarachnoid Aneurysm Trial: practice utilizing clip ligation and coil embolization as individual or complementary therapies.** *J Neurosurg* 2006;104:344–49
 22. Lanzino G. **The Barrow Ruptured Aneurysm Trial.** *J Neurosurg* 2012;116:133–34