



Providing Choice & Value

Generic CT and MRI Contrast Agents



CONTACT REP

AJNR

Overlying Fluoroscopy and Preacquired CT Angiography for Road-Mapping in Cerebral Angiography

C.-J. Lin, R. Blanc, F. Clarençon, M. Pötter, L. Spelle, J. Guillemin and J. Moret

This information is current as of July 23, 2025.

AJNR Am J Neuroradiol published online 15 October 2009
<http://www.ajnr.org/content/early/2009/10/15/ajnr.A1757.citation>

Overlying Fluoroscopy and Preacquired CT Angiography for Road-Mapping in Cerebral Angiography

TECHNICAL NOTE

C.-J. Lin
R. Blanc
F. Clarençon
M. Piotin
L. Spelle
J. Guillermic
J. Moret

SUMMARY: We describe our preliminary experience using a road-mapping procedure that involves combining preacquired CTA with real-time fluoroscopy. This maneuver facilitates navigation in supra-aortic vessels from the arch to skull base levels. It requires less contrast than is used for traditional road-mapping while potentially reducing the hazard of thromboembolic events associated with direct catheterization. The accuracy of registration between the 2 volume datasets seems satisfactory for clinical practice.

ABBREVIATIONS: AP = anteroposterior; CTA = CT angiography; 3DRA = 3D rotation angiography; MIP = maximum intensity projection.

Traditional road-mapping, involving the superimposition of digital subtraction of the contrast-filled vessel lumen on fluoroscopy, provides good spatial resolution and contrast for real-time images. It also lowers the risk of inadvertent events when compared with the direct catheterization of vessels, in which the manipulation of wires and catheters distally sometimes causes vasospasm, dissection, and dislodgement of plaques because of an uncertain spatial relationship between the devices and the vessel walls.

However, an inherent limitation of traditional subtraction road-mapping is its static projection. Different projections are usually mandatory for a better delineation of tortuous vessels in neuroradiologic angiograms, and this typically requires extra contrast administration for a new roadmap with different working projections.

The introduction of dynamic 3D road-mapping offers a way to avoid the problems associated with both of the above procedures. In this method, road-mapping is generated through fusion of a preacquired volume of the arterial tree (isotropic CTA) and a noninjected 3DRA generated by the 3D workstation (XtraVision Rel 6; Philips Healthcare, Best, the Netherlands).¹ Images can be adjusted to different angles by altering the C-arm position to provide multiple working projections.²

Technique and Comprehensive Cases

Three patients who were suspected of having intracranial arterial diseases based on previous explorations with aortic CTA were referred to our department for diagnostic angiography. We used a C-arm angiographic unit (Allura Xper FD20; Philips Healthcare) connected to a 3D workstation (XtraVision Rel 6; Philips Healthcare) to create a dynamic roadmap. The volume datasets of isotropic CTA axial images were loaded into the workstation before the beginning of the examination. The patient was assisted into a supine position in the

angiography suite, and his head was fixed in a neutral position by using a headset. The isocenter was defined at the anterior border of the T1 vertebral body, to diminish the motion artifacts in the resulting roadmap. A propeller movement of the C-arm, covering a 240° circular trajectory, was performed without contrast injection. A series of 120 images in total were exposed at a rate of 30 frames per second. This primary dataset was automatically transferred to the workstation; the reconstruction of the noninjected volume was displayed in the workstation 10 seconds after the acquisition was complete. We superimposed the primary volume dataset (3D volume of rotation angiography, without contrast injection, integrated with real-time fluoroscopy) on the secondary volume dataset (CTA axial images).

Fusion of vascular and anatomic volume datasets can be performed either by manual or automatic methods. The automatic method registers 2 datasets by using a rigid transformation and mutual information as similarity measures. When used with cerebral applications, the software uses rigid registration instead of elastic transformations (ie, only global translation and rotation). With rigid registration, the software determines the transformation of the CT volume dataset to the coordinate space of the detector. The rotation of the CT volume dataset corresponds to the inverse of the original matrix, which will be equal to its transpose, because rotation matrices are orthogonal. The software then uses calibration data to compensate for deviations from the ideally calculated orientation of fluoroscopy.³ Mutual information works very well between intermodality registrations and does not require prior knowledge of the datasets. With the manual method, the operator needs to move the secondary volume dataset to match the primary volume dataset in the axial, coronal, and sagittal planes. This 3D volume spontaneously matches live fluoroscopy and dynamic acquisitions according to daily calibration and can thus follow the position of the C-arm. Because, by default, the primary volume (3DRA) is set undisplayed, the final imaging displayed in the workstation is a hybrid of real-time fluoroscopy and CTA.

High Hounsfield unit objects, such as the sternum, cervical spine, and carotid arteries, can serve as landmarks. Blending and opacity options for both 3D volume datasets can be manually adjusted directly at bedside according to the visual preferences of the operator. CTA volume superimposed on the live fluoroscopy and dynamic sequences can be handled either with volume-rendered options or sections, with visualization limited to a 10-mm thickness. Navigation of the medical devices can start as soon as the registrations between the 3D volumes have been performed (Fig 1). During the navigation, we mostly defined our working projections around the AP position; the

Received April 25, 2009; accepted after revision May 22.

From the Department of Functional and Interventional Neuroradiology (C.-J.L., R.B., F.C., M.P., L.S., J.M.), Fondation Rothschild Hospital, Paris, France; University of Paris (R.B., F.C., M.P., L.S., J.M.), Bichat School of Medicine, Paris, France; Department of Medical Imaging (C.-J.L.), Far Eastern Memorial Hospital, Pan-Chiao City, Taiwan, ROC; National Yang Ming University School of Medicine (C.-J.L.), Taipei, Taiwan, ROC; and Philips Healthcare (J.G.) Cardio/Vascular Innovation, Best, the Netherlands.

Please address correspondence to Raphaël Blanc, MD, Department of Functional and Interventional Neuroradiology, Fondation Rothschild Hospital, 25–29 rue Manin, 75940 Paris, Cedex 19, France; e-mail: rblanc@fo-rothschild.fr

DOI 10.3174/ajnr.A1757

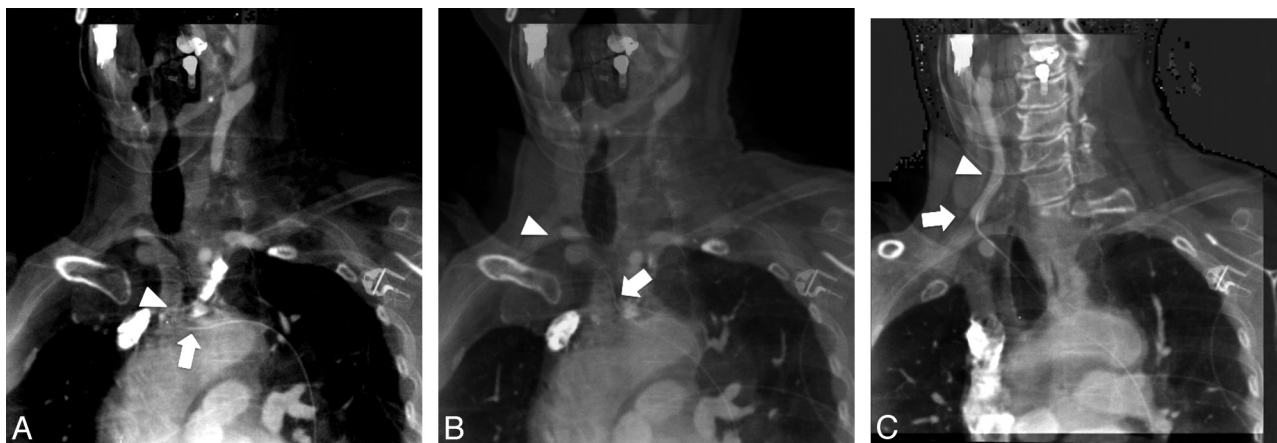


Fig 1. A 68-year-old woman was referred for diagnostic angiography of an aneurysm in the cavernous portion of the internal carotid artery. **A**, AP view of real-time fluoroscopy with superimposition of an MIP of a previously acquired CTA. A 5F Bern catheter (Boston Scientific, Natick, Massachusetts) with a Terumo wire (Terumo Medical, Somerset, New Jersey) can be seen in the brachiocephalic trunk. **B**, The wire is shown in the proximal right common carotid artery. The superimposed MIP of the CTA does not correlate well with fluoroscopy due to the different depth of the aortic arch and the proximal common carotid artery in the AP projection. **C**, After manual adjustment of the depth of the MIP, the road-mapping of distal vasculature until bifurcation is available again for further navigation of the catheter. Arrows indicate the tip of the catheter, and the arrowheads indicate the tip of the wire.

orientation of the CTA volume dataset was synchronized with every C-arm movement. The AP projection was the most commonly used plane, because we sought to avoid difficult navigation into bifurcations from the brachiocephalic-carotid junctions to distal carotid artery bifurcations.

Discussion

Catheterization of the supra-aortic arch might be cumbersome in some patients because of vessel tortuosity.⁴ Moreover, these vessels are predisposed to atherosclerotic plaques, and intra-arterial navigation is associated with a high incidence of thromboembolic events.⁵ Use of 2D road-mapping can improve the navigation of wires more distally to support catheterization, but a large amount of contrast medium might be required to provide acceptable image quality in this region, which contains 3 major branches and thick soft tissues. Conventional 3DRA-based road-mapping (which would require a high-volume injection at the aortic arch) does not seem relevant in clinical routine. We, thus, chose to use coregistration of preacquired isotropic CTA without extra contrast loading, with the goal of enhancing catheterization possibilities during intervention.⁶

There are some drawbacks associated with our technique. First, as with conventional 3D road-mapping, immobility is prerequisite to avoid misalignment. Second, no stereotactic techniques were used for the fusion of CTA and fluoroscopy. However, this may not be an issue because imaging distortion essentially no longer exists with flat panel detectors. The rigid transformation used during automatic registration provides faster and more stable results but less tomographic accuracy compared with elastic transformation in the lower neck region. A new algorithm that balances the 2, or adds a novel maneuver such as motion compensation techniques,⁷ may make 3D road-mapping feasible for navigation in the neck and chest regions. Downgrading of the gray-scales of the volume datasets might reduce the noise and thus provide better blending imaging quality.

A final disadvantage is the necessity of manually adjusting the overlying secondary volumetric image by a cut plane position, or slide thickness. Without such an adjustment, the vasculature is obliterated by high Hounsfield unit structures

such as bones and teeth. Consequently, an additional clinician is required to operate the workstation while the operators navigate the devices. Another possibility worth considering would be to use the total volume of overlying CTA images with suppression of bone and soft tissue (equivalent to rotational angiography) to serve as a secondary volume, thus providing images of equivalent quality to those produced by traditional 3D road-mapping.

Although the resulting image is not yet delicate enough to clearly display intracranial vasculature, we believe that with strict immobilization and possibly with the use of stereotactic techniques, practitioners will be able to extend the application of overlying fluoroscopy and preacquired CT from neck to intracranial vessels.

Conclusions

Our preliminary experience with road-mapping by combining preacquired CTA isotropic datasets with fluoroscopy suggests that it is a feasible technique for navigation in areas ranging from the aortic arch level to the proximal internal carotid arteries. The accuracy of road-map registration is satisfactory for clinical practice. The potential to lower contrast media use and reduce the risk of thromboembolic events is clinically relevant. Improvements in registration and manipulation of angiographic volumes and live catheterization are prompted.

References

1. Kyriakou Y, Richter G, Dörfler A, et al. **Neuroradiologic applications with routine C-arm flat panel detector CT: evaluation of patient dose measurements.** *AJNR Am J Neuroradiol* 2008;29:1930–36. Epub 2008 Aug 7
2. Söderman M, Babic D, Homan R, et al. **3D roadmap in neuroangiography: technique and clinical interest.** *Neuroradiology* 2005;47:735–40
3. Ruijters D, Babic D, Homan R, et al. **3D multi-modality roadmapping in neuroangiography.** In: *Proceedings of SPIE Medical Imaging: Visualization and Image-Guided Procedures*, San Diego. February 3, 2007:65091F
4. Blanc R, Pötin M, Mounayer C, et al. **Direct cervical arterial access for intracranial endovascular treatment.** *Neuroradiology* 2006;48:925–29
5. Chuah KC, Stuckey SL, Berman IG. **Silent embolism in diagnostic cerebral angiography: detection with diffusion-weighted imaging.** *Australas Radiol* 2004;48:133–38
6. Rosovsky M, Rusinek H. **Dose-related nephrotoxicity.** *Radiology* 2006;240:614
7. Timinger H, Krueger S, Borgert J, et al. **Motion compensation for interventional navigation on 3D static roadmaps based on an affine model and gating.** *Phys Med Biol* 2004;49:719–32