



Providing Choice & Value

Generic CT and MRI Contrast Agents



**FRESENIUS
KABI**

CONTACT REP

AJNR

**Neuroimaging Clinics of North America:
Multiple Sclerosis, Part I: Background and
Conventional MRI, Vol. 18, No. 4 and Part II:
Nonconventional MRI Techniques, Vol. 19,
No. 1**

This information is current as
of July 28, 2025.

AJNR Am J Neuroradiol published online 2 April 2009
<http://www.ajnr.org/content/early/2009/04/02/ajnr.A1596.citation>

BOOK REVIEW

Neuroimaging Clinics of North America: Multiple Sclerosis, Part I: Background and Conventional MRI, Vol. 18, No. 4 and Part II: Nonconventional MRI Techniques, Vol. 19, No. 1

M. Filippi, guest ed. Philadelphia: W.B. Saunders; 2008, Part I: pages 563–719, 66 figures; Part II: pages 1–132, 46 figures.

The introduction of MR imaging to the evaluation of patients with multiple sclerosis (MS) has dramatically altered our understanding of the disease in recent decades, making it abundantly clear to researchers and clinicians that the pathogenesis of MS is much more complex than the simple plaque-centric theory, which previously dominated our thinking. Because of their improved sensitivity for detecting abnormalities in the brain and spinal cord over clinical assessment alone, conventional MR imaging techniques have become indispensable tools for initial diagnosis and follow-up of MS, both in daily practice and in clinical drug trials. Unfortunately, neither existing clinical criteria nor paraclinical tests (including MR imaging) used in MS have proved to be particularly reliable measures for predicting disability, disease progression, or response to disease-modifying agents on a patient-by-patient basis. However, newer MR imaging techniques, such as magnetization transfer (MT) imaging, susceptibility-weighted imaging (SWI), and diffusion tensor imaging (DTI), are now able to detect brain and spinal cord alterations not evident on conventional MR imaging sequences, which may ultimately translate into substantial improvements in our ability to diagnose MS and to monitor disease progression in the near future.

In the recent 2-part *Neuroimaging Clinics of North America* series, guest editor and renowned MS researcher, Dr. Massimo Filippi, presents 18 articles covering topics related to both conventional and nonconventional MR imaging of MS. From a quick overview of each table of contents, it becomes readily apparent that the articles contained within these 2 volumes are mainly intended for those with an inclination toward research—as is evidenced by several of the article titles, which include “MR Image Postprocessing for Multiple Sclerosis Research” and “The Use of MR Imaging as an Outcome Measure in Multiple Sclerosis Clinical Trials,” to name a few. However, several articles would be of interest to those who fall primarily on the clinical side of radiology. In particular, 2 standout articles in Part I covering conventional MR imaging and variants of MS provide excellent practical reviews of standard MR imaging techniques used for the diagnosis and follow-up of patients with MS (including an update on current diag-

nostic criteria) and of the clinical and imaging features of less commonly encountered variants of MS, such as Devic disease, Balo concentric sclerosis, and Schilder disease.

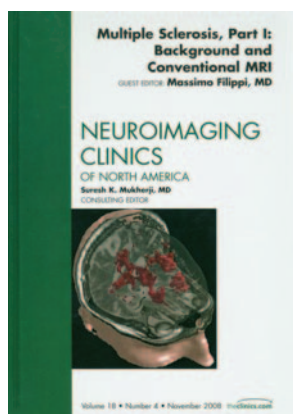

Three introductory chapters at the beginning of Part I cover the pathology, immunology, and epidemiology of MS. The first of these chapters, entitled “The Pathologic Substrate of Magnetic Resonance Alterations in Multiple

Sclerosis,” discusses how specific pathologic changes seen in MS translate into the typical abnormalities that we see (or in many cases do not see) with various conventional and nonconventional MR imaging techniques. Also included in the first volume is a chapter on the use of volumetric analysis techniques to measure brain atrophy in patients with MS.

One of the more curious inclusions in the series is the chapter entitled “Basic Principles of Magnetic Resonance Imaging,” which covers rudimentary MR imaging physics—including the principles behind spin-echo and gradient-echo imaging. Although the article is, in and of itself, well written and easy to read at a resident level, it fails even to mention MS, and its content seems a bit facile when juxtaposed against subsequent articles covering much more complex MR imaging techniques. I would expect that anyone even remotely interested in reading about DTI or MR relaxometry would already have a reasonably good understanding of basic pulse sequences.

Part II of the series, entitled “Nonconventional MRI Techniques,” covers a range of promising cutting-edge MR imaging techniques currently being used for MS research. In addition to articles reviewing the topics already listed above (MR relaxometry, MT MR, and DTI), this issue also contains reviews of the literature on the use of proton MR spectroscopy and functional MR imaging in MS research and articles dedicated specifically to optic nerve and spinal cord imaging in MS. The concluding chapters in the series are dedicated to discussions on high-field-strength MR imaging and the future of MS imaging, including sections devoted to newer MR contrast agents (such as ultrasmall iron oxide particles) and molecular imaging in MS. These articles are consistently well researched and written and do an excellent job of covering the relative strengths and limitations of each respective technique for characterizing central nervous system alterations in patients with MS. Not surprisingly, there is even less for the non-academician in the second volume, though the article on spinal cord imaging does include a fair amount on conventional spinal imaging techniques and common issues encountered in the clinical setting.

Redundancy becomes evident as one progresses through these issues, because several of the same topics are discussed repeatedly in different articles, albeit in varying degrees of depth. For instance, the basics of MT MR imaging are covered separately in at least one third of the articles. Although this might be fine if one is only planning to read 1 or 2 chapters, it



may become a little repetitious when one is attempting to read each volume cover to cover. Mind you, this critique is not directed at any 1 specific article but rather reflects a general shortcoming of the *Clinics* format, which aims to collect a number of stand-alone, but usually overlapping, contributions into a single collection.

The figures and illustrations found within the chapters are generally well selected and of good quality and nicely complement the text, though the degree to which each article is illustrated varies considerably and the legends range from being fairly minimalist to being overlong, depending on the article.

Minor criticisms aside, this 2-volume series provides read-

ers with an excellent overview of the most promising MR imaging techniques currently being used in MS research and of the wealth of new and sometimes confounding information that these techniques are revealing about the pathophysiology and natural history of the disorder. The articles are comprehensively researched and engaging and do a fine job of distilling a great deal of new data into a very manageable package (weighing in at just under 300 pages). This 2-part series should prove to be an extremely useful resource for those involved in ongoing MS research or in the care of patients with this highly debilitating disease.

DOI 10.3174/ajnr.A1596