



Discover Generics

Cost-Effective CT & MRI Contrast Agents



FRESENIUS
KABI

WATCH VIDEO

AJNR

Outcome in AIDS-Related Systemic Non-Hodgkin Lymphoma and Leptomeningeal Disease Is Not Predicted by a CT Brain Scan

C.L. Davies, R. Chinn, M. Nelson, M. Rasanesan, B. Gazzard, T. Powles, M. Bower and J. Stebbing

This information is current as of June 27, 2025.

AJNR Am J Neuroradiol published online 26 September 2007

<http://www.ajnr.org/content/early/2007/09/26/ajnr.A0718.citation>

ORIGINAL
RESEARCH

C.L. Davies
R. Chinn
M. Nelson
M. Rasanesan
B. Gazzard
T. Powles
M. Bower
J. Stebbing

Outcome in AIDS-Related Systemic Non-Hodgkin Lymphoma and Leptomeningeal Disease Is Not Predicted by a CT Brain Scan

BACKGROUND AND PURPOSE: AIDS-related systemic non-Hodgkin lymphoma (ARL) remains a significant cause of morbidity and mortality in patients infected with the human immunodeficiency virus (HIV-1), and leptomeningeal disease in this setting has a dismal prognosis. We investigated the utility of brain CT in determining the outcome of leptomeningeal disease, despite MR imaging being the gold standard.

MATERIALS AND METHODS: From a cohort of 9621 HIV-1-seropositive individuals, we identified those diagnosed with ARL in the highly active antiretroviral therapy (HAART) era who had both a lumbar puncture and central nervous system imaging using a CT brain scan at the time of initial diagnosis, and we compared survival parameters between those with and without leptomeningeal disease.

RESULTS: In a cohort of 82 individuals with ARL treated in the era of HAART, we found that the survival of individuals with leptomeningeal disease defined as the presence of cells in the CSF was worse compared with that of other patients ($P = .0026$). However, when defined by the presence of abnormal enhancement or parenchymal lesions on a CT scan, the outcome was not significantly different.

CONCLUSION: A CT brain scan appears not to offer additional prognostic information following a lumbar puncture in patients with ARL.

In established market economies, treatment with highly active antiretroviral therapy (HAART) has reduced morbidity and mortality associated with infection with the human immunodeficiency virus (HIV).¹ Non-Hodgkin lymphoma (NHL) remains the second most common tumor in individuals infected with HIV-1, after Kaposi sarcoma, and the mortality of AIDS-related systemic non-Hodgkin lymphoma (ARL) remains high.^{2,3} The median survivals reported with chemotherapy in the pre-HAART era were 2–13 months,⁴ though the outcome of ARL appears to have improved in the HAART era.⁵

The most common form of central nervous system (CNS) involvement in systemic NHL is leptomeningeal disease, a devastating complication that usually occurs in conjunction with systemic metastases.^{6,7} Also known as neoplastic meningitis and meningeal carcinomatosis, its diagnosis has been facilitated by advances in neuroimaging that may demonstrate discrete enhancement abnormalities and laboratory analysis of CSF, though cytologic evaluation of CSF does not consistently detect malignant cells.⁸ After a diagnosis of leptomeningeal NHL is established, the use of intrathecal chemotherapy and/or radiation therapy, in addition to systemic chemotherapy, can improve survival and palliate symptoms.

Although MR imaging is generally thought of as the standard of care and recent papers have delineated the optimal manner to perform such scans, these investigations often remain difficult to obtain, especially in the developing world,⁹ and require patients to remain still. To evaluate the utility of a CT brain scan in the outcome of patients with potential lepto-

meningeal disease, we investigated the survival of individuals with ARL and leptomeningeal disease, diagnosed either on a CT brain scan and/or with the presence of tumor cells in the CSF.

Methods

The Chelsea and Westminster HIV cohort is one of the largest in Europe, and clinical information on a total of 9621 HIV-seropositive patients has been accumulated since 1986. All patients who were diagnosed with lymphoma were identified prospectively, and we restricted our study to those individuals with systemic ARL diagnosed in the HAART era and who had both a lumbar puncture and CNS imaging by using a CT brain scan at the time of initial diagnosis. We identified 82 patients who fulfilled these criteria in the HAART era.

All patients had histologically confirmed diagnoses of ARL by using a peripheral (lymph node or organ) or bone marrow biopsy. CT brain scans were independently reviewed by a radiologist, and patients were classified as having no CNS involvement, meningeal disease, and/or a cerebral mass. CSF protein was measured by using the PRM assay (Sigma Aldrich, Poole, Dorset, UK) with an upper limit of normal of 450 mg/L; cytopspins were performed by using standard light microscopy to detect cells. MR imaging scans were not included in this analysis, and individuals with primary CNS lymphomas were excluded.

Comparison of variables between groups was by χ^2 test for nominal variables and the Mann-Whitney U test for nonparametric variables. Survival was calculated from the day of diagnosis until death or the date of last follow-up. Overall survival duration curves were plotted according to the method of Kaplan and Meier.¹⁰ The logrank method was used to test for the significance of differences in survival distributions.¹¹ Appropriate ethical approval was obtained.

Results and Discussion

A CT brain scan does not appear to offer additional prognostic information in leptomeningeal disease. Our cohort of 82 individuals with ARL in the HAART era had a median CD4 cell count of 176 cells/mm (range, 0–636) and a mean age of 43

Received February 12, 2007; accepted after revision April 20.

From the Department of Oncology, Imperial College School of Science, Medicine and Technology, Chelsea and Westminster Hospital, London, United Kingdom.

Please address correspondence to J. Stebbing, PhD, MRCP, Department of Oncology, Imperial College School of Science, Medicine and Technology, Charing Cross Hospital, London W6 8RF UK; e-mail: j.stebbing@imperial.ac.uk

DOI 10.3174/ajnr.A0718

Clinicopathological details of 82 patients with ARL in the HAART era ^a	
Clinical Characteristic	Number (%)
Sex	
Male	74 (90)
Female	8 (10)
Prior AIDS-defining illness	
No	68 (83)
Yes	14 (17)
On antiretrovirals prior to ARL diagnosis	
No	31 (38)
Yes	51 (62)
HIV-1 RNA viral load <50 copies/mL at the time of diagnosis ^b	
No	62 (76)
Yes	20 (28)
International Prognostic Index risk group ^c	
High	21 (26)
High/intermediate	22 (28)
Low	19 (24)
Low/intermediate	18 (22)
ECOG performance status	
0	5 (6)
1	39 (48)
2	22 (27)
3	9 (11)
4	7 (8)
Histology	
Burkitt	11 (13)
DLBCL	65 (79)
Other	5 (8)
Meningeal enhancement on CT	
No	79 (97)
Yes	3 (3)
Parenchymal lesion on CT brain	
No	75 (91)
Yes	7 (9)
Raised CSF protein	
No	36 (44)
Yes	43 (46)
Meningeal disease at diagnosis	
No	65 (79)
Yes	17 (21)

Note:—DLBCL indicates diffuse large B-cell lymphoma; RNA, ribonucleic acid.

^a CD4 subset analysis was performed using whole blood stained with murine antihuman monoclonal antibodies to CD4 (T helper cells, TetraOne; Beckman Coulter, High Wycombe, UK) and was evaluated on an Epics XL-MCL (Beckman Coulter) multiparametric 4-color flow cytometer. There were no missing data.

^b Plasma viral loads (Quantiplex HIV RNA 3.0; Chiron, Halstead, UK) were recorded since 1998 with a lower limit of detection of 50 copies/mL.

^c The International Prognostic Index was defined according to well-known established criteria.¹²

years (range, 23–77 years), and most (79%) had a diagnosis of diffuse large B-cell lymphoma (Table). In addition, most had been exposed to HAART before ARL diagnosis and had a European Cooperative Oncology Group (ECOG) performance status of 1–2; most were male, reflective of the patient composition of the entire HIV cohort. Forty-three patients (46%) had a raised CSF protein at ARL diagnosis. A total of 17 (21%) patients had lymphoma cells in the CSF; only 3 were reported as having meningeal enhancement, whereas 7 had a mass on CT. All 3 patients with meningeal enhancement had tumor cells in the CSF and a raised protein.

Individuals with ARL have a poor prognosis,¹³ regardless of the histologic type.⁵ We found that individuals with meningeal ARL (leptomeningeal disease), defined as the presence of malignant cells in a diagnostic lumbar puncture at the time of

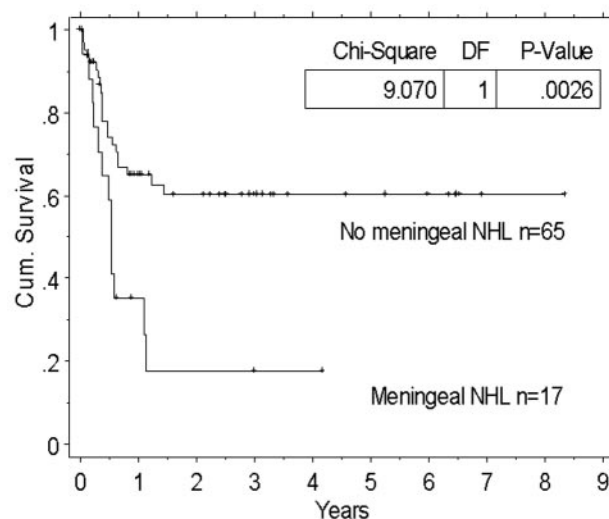


Fig 1. A Kaplan-Meier curve comparing the survival of patients with and without leptomeningeal disease and ARL. Cum indicates cumulative.

diagnosis, had a worse outcome compared with those individuals without meningeal ARL (logrank $P = .0026$, Fig 1). However, measured overall survival was not affected by meningeal disease, defined by abnormal CT enhancement (logrank $P = .126$) or by parenchymal lesions demonstrated on CT (logrank $P = .073$). Both parenchymal lesions on CT scan and/or abnormal meningeal enhancement did, however, correlate with meningeal disease (defined by CSF cytology; $P = .3$ and $P = .05$, respectively).

Although the numbers of individuals with CNS pathology are small, it appears that a CT brain scan does not add prognostic information over CSF protein and cell count in the diagnosis of meningeal involvement. This disease has become an increasingly important late complication in oncology and HIV medicine, as patients survive longer and develop more CNS involvement and newer chemotherapies fail to penetrate the blood-brain barrier. As such, leptomeningeal lymphoma can be considered an emerging tumor entity, as well as a variant of CNS metastases. The hallmark of clinical presentation is a patient with cancer who has focal neurologic dysfunction and is found to have multifocal signs on neurologic examination. The clinical course is relentlessly progressive, and treatment is limited. This study confirms the poor prognosis and suggests that a CT brain scan does not provide additional prognostic information over and above CSF protein and cytospin, in the diagnosis of leptomeningeal ARL. Although this is not surprising because CT cannot exclude leptomeningeal disease, a CT brain scan may, however, be useful to exclude a space-occupying lesion as a cause of raised intracranial pressure, in addition to a lumbar puncture.

References

1. Palella FJ Jr, Delaney KM, Moorman AC, et al. Declining morbidity and mortality among patients with advanced human immunodeficiency virus infection: HIV Outpatient Study Investigators. *N Engl J Med* 1998;338:853–60
2. Stebbing J, Bower M. What can oncologists learn from HIV? *Lancet Oncol* 2003;4:438–45
3. Stebbing J, Gazzard B, Mandalia S, et al. Antiretroviral treatment regimens and immune parameters in the prevention of systemic AIDS-related non-Hodgkin's lymphoma. *J Clin Oncol* 2004;22:2177–83
4. Stebbing J, Marvin V, Bower M. The evidence-based treatment of AIDS-related non-Hodgkin's lymphoma. *Cancer Treat Rev* 2004;30:249–53

5. Bower M, Gazzard B, Mandalia S, et al. **A prognostic index for systemic AIDS-related non-Hodgkin lymphoma treated in the era of highly active antiretroviral therapy.** *Ann Intern Med* 2005;143:265–73
6. Abrey LE. **Leptomeningeal noplasm.** *Curr Treat Options Neurol* 2002; 4:147–56
7. Sarker D, Thirlwell C, Nelson M, et al. **Leptomeningeal disease in AIDS-related non-Hodgkin's lymphoma.** *AIDS* 2003;17:861–65
8. Gleissner B, Siehl J, Korfel A, et al. **CSF evaluation in primary CNS lymphoma patients by PCR of the CDR III IgH genes.** *Neurology* 2002;58:390–96
9. Kremer S, Abu Eid M, Bierry G, et al. **Accuracy of delayed post-contrast FLAIR MR imaging for the diagnosis of leptomeningeal infectious or tumoral diseases.** *J Neuroradiol* 2006;33:285–91
10. Kaplan E, Meier P. **Nonparametric estimation from incomplete observations.** *J Am Stat Assoc* 1958;53:457–81
11. Peto R, Pike M, Armitage P, et al. **Design and analysis of randomized clinical trials requiring prolonged observation of each patient. II: Analysis and examples.** *Br J Cancer* 1977;35:1–39
12. **A predictive model for aggressive non-Hodgkin's lymphoma: The International Non-Hodgkin's Lymphoma Prognostic Factors Project.** *N Engl J Med* 1993;329:987–94
13. Lim ST, Karim R, Nathwani BN, et al. **AIDS-related Burkitt's lymphoma versus diffuse large-cell lymphoma in the pre-highly active antiretroviral therapy (HAART) and HAART eras: significant differences in survival with standard chemotherapy.** *J Clin Oncol* 2005;23:4430–38