



**Providing Choice & Value**

Generic CT and MRI Contrast Agents



**FRESENIUS  
KABI**

**CONTACT REP**

**AJNR**

This information is current as  
of July 13, 2025.





## **Prevalence and Characteristics of Intracranial Aneurysms in Hereditary Hemorrhagic Telangiectasia**

How-Chung Cheng, Marie E. Faughnan, Karel G. terBrugge,  
Hon-Man Liu, Timo Krings and the Brain Vascular  
Malformation Consortium Hereditary Hemorrhagic  
Telangiectasia Investigator Group

*AJNR Am J Neuroradiol* published online 30 November  
2023

<http://www.ajnr.org/content/early/2023/11/30/ajnr.A8058>

# Prevalence and Characteristics of Intracranial Aneurysms in Hereditary Hemorrhagic Telangiectasia

 How-Chung Cheng,  Marie E. Faughnan, Karel G. terBrugge,  Hon-Man Liu,  Timo Krings, and the Brain Vascular Malformation Consortium Hereditary Hemorrhagic Telangiectasia Investigator Group



## ABSTRACT

**BACKGROUND AND PURPOSE:** The association between hereditary hemorrhagic telangiectasia and intracranial aneurysms remains controversial. This study evaluated the prevalence and characteristics of intracranial aneurysms in patients with hereditary hemorrhagic telangiectasia with brain vascular malformations.

**MATERIALS AND METHODS:** Between 2007 and 2021, patients enrolled in the Brain Vascular Malformation Consortium with definite hereditary hemorrhagic telangiectasia, the presence of brain vascular malformations, and available angiographic studies of the brain were retrospectively reviewed. Angiographic features of intracranial aneurysms and their relationship to coexisting brain vascular malformations were analyzed. We also examined the association between baseline clinical features and the presence of intracranial aneurysms.

**RESULTS:** One hundred eighty patients were included. A total of 14 intracranial aneurysms were found in 9 (5%) patients, and 4 intracranial aneurysms were considered flow-related aneurysms. Patients with intracranial aneurysms were significantly older than patients without intracranial aneurysms (mean, 48.1 [SD, 18.2] years versus 33.5 [SD, 21.0] years;  $P = .042$ ). If we excluded flow-related intracranial aneurysms, the prevalence of intracranial aneurysms was 3.3%. All intracranial aneurysms were in the anterior circulation, were unruptured, and had an average maximal diameter of 3.9 (SD, 1.5) mm. No intracranial aneurysms were found in pediatric patients with hereditary hemorrhagic telangiectasia. No statistically significant correlation was observed among other baseline demographics, hereditary hemorrhagic telangiectasia features, and the presence of intracranial aneurysms.

**CONCLUSIONS:** The prevalence of intracranial aneurysms in this large cohort study is comparable with that in the general population and might be increased slightly due to hemodynamic factors associated with shunting brain vascular malformations.

**ABBREVIATIONS:** HHT = hereditary hemorrhagic telangiectasia; IA = intracranial aneurysm; VM = vascular malformation

**H**ereditary hemorrhagic telangiectasia (HHT) or Osler-Weber-Rendu syndrome is an autosomal dominant disorder characterized by mucocutaneous telangiectasias and vascular malformations (VMs) in organs, including the liver, gastrointestinal tract,

lungs, brain, and spinal cord.<sup>1,2</sup> It is caused by mutations in one of several genes involved in the transforming growth factor- $\beta$ /bone morphogenetic protein signaling pathway. Loss-of-function mutations in HHT genes have been shown to impair endothelial cell proliferation and migration during angiogenesis and vascular remodeling.<sup>1,3,4</sup> Approximately 96% of individuals with a definite clinical diagnosis of HHT have a mutation in the endoglin (*ENG*) gene or activin A receptor type II-like kinase 1 (*ACVRL1*) gene,<sup>5</sup> and about 3% of patients have a mutation in the *SMAD4* gene. The diagnosis of HHT is made clinically using the Curaçao criteria, which include spontaneous and recurrent nose bleeds, multiple


Received July 24, 2023; accepted after revision October 6.

From the Division of Neuroradiology (H.-C.C., K.G.t., T.K.), Joint Department of Medical Imaging, Toronto Western Hospital, University Health Network, Toronto, Ontario, Canada; Division of Neurosurgery (H.-C.C.), Department of Surgery, and Department of Medical Imaging (H.-M.L.), Fu Jen Catholic University Hospital, Fu Jen Catholic University, New Taipei City, Taiwan; Toronto HHT Centre (M.E.F.), St. Michael's Hospital and Li Ka Shing Knowledge Institute, Toronto, Ontario, Canada; and Division of Respiriology (M.E.F.), Department of Medicine, University of Toronto, Toronto, Ontario, Canada.

The Brain Vascular Malformation Consortium is part of the Rare Diseases Clinical Research Network, which is funded by the National Institutes of Health and led by the National Center for Advancing Translational Sciences through its Office of Rare Diseases Research. The Brain Vascular Malformation Consortium is funded under grant No. U54NS065705 as a collaboration between the National Center for Advancing Translational Sciences and the National Institute of Neurological Disorders and Stroke. All Rare Diseases Clinical Research Network consortia are supported by the network's Data Management and Coordinating Center (U2CTR002818). Funding support for the Data Management and Coordinating Center is provided by National Center for Advancing Translational Sciences and the National Institute of Neurological Disorders and Stroke.

M.E.F. was also supported by the Li Ka Shing Knowledge Institute. This work was funded, in part, by the Holt-Hornsby and Andreae Fund and University Medical Imaging Toronto.

Please address correspondence to How-Chung Cheng, Division of Neuroradiology, Joint Department of Medical Imaging, Toronto Western Hospital, University Health Network, 399 Bathurst St, Toronto, ON, M5T 2S8, Canada; e-mail: vionishc@gmail.com

 Indicates article with online supplemental data.

<http://dx.doi.org/10.3174/ajnr.A8058>

mucocutaneous telangiectasias (of the lips, oral cavity, nose, or fingers), visceral VMs (of the liver, lungs, or CNS), and a first-degree relative with HHT. Patients are diagnosed with “definite HHT” when 3 of these 4 criteria are met, whereas those who fulfill 2 criteria are considered to have “possible HHT.”<sup>6</sup> For asymptomatic individuals from a family with known HHT, the International HHT Guidelines recommend genetic testing for diagnosis.<sup>5</sup>

Patients with HHT present with a wide variety of cerebrovascular diseases. Between 10% and 20% of patients have brain VMs, classified in previous studies as pial AVFs, nidus-type AVMs, or capillary vascular malformations.<sup>7–11</sup> Other nonshunting vascular lesions such as cavernous malformations, developmental venous anomalies, and intracranial aneurysms (IAs) were also found in patients with HHT.<sup>8,11,12</sup>

Although earlier studies reported the prevalence of IAs in the HHT population,<sup>8,11,13,14</sup> no studies have addressed the characteristics of these aneurysms and their relationship to AVMs. The present study aimed to determine the prevalence of IAs in the HHT population, identify angiographic features of IAs, and examine the correlation between IAs and brain VMs in patients with HHT. Notably, a recent study found a strikingly high 14.5% prevalence of IAs in an HHT cohort, contrary to previous studies.<sup>14</sup> Current screening recommendations may need refinement if this higher prevalence of IAs is confirmed in our data set.

## MATERIALS AND METHODS

### Study Population

We analyzed patient data from the HHT project of the Brain Vascular Malformation Consortium. Patients with either a confirmed genetic diagnosis or a definite clinical diagnosis of HHT, based on the presence of at least 3 of the Curaçao criteria,<sup>6</sup> were enrolled in the Brain Vascular Malformation Consortium HHT project as previously reported.<sup>10,15</sup> The Brain Vascular Malformation Consortium HHT cohort aimed for a 25% recruitment target for patients with brain VMs.<sup>15</sup> From January 2007 to December 2021, we included all recruited patients with brain VMs and available angiographic studies (ie, CTA, MRA, and/or DSA). All patients provided written, informed consent. The study was approved by each participating center’s institutional review board.

### Data Collection

For each patient, we collected data including age at enrollment, sex, clinical presentations, family history, and genetic testing results (*ENG*, *ACVRL1*, *SMAD4*) when available. Radiologic data included biplanar 6-vessel selective cerebral angiography, contrast-enhanced MRA or TOF-MRA using 1.5T or 3T scanners, and CTA. All images were retrospectively reviewed by 2 of the authors (H.-C.C. and T.K.) in consensus. Images were assessed for the presence of IAs and shunting lesions such as AVMs and AVFs, as classified in previous studies.<sup>10,16</sup> The aneurysm location, the number of aneurysms per patient, their geometric measurements, and their relationship to the intracranial shunting lesions were recorded. We measured aneurysm neck width, dome-to-neck ratio, and aspect ratio on the PACS. Aneurysms with a neck diameter of  $\geq 4$  mm or a dome-to-neck ratio of  $< 2$  were classified as wide-neck.<sup>17,18</sup> A Spetzler-Martin grade was calculated for each AVM when the patient had a concurrent IA.<sup>19</sup>

**Table 1: Basic demographics of 180 subjects with HHT and brain VMs**

Characteristic	Summary <sup>a</sup> (%)
Age at enrollment (mean) (yr)	34.2 (SD, 21.1)
Women	111/180 (61.7%)
Curaçao criteria	
Epistaxis	168/180 (93.3%)
Mucosal telangiectasias	141/180 (78.3%)
Pulmonary AVMs	91/180 (50.6%)
Liver VMs	14/180 (7.8%)
Gastrointestinal bleeding	9/180 (5.0%)
Affected first-degree relative	135/180 (75%)
Genetic mutation	
<i>ENG</i>	109/131 (83.2%)
<i>ACVRL1</i>	21/131 (16.0%)
<i>SMAD4</i>	1/131 (0.7%)
DSA	116/180 (64.4%)
MRA	114/180 (63.3%)
CTA	5/180 (2.8%)
AVM	113/180 (62.8%)
AVF	16/180 (8.9%)
IAs	9/180 (5%)

<sup>a</sup>Summary is the number of observations with each value over the total available numbers (and the percentage) or the mean (SD) for continuous variables.

IAs were considered unrelated aneurysms when they presented on vessels that were not AVM feeders, whereas those arising from vessels contributing to perfusion of the nidus were termed flow-related aneurysms.<sup>20</sup> Flow-related aneurysms were further classified as proximal when located at the circle of Willis up to the primary bifurcation, while those more distally located were considered distal.

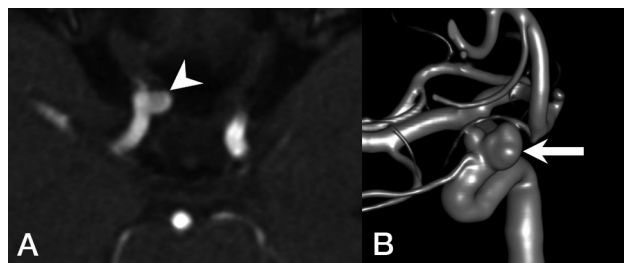
### Statistical Tests

We determined the prevalence of IAs by the number of patients having at least 1 IA divided by the total number of included patients with HHT. We tested for differences in age, sex, the presence of Curaçao criteria, and the presence of AVMs/AVFs between patients with IAs and those without. Continuous variables were compared using the Student *t* test, and categorical variables were compared using the Fisher exact test. We considered *P* values  $< .05$  as statistically significant. All analyses used SPSS (IBM).

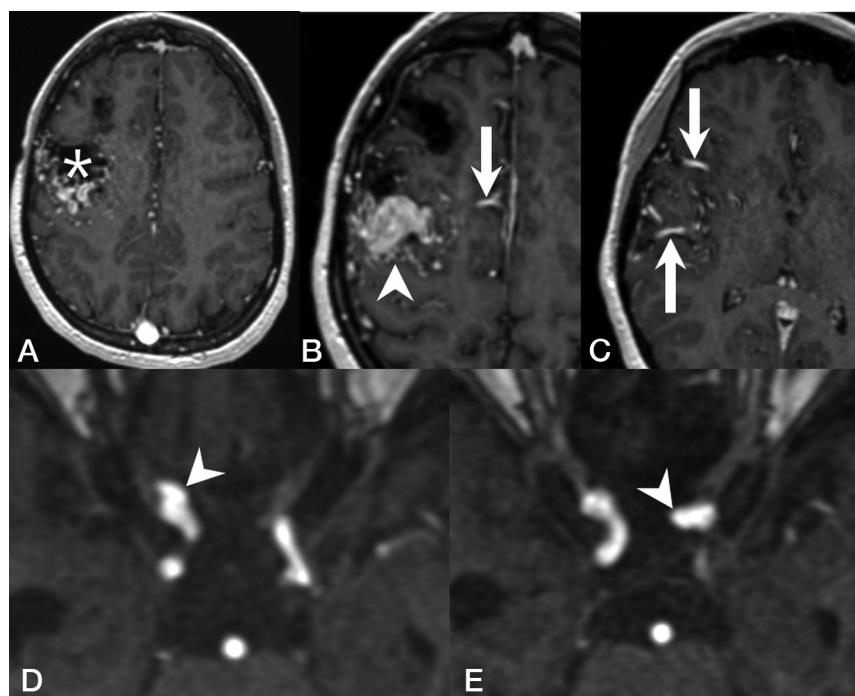
## RESULTS

One hundred eighty patients with HHT and brain VMs as well as available angiographic studies were included in the study. The average age at enrollment was 34.2 (SD, 21.1) years, with 54 (30%) subjects younger than 18 years of age. Female patients accounted for 61.7% of the population. One hundred thirty-one patients had positive findings on genetic testing: One hundred nine (83.2%) had an *ENG* mutation, 21 (16.0%) had an *ACVRL1* mutation, and 1 (0.7%) had a *SMAD4* mutation. Basic demographics and clinical features of the study population are summarized in Table 1.

Fourteen IAs were noted in 9 (5%) patients, and 3 (33%) patients had multiple aneurysms. No pediatric patients with HHT in this cohort had an IA. All IAs were unruptured and were found in the anterior circulation, most commonly located in the ICA (64%), followed by the anterior cerebral artery (21%). The average neck size and maximal aneurysm diameter



**FIG 1.** Representative images of a patient with HHT with an IA unrelated to AVMs. *A*, MRA demonstrates an ophthalmic segment aneurysm of the right ICA (arrowhead) projecting medially. *B*, 3D reconstruction of a DSA shows a bilobed, wide-neck, right ophthalmic segment aneurysm of the right ICA (arrow).



**FIG 2.** Representative images of a patient with HHT with flow-related cerebral aneurysms. T1 contrast-enhanced MR images demonstrate a Spetzler-Martin grade III right frontal AVM with a nidus size of 4 cm (*A*, asterisk) and venous varices (*B*, arrowhead), supplied by several dilated arterial feeders from the right anterior cerebral arteries (*B*, arrow) and the right middle cerebral arteries (*C*, arrow). MRA demonstrates a clinoid segment aneurysm of the right ICA (*D*, arrowhead) and another aneurysm arising from the ophthalmic segment of the left ICA (*E*, arrowhead).

were 3.7 (SD, 1.3) mm and 3.9 (SD, 1.5) mm, respectively. The average aspect ratio was 0.92 (SD, 0.30). All aneurysms had a dome-to-neck ratio of  $<2$ . A representative example of IAs is shown in Fig 1.

Of the 9 patients with IAs, 6 had nidus-type brain AVMs, 1 had an AVF, and 2 had a capillary vascular malformation. Ten (71%) of the 14 IAs were considered unrelated to the VMs, whereas 4 (29%) were considered flow-related aneurysms arising from a feeding artery of a shunting VM. One patient with a right frontal Spetzler-Martin grade III AVM and a nidus size of 4 cm had 1 aneurysm on each of the ICAs (Fig 2). Another patient with a left frontal AVF and a large venous pouch had an aneurysm on the ipsilateral anterior cerebral artery. The last patient

had 2 Spetzler-Martin grade I AVMs in the same hemisphere as the aneurysm. The characteristics of IAs and angiographic features are summarized in the Online Supplemental Data. Patients with IAs were significantly older compared with patients without IAs (mean, 48.1 [SD, 18.2] years versus 33.5 [SD, 21.0] years;  $P = .042$ ). No statistically significant association was found between patients with or without IAs regarding sex, the presence of the Curaçao criteria, or the presence of concurrent shunting brain VMs (AVMs and/or AVFs) (Table 2).

## DISCUSSION

The association between HHT and IAs remains controversial. In a report on neurovascular manifestations of patients with HHT, Brinjikji et al<sup>11</sup> demonstrated a 2.1% prevalence of IAs. Woodall et al<sup>8</sup> evaluated 230 patients with HHT and found a 2.4% prevalence of IAs. Ring et al<sup>13</sup> looked for arterial aneurysms in all locations in an HHT cohort and reported a 4.3% IA prevalence. A very recent study from Perez Akly et al<sup>14</sup> found 33 (14.5%) patients with HHTs with IAs,  $>3$ -fold higher than the prevalence rate of 3.2% in the general population,<sup>21</sup> thus potentially changing the clinical practice regarding active screening for IAs in patients with HHT. This remarkable discrepancy and the potential impact of encountering a high prevalence of IAs in patients with HHT prompted the present study.

We report a prevalence of IAs of 5% in this largest series of patients with HHT with brain VMs. In the subgroup of patients not having flow-related IAs, the prevalence of IAs was 3.3%, very similar to that of the general population. Although we included specifically patients with HHT with brain VMs, our observation is in line with the reported prevalences by Brinjikji et al,<sup>11</sup> Woodall et al,<sup>8</sup> and Ring et al.<sup>13</sup> In addition, our study cohort shares similar prevalences of epistaxis,<sup>8,11,14</sup> mucosal telangiectasias,<sup>1,11,22</sup> and pulmonary AVMs<sup>1,11,23,24</sup> with previous reports, and, therefore, is likely generalizable to unselected patients with HHT. Because children can develop complications of HHT,<sup>25</sup> we believe that it is necessary to include the pediatric population in this epidemiologic study to better understand the prevalence and natural history of IAs and, more important, to determine whether HHT is associated with an increased risk of IAs. Moreover, we are convinced that by including all patients with available angiographic studies of all types (ie, CTA, MRA, and/or DSA), our observed prevalence of IAs more accurately reflects the prevalence of IAs in the HHT population. According to our findings and those of the latter 3 studies,<sup>8,11,13</sup> the prevalence of IAs in HHT is similar to that in the general



**Table 2: Bivariate analysis between baseline demographics and IAs**

Outcome	Patients with IAs (n = 9)	Patients without IAs (n = 171)	P Value
Age (mean) (yr)	48.1 (SD, 18.2)	33.5 (SD, 21.0)	.042
Women	7/9 (77.8%)	104/171 (60.8%)	.486
Curaçao criteria			
Epistaxis	9/9 (100%)	159/171 (93.0%)	1.000
Telangiectasias	8/9 (88.9%)	133/171 (77.8%)	.687
Pulmonary AVMs	6/9 (66.7%)	85/171 (49.7%)	.497
Liver VMs	2/9 (22.2%)	12/171 (7.0%)	.148
Gastrointestinal bleeding	0/9 (0%)	9/171 (5%)	1.000
Affected first-degree relative	5/9 (55.6%)	130/171 (76.0%)	.230
AVM	6/9 (66.7%)	107/171 (62.6%)	1.000
AVF	1/9 (11.1%)	15/171 (8.8%)	.576
AVM or AVF	7/9 (77.8%)	122/171 (71.3%)	1.000

population, with a small additional prevalence of IAs in patients with HHT with coexisting shunting brain VMs.

This observation is in keeping with pathogenetic concepts of HHT in several ways. First, it is postulated that in HHT, the targets of the dysfunction are the venules instead of the arteries.<sup>16</sup> Early histopathologic studies demonstrated that the clinically detectable lesions of HHT start with focal dilation of postcapillary venules, which enlarge and connect with arterioles, eventually forming direct arteriovenous shuntings as capillaries disappear.<sup>1,26</sup> More recent animal studies also suggest that the *ENG/ACVRL1* signaling pathway mediates the endothelial cell shear stress response and is essential for flow-induced endothelial cell migration against the direction of blood flow, starting from growing veins, ie, flow-migration coupling. Loss of *ENG* or *ACVRL1* expression in venous and capillary endothelial cells is sufficient to cause AVMs as a result of impaired flow-migration coupling, whereas *ENG* or *ACVRL1* deletion in arterial endothelial cells does not lead to AVM formation.<sup>4,27-30</sup> Histopathologically, HHT is unlikely to be associated with a higher prevalence of IAs. Second, although several reports have associated the interruption of the transforming growth factor- $\beta$  signaling pathway with a higher prevalence of visceral aneurysms in patients with HHT due to its important role in extracellular matrix remodeling,<sup>13,31</sup> there is no genetic evidence to support applying the same hypothesis to IAs. *ENG*, one of the most commonly found mutated genes in patients with HHT, has repeatedly been reported to have no association with IAs.<sup>32,33</sup>

In a study about sequencing transforming growth factor- $\beta$  pathway genes in familial IA cases, Santiago-Sim et al<sup>34</sup> demonstrated that mutations in transforming growth factor- $\beta$  receptor genes are not a major cause of IAs. Furthermore, a recently published genome-wide association study also demonstrated no evidence of polygenic overlap between other aortic aneurysms and IAs,<sup>35</sup> while another meta-analysis of genome-wide association study on genetic risk factors for IAs found no linkage between transforming growth factor- $\beta$ -related genes and the development of IAs.<sup>36</sup> Finally, unlike some other clinical features of HHT that become apparent in early childhood and evolve, no IAs were found in the pediatric population of our cohort. In addition, the mean age of patients with IAs in this study was 48 years, comparable with the mean age of 47–55 years described in non-HHT populations with IAs.<sup>37,38</sup> If IAs and VMs share the same

pathogenesis, there would presumably be more evidence of IAs in younger patients with HHT.

IAs in this study were most commonly found in the ICA and were small with a mean maximal diameter of 3.9 mm. Similar to findings in the previous studies,<sup>8,11,14</sup> no patients in this cohort presented with SAH, which may hint at a benign nature of IAs in HHT. Although there were a few case reports describing ruptured IAs in patients with HHT,<sup>39,40</sup> most were flow-related aneurysms associated with a shunting brain VM.

In this study, we found no association between IAs and shunting brain VMs. Because approximately 71% of included patients with HHT had at least 1 shunting brain VM, it is possible that we could not detect any significant difference in brain VM prevalence between patients with and without IAs, given this high prevalence of brain VMs in our cohort. Notably, merely 29% of the IAs in this study were related to the shunting brain VMs, and only 2% of the AVMs were found to have flow-related aneurysms, as opposed to 18% described previously by a meta-analysis on the natural history of brain AVMs and concurrent IAs in the non-HHT population.<sup>41</sup> One possible explanation is that most of the AVMs found in patients with HHT are <3 cm;<sup>10,11,42</sup> therefore, the hemodynamic factors related to the shunting in the AVM nidus, such as higher shear stress on the vessel wall, are less prominent among patients with HHT.

In conclusion, the prevalence of IAs in patients with HHT with brain VMs is similar to that in the general population. In addition, we observed that IAs in patients with HHTs are seen in adults, but not children, and they are typically small with a low likelihood of hemorrhagic presentation. Thus, our observations do not support a recommendation for routine screening of patients with HHT specifically for IAs.

This study has limitations. First, it has some inherent selection bias because we included only patients with brain VMs. Although the genetic linkage between IAs and brain VMs, if any, remains undetermined, the prevalence of IAs in our study was in line with that reported in the literature. Second, genetic information was not available for one-third of the included individuals; therefore, there was an insufficient sample size to assess the association between IAs and genes mutated. Also, our study cohort included few patients with *ACVRL1* or *SMAD4* mutations, unsurprisingly, given the known association between brain VMs and *ENG* mutation, among patients with HHT. Additional studies will be required to clarify the association between these genes and IAs. Finally, the limited sample size of IAs may reduce the power of the study to detect statistically significant correlations such as the association between IAs and shunting brain VMs, but there was no evidence of even a trend association.

## CONCLUSIONS

From this large cohort of patients with HHT and brain VMs, we demonstrate that the prevalence of IAs in HHT is similar to that

of the general population and is not clearly associated with the presence of shunting brain VMs. Further studies are required to explore the mechanistic linkage between HHT and IA formation and the natural history of IAs in the HHT population.

## ACKNOWLEDGMENTS

We would like to thank Professor Shiao-Chi Wu of National Yang Ming Chiao Tung University for statistical analysis.

### Brain Vascular Malformation Consortium Hereditary Hemorrhagic Telangiectasia Investigator Group:

Mary E. Atherton, Murali M. Chakinala, Marianne S. Clancy, Marie E. Faughnan, James R. Gossage, Adrienne M. Hammill, Katharine Henderson, Steven Hetts, Peter Hountras, Vivek Iyer, Raj S. Kasthuri, Helen Kim, Timo Krings, Michael T. Lawton, Doris Lin, Johannes Jurgen Mager, Douglas A. Marchuk, Justin P. McWilliams, Jamie McDonald, Ludmila Pawlikowska, Jeffrey Pollak, Felix Ratjen, Karen Swanson, Dilini Vethanayagam, Shantel Weinsheimer, Andrew J White, Pearce Wilcox.

**Disclosure forms** provided by the authors are available with the full text and PDF of this article at [www.ajnr.org](http://www.ajnr.org).

## REFERENCES

- Shovlin CL. Hereditary haemorrhagic telangiectasia: pathophysiology, diagnosis and treatment. *Blood Rev* 2010;24:203–19 [CrossRef Medline](#)
- McDonald J, Bayrak-Toydemir P, Pyeritz RE. Hereditary hemorrhagic telangiectasia: an overview of diagnosis, management, and pathogenesis. *Genet Med* 2011;13:607–16 [CrossRef Medline](#)
- McDonald J, Wooderchak-Donahue W, VanSant Webb C, et al. Hereditary hemorrhagic telangiectasia: genetics and molecular diagnostics in a new era. *Front Genet* 2015;6:1 [CrossRef Medline](#)
- Jin Y, Muhl L, Burmakin M, et al. Endoglin prevents vascular malformation by regulating flow-induced cell migration and specification through VEGFR2 signaling. *Nat Cell Biol* 2017;19:639–52 [CrossRef Medline](#)
- Faughnan ME, Mager JJ, Hetts SW, et al. Second international guidelines for the diagnosis and management of hereditary hemorrhagic telangiectasia. *Ann Intern Med* 2020;173:989–1001 [CrossRef Medline](#)
- Shovlin CL, Guttmacher AE, Buscarini E, et al. Diagnostic criteria for hereditary hemorrhagic telangiectasia (Rendu-Osler-Weber syndrome). *Am J Med Genet* 2000;91:66–67 [CrossRef Medline](#)
- Nishida T, Faughnan ME, Krings T, et al. Brain arteriovenous malformations associated with hereditary hemorrhagic telangiectasia: gene-phenotype correlations. *Am J Med Genet A* 2012;158A:2829–34 [CrossRef Medline](#)
- Woodall MN, McGettigan M, Figueroa R, et al. Cerebral vascular malformations in hereditary hemorrhagic telangiectasia. *J Neurosurg* 2014;120:87–92 [CrossRef Medline](#)
- Brinjikji W, Iyer VN, Sorenson T, et al. Cerebrovascular manifestations of hereditary hemorrhagic telangiectasia. *Stroke* 2015;46:3329–37 [CrossRef Medline](#)
- Krings T, Kim H, Power S, et al; Brain Vascular Malformation Consortium HHT Investigator Group. Neurovascular manifestations in hereditary hemorrhagic telangiectasia: imaging features and genotype-phenotype correlations. *AJNR Am J Neuroradiol* 2015;36:863–70 [CrossRef Medline](#)
- Brinjikji W, Iyer VN, Yamaki V, et al. Neurovascular manifestations of hereditary hemorrhagic telangiectasia: a consecutive series of 376 patients during 15 years. *AJNR Am J Neuroradiol* 2016;37:1479–86 [CrossRef Medline](#)
- Gaetani E, Peppucci E, Agostini F, et al. Distribution of cerebrovascular phenotypes according to variants of the ENG and ACVRL1 genes in subjects with hereditary hemorrhagic telangiectasia. *J Clin Med* 2022;11:2685 [CrossRef Medline](#)
- Ring NY, Latif MA, Hafezi-Nejad N, et al. Prevalence of and factors associated with arterial aneurysms in patients with hereditary hemorrhagic telangiectasia: 17-year retrospective series of 418 patients. *J Vasc Interv Radiol* 2021;32:1661–69 [CrossRef Medline](#)
- Perez Akly MS, Vazquez C, Besada CH, et al. Prevalence of intracranial aneurysms in hereditary hemorrhagic telangiectasia: report from a single reference center. *AJNR Am J Neuroradiol* 2022;43:844–49 [CrossRef Medline](#)
- Akers AL, Ball KL, Clancy M, et al. Brain vascular malformation consortium: overview, progress and future directions. *J Rare Disord* 2013;1:5 [Medline](#)
- Krings T, Ozanne A, Chng SM, et al. Neurovascular phenotypes in hereditary haemorrhagic telangiectasia patients according to age. Review of 50 consecutive patients aged 1 day–60 years. *Neuroradiology* 2005;47:711–20 [CrossRef Medline](#)
- Fernandez Zubillaga A, Guglielmi G, Viñuela F, et al. Endovascular occlusion of intracranial aneurysms with electrically detachable coils: correlation of aneurysm neck size and treatment results. *AJNR Am J Neuroradiol* 1994;15:815–20 [Medline](#)
- Debrun GM, Aletich VA, Kehrli P, et al. Aneurysm geometry: an important criterion in selecting patients for Guglielmi detachable coiling. *Neurol Med Chir (Tokyo)* 1998;38(Suppl):1–20 [CrossRef Medline](#)
- Spetzler RF, Martin NA. A proposed grading system for arteriovenous malformations. *J Neurosurg* 1986;65:476–78 [CrossRef Medline](#)
- Ramos SK, Gardenghi B, Bortolotti C, et al. Aneurysms associated with brain arteriovenous malformations. *AJNR Am J Neuroradiol* 2016;37:1966–67 [CrossRef Medline](#)
- Thompson BG, Brown RD Jr, Amin-Hanjani S, et al; American Stroke Association. Guidelines for the management of patients with unruptured intracranial aneurysms: a Guideline for Healthcare Professionals from the American Heart Association/American Stroke Association. *Stroke* 2015;46:2368–400 [CrossRef Medline](#)
- Hyldahl SJ, El-Jaji MQ, Schuster A, et al. Skin and mucosal telangiectatic lesions in hereditary hemorrhagic telangiectasia patients. *Int J Dermatol* 2022;61:1497–505 [CrossRef Medline](#)
- Jaskolka J, Wu L, Chan RP, et al. Imaging of hereditary hemorrhagic telangiectasia. *AJR Am J Roentgenol* 2004;183:307–14 [CrossRef Medline](#)
- Fish A, Henderson K, Moushey A, et al. Incidence of spontaneous pulmonary AVM rupture in HHT patients. *J Clin Med* 2021;10:4714 [CrossRef Medline](#)
- Kilian A, Latino GA, White AJ, et al; the Brain Vascular Malformation Consortium HHT Investigator Group. Genotype-phenotype correlations in children with HHT. *J Clin Med* 2020;9:2714 [CrossRef Medline](#)
- Braverman IM, Keh A, Jacobson BS. Ultrastructure and three-dimensional organization of the telangiectases of hereditary hemorrhagic telangiectasia. *J Invest Dermatol* 1990;95:422–27 [CrossRef Medline](#)
- Crist AM, Lee AR, Patel NR, et al. Vascular deficiency of Smad4 causes arteriovenous malformations: a mouse model of hereditary hemorrhagic telangiectasia. *Angiogenesis* 2018;21:363–80 [CrossRef Medline](#)
- Bernabeu C, Bayrak-Toydemir P, McDonald J, et al. Potential second-hits in hereditary hemorrhagic telangiectasia. *J Clin Med* 2020;9:3571 [CrossRef Medline](#)
- Singh E, Redgrave RE, Phillips HM, et al. Arterial endoglin does not protect against arteriovenous malformations. *Angiogenesis* 2020;23:559–66 [CrossRef Medline](#)
- Park H, Furtado J, Poulet M, et al. Defective flow-migration coupling causes arteriovenous malformations in hereditary hemorrhagic telangiectasia. *Circulation* 2021;144:805–22 [CrossRef Medline](#)

31. Moulinet T, Mohamed S, Deibener-Kaminsky J, et al. **High prevalence of arterial aneurysms in hereditary hemorrhagic telangiectasia.** *Int J Cardiol* 2014;176:1414–16 [CrossRef Medline](#)
32. Krex D, Ziegler A, Schackert HK, et al. **Lack of association between endoglin intron 7 insertion polymorphism and intracranial aneurysms in a white population: evidence of racial/ethnic differences.** *Stroke* 2001;32:2689–94 [CrossRef Medline](#)
33. Onda H, Kasuya H, Yoneyama T, et al. **Endoglin is not a major susceptibility gene for intracranial aneurysm among Japanese.** *Stroke* 2003;34:1640–44 [CrossRef Medline](#)
34. Santiago-Sim T, Mathew-Joseph S, Pannu H, et al. **Sequencing of TGF-beta pathway genes in familial cases of intracranial aneurysm.** *Stroke* 2009;40:1604–11 [CrossRef Medline](#)
35. van 't Hof FN, Ruigrok YM, Lee CH, et al; Aneurysm Consortium; Vascular Research Consortium of New Zealand. **Shared genetic risk factors of intracranial, abdominal, and thoracic aneurysms.** *J Am Heart Assoc* 2016;5:e002603 [CrossRef Medline](#)
36. Alg VS, Sofat R, Houlden H, et al. **Genetic risk factors for intracranial aneurysms: a meta-analysis in more than 116,000 individuals.** *Neurology* 2013;80:2154–65 [CrossRef Medline](#)
37. Weir B, Disney L, Karrison T. **Sizes of ruptured and unruptured aneurysms in relation to their sites and the ages of patients.** *J Neurosurg* 2002;96:64–70 [CrossRef Medline](#)
38. Backes D, Vergouwen MD, Tiel Groenestege AT, et al. **PHASES score for prediction of intracranial aneurysm growth.** *Stroke* 2015;46:1221–26 [CrossRef Medline](#)
39. Helmchen C, Nahser HC, Yousry T, et al. **Therapy of cerebral aneurysms and arteriovenous vascular malformations in hereditary hemorrhagic telangiectasia (Rendu-Osler-Weber disease)** [in German]. *Nervenarzt* 1995;66:124–28 [Medline](#)
40. Ishii D, Takechi A, Seyama G, et al. **Ruptured large basilar artery aneurysm associated with an arteriovenous malformation in hereditary hemorrhagic telangiectasia.** *Neurol Med Chir (Tokyo)* 2012;52:502–05 [CrossRef Medline](#)
41. Gross BA, Du R. **Natural history of cerebral arteriovenous malformations: a meta-analysis.** *J Neurosurg* 2013;118:437–43 [CrossRef Medline](#)
42. Brinjikji W, Iyer VN, Wood CP, et al. **Prevalence and characteristics of brain arteriovenous malformations in hereditary hemorrhagic telangiectasia: a systematic review and meta-analysis.** *J Neurosurg* 2017;127:302–10 [CrossRef Medline](#)