



Providing Choice & Value
Generic CT and MRI Contrast Agents

**FRESENIUS
KABI**

CONTACT REP

AJNR






Malignant Melanotic Nerve Sheath Tumor

J.C. Benson, M.D. Marais, P.M. Flanigan, M. Bydon, C. Giannini, R.J. Spinner and A.L. Folpe

AJNR Am J Neuroradiol published online 27 October 2022
<http://www.ajnr.org/content/early/2022/10/27/ajnr.A7691>

This information is current as
of July 14, 2025.

Malignant Melanotic Nerve Sheath Tumor

 J.C. Benson,  M.D. Marais, P.M. Flanigan,  M. Bydon,  C. Giannini,  R.J. Spinner, and A.L. Folpe

ABSTRACT

SUMMARY: Malignant melanotic nerve sheath tumors are uncommon pigmented tumors of Schwann cell origin, most often found along the spinal nerves. Although well-described in the literature, the tumors are quite rare, making up <1% of nerve sheath tumors. Physicians are, therefore, often unfamiliar with both the appearance and the optimal treatment of such tumors. Morphologically, many imaging features overlap with schwannomas and neurofibromas. Nevertheless, the malignant melanotic nerve sheath tumors are crucial to identify. They can be extremely aggressive, and the management of these tumors is considerably different from their benign counterparts. In this radiology-pathology review, we will highlight the imaging appearance, histologic features, surgical resection, and subsequent therapeutic strategies in a patient with a lumbar malignant melanotic nerve sheath tumor.

ABBREVIATION: MMNST = malignant melanotic nerve sheath tumor

The patient is a 39-year-old woman with no notable medical history who presented with a 5-year history of progressive left, lower-extremity, radicular symptoms. Her symptoms began as intermittent pain in her left leg, which evolved into constant pain and dysesthesias. On physical examination, she demonstrated mild weakness of left toe extension and trace weakness of left ankle inversion/eversion. An initial lumbar spine MR imaging performed at an outside institution 4 years prior to presentation was interpreted as having normal findings. Follow-up imaging, performed 1 year before presentation, identified a mass along the L5 nerve root. In retrospect, this had been present on the first examination and had grown in the interim. The patient presented to our institution for further management.

Imaging

MR imaging of the lumbar spine demonstrated an elongated well-circumscribed mass centered in the left L5-S1 foramen with both intra- and extradural components. The mass extended centrally to the left lateral recess and peripherally into the extraforaminal space along the exiting nerve root. There was no remodeling of the adjacent bone. Intratumoral signal was homogeneously hyperintense on T1 and hypointense on T2 (Fig 1). Homogeneous enhancement

was observed on postcontrast images. Comparison with prior imaging demonstrated progressive growth of the tumor during the course of the prior MRIs, from 1.0 to 1.6 cm in maximum axial diameter during a 4-year period. Because of its imaging characteristics, the mass was thought most likely to represent a malignant melanotic nerve sheath tumor. A melanin-containing metastasis was also considered possible, though less likely given the patient's negative medical history. A benign hemorrhagic nerve sheath tumor was thought to be unlikely, given its homogeneous intraleSIONAL signal and consistent appearance across time.

Imaging findings of the brain and cervical and thoracic spine were normal, without evidence of leptomeningeal metastases.

Operative Report

Given the patient's steadily worsening radicular symptoms, mild weakness on examination, and the uncertain malignant potential of the mass, surgical treatment was recommended. The tumoral resection required an L5 laminectomy and a complete left L5-S1 facetectomy due to the extensive involvement of the mass along the nerve (from the nerve root axilla to the extraforaminal segment of the left L5 nerve, even extending underneath the sacral ala). Intraoperatively, after the above bony elements had been removed, the melanotic-appearing spinal nerve was identified along its course by careful dissection of overlying soft tissues. Neuromonitoring was used to enhance intraoperative understanding of regional anatomy. Despite appropriate firing of other nerves in the operative field, a firing response was not able to be elicited, suggesting the nerve was nonfunctional from a motor standpoint.

Received August 15, 2022; accepted after revision September 30.

From the Departments of Radiology (J.C.B., M.D.M.), Neurologic Surgery (P.M.F., M.B.), and Laboratory Medicine and Pathology (C.G., R.J.S., A.L.F.), Mayo Clinic, Rochester, Minnesota.

Please address correspondence to John C. Benson, MD, Department of Radiology, Mayo Clinic, 200 1st St SW, Rochester, MN 55902; e-mail: benson.john3@mayo.edu
<http://dx.doi.org/10.3174/ajnr.A7691>

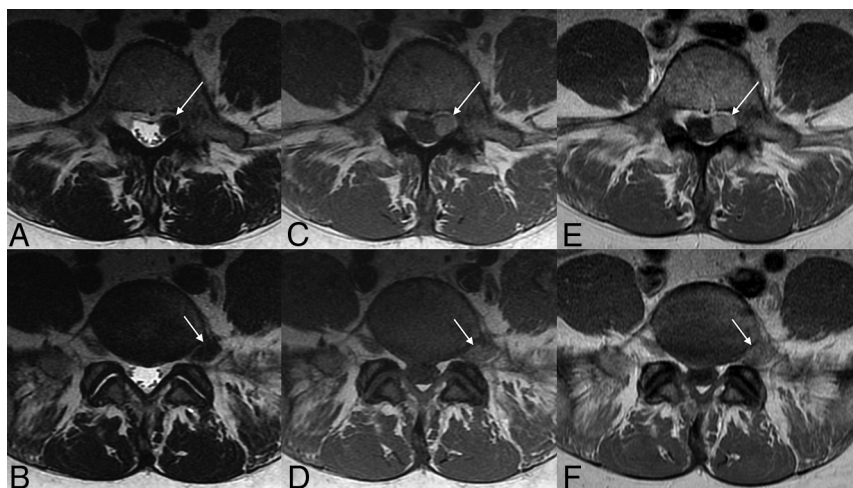


FIG 1 Axial T2 (A and B), T1 precontrast (C and D), and postgadolinium T1 (E and F) images of the lumbar spine. On each image, the tumor is seen transverse the left L5-S1 foramen along the exiting nerve root (arrows). The mass is distinctively hypointense to adjacent muscle on T2 and hyperintense to muscle on T1. Faint-but-convincing enhancement is noted on postcontrast images.

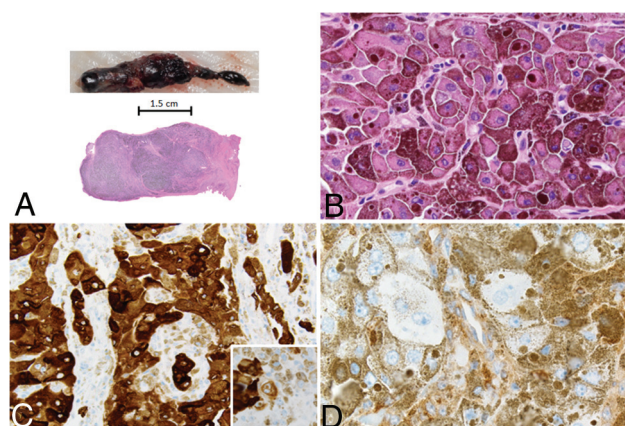


FIG 2 A, Gross photograph of a malignant melanotic schwannian tumor, presenting as a jet-black, roughly dumbbell-shaped mass involving the neural foramen. B, Microscopic view of malignant melanotic schwannoma, composed of moderately variable epithelioid cells with abundant intracytoplasmic melanin pigment and variably prominent nucleoli (H&E, original magnification $\times 200$). C, The tumor was strongly positive for Melan-A. D, Expression of the Carney complex-associated tumor-suppressor gene *PRKARIA* was entirely absent. Loss of *PRKARIA* expression is seen both in syndromic and nonsyndromic MMNSTs.

Under the microscope, the multilobular tumor was separated from the nerve using standard microsurgical dissection techniques. After identifying the most distal aspect of the tumor, a dissection plane was made between it and the nerve, proceeding in a distal-to-proximal direction. At its proximal extent, a small portion of intradural tumor extension was encountered and, consequently, CSF egress occurred from that site. The spinal fluid leak ultimately was repaired satisfactorily. A substantial majority of the mass was removed en bloc (Fig 2), and there was no trace of residual tumor seen grossly. The patient awoke at the neurologic baseline and had an uneventful postoperative course.

Pathology

Grossly, the tumor appeared as a jet-black, multinodular, fusiform expansion of the nerve root, measuring 4.5 cm in greatest dimension. Microscopically, the tumor cells were predominantly epithelioid in morphology, with abundant intracytoplasmic melanin pigment and variably-sized nuclei with prominent nucleoli; mitotic activity was $<1/50$ high-powered fields; and necrosis was absent (Fig 2). By immunohistochemistry, the neoplastic cells showed diffuse expression of S-100 protein and Melan-A with complete loss of *PRKARIA*, an immunophenotype diagnosis of malignant melanotic nerve sheath tumor (MMNST) in this clinical and morphologic context. Loss of *PRKARIA* expression is commonly seen in MMNST¹ and is not a feature of conventional malignant melanoma or melanoma arising

in a cellular blue nevus,² melanocytic tumors that share some morphologic and immunohistochemical features with MMNST. Although molecular genetic studies were not needed in the present case, MMNST also differed genetically from other malignant melanotic tumors, with MMNST having *PRKARIA* mutations; conventional melanomas showing mutations in *BRAF*, *NRAS* or *KRAS*; and melanoma arising in a blue nevus containing mutations in the *GNA* genes.

DISCUSSION

MMNSTs are pigmented tumors often located in the spine and paraspinal soft tissues.³ Formerly known as melanotic schwannomas, these tumors were reclassified in 2020 to reflect their aggressive clinical behavior.^{4,5} MMNSTs are rare, making up $<1\%$ of all nerve sheath tumors.⁶ The tumors tend to occur in the fourth decade of life without a sex predilection.⁷ Although MMNSTs can occur along cranial nerves, they tend to grow along the dorsal spinal nerve roots, and patients often present with indolent pain, weakness, or paresthesia along a corresponding dermatome.^{8,9} Tumors may also be discovered incidentally on spinal imaging. Although acute presentations have been described in MMNSTs, these reports are rare.^{10,11}

On imaging, spinal MMNSTs generally appear similar to the appearance presented in the current case: intradural, extramedullary tumors. In the spine, the tumors typically grow along spinal nerve roots, sometimes assuming a dumbbell configuration if they extend through a foramen. Tumors demonstrate enhancement on CT and are FDG-avid on PET.¹² Paramagnetic free radicals associated with the intratumoral melanin give the tumors a distinctive T1-hyperintense and T2-hypointense appearance. This feature is inconstant; 1 review found that only 65% of tumors demonstrated T1 hyperintensity, likely reflecting the variable concentrations of intratumoral melanin and cellular densities of tumors.¹³ Intratumoral T2 hyperintensity, too, is variable.⁸ In very rare cases, the tumors may arise from within

the spinal cord.¹⁴⁻¹⁶ No imaging features have been identified to serve as prognostic markers to predict the aggressiveness of the tumor.⁸

The major differential considerations for MMNSTs are those of other intradural, extramedullary tumors closely related to spinal nerves. The most likely entities would be benign schwannomas and neurofibromas, meningiomas, malignant peripheral nerve sheath tumors, or metastases. On CT, distinguishing these tumors may be impossible. The “dumbbell” morphology, for instance, is nonspecific; all of these tumors can take this shape if they contain both intradural and extradural components.¹⁷ On MR imaging, however, the intrinsic T1 hyperintensity associated with MMNSTs can be used to distinguish such tumors from their mimics. Schwannomas and neurofibromas tend to be hypointense on T1 and hyperintense on T2. Larger schwannomas, in particular, can be markedly T2 hyperintense and even demonstrate ringlike enhancement because they often undergo cystic degeneration.¹⁸ Nevertheless, T1 hyperintensity can also be seen in the setting of meningeal melanotic neoplasms and melanoma metastases, both of which could be included as differential considerations on imaging.¹⁹

The management of patients with MMNSTs can be complex. The tumors are capable of substantial malignant spread, with local recurrence found in more than one-third of patients, and metastatic disease, in 44% of cases.¹ Lungs are the most common site of metastases, though many other sites have been reported.²⁰⁻²² Some tumors can lead to considerable leptomeningeal spread.²³ MMNSTs are known to recur or spread after 5 years, even without sinister histologic markers.⁹

Furthermore, the tumors are associated with the Carney complex, an autosomal dominant syndrome characterized by cardiac and extracardiac myxomas, spotty skin pigmentation, endocrine overactivity, and testicular tumors.²⁴ The precise association between MMNSTs and Carney complex has been a matter of debate. Carney²⁵ reported that one-half of patients with MMNSTs containing psammoma bodies (previously called “psammomatous melanotic schwannomas”) had Carney complex features. Others, most notably Torres-Mora et al,¹ found no clinicopathologic differences between psammomatous and nonpsammomatous melanotic tumors, and they have doubted that any distinction exists between these tumor subtypes and their associations with Carney complex.

Surgical resection is the mainstay of treatment, with gross total resection recommended.²⁶ Adjuvant therapy and management of metastatic or recidivist disease, however, are less well-defined, given the scarcity of MMNSTs. Some authors suggest adjuvant radiation therapy following resection that did not accomplish clear surgical margins, though the evidence for this remains mostly anecdotal in the literature.^{6,27,28} The patient presented in this case is expected to have a favorable postoperative course. His most recent imaging, performed 4 months after the operation, showed no evidence of residual or recurrent tumor. He will be assessed by radiation oncology to consider adjuvant treatment and will undergo surveillance imaging to rule out recidivist disease.

Case Summary

- Although rare, MMNSTs are crucial to identify on imaging because they are aggressive and prone to metastasizing

- On MRI, MMNSTs demonstrate characteristic T1 hyperintensity and T2 hyperintensity related to intratumoral melanin
- Characteristic morphologic features and loss of *PRKARIA* expression help to distinguish MMNSTs from morphologic mimics, in particular metastatic melanoma and melanoma arising from a cellular blue nevus
- Surgical resection of the tumor should focus on safe and complete resection and should be en bloc when possible, given the variable metastatic and malignant potential of the tumor.

Disclosure forms provided by the authors are available with the full text and PDF of this article at www.ajnr.org.

REFERENCES

1. Torres-Mora J, Dry S, Li X, et al. **Malignant melanotic schwannian tumor: a clinicopathologic, immunohistochemical, and gene expression profiling study of 40 cases, with a proposal for the reclassification of “melanotic schwannoma.”** *Am J Surg Pathol* 2014;38:94–105 [CrossRef](#)
2. Shah K, Folpe AL, Miller M, et al. **Primary intra-abdominal melanoma arising in association with extracutaneous blue naevus: a report of two cases.** *Histopathology* 2021;78:281–89 [CrossRef Medline](#)
3. Meyer A, Billings SD. **What’s new in nerve sheath tumors.** *Virchows Arch* 2020;476:65–80 [CrossRef Medline](#)
4. Kallen ME, Hornick JL. **The 2020 WHO Classification: what’s new in soft tissue tumor pathology?** *Am J Surg Pathol* 2021;45:e1–23 [CrossRef Medline](#)
5. Sbaraglia M, Bellan E, Dei Tos AP. **The 2020 WHO Classification of Soft-Tissue Tumours: news and perspectives.** *Pathologica* 2021;113:70–84 [CrossRef Medline](#)
6. Sahay A, Epari S, Gupta P, et al. **Melanotic schwannoma, a deceptive misnomer for a tumor with relative aggressive behavior: a series of 7 cranial and spinal cases.** *Int J Surg Pathol* 2020;28:850–58 [CrossRef Medline](#)
7. Alexiev BA, Chou PM, Jennings LJ. **Pathology of melanotic schwannoma.** *Arch Pathol Lab Med* 2018;142:1517–23 [CrossRef Medline](#)
8. Khoo M, Pressney I, Hargunani R, et al. **Melanotic schwannoma: an 11-year case series.** *Skeletal Radiol* 2016;45:29–34 [CrossRef Medline](#)
9. Vallat-Decouvelaere AV, Wassef M, Lot G, et al. **Spinal melanotic schwannoma: a tumour with poor prognosis.** *Histopathology* 1999;35:558–66 [CrossRef Medline](#)
10. Zaninovich O, Ramey W, Eldersveld J, et al. **Malignant melanotic schwannian tumor presenting with spinal cord infarction due to occlusion of the artery of Adamkiewicz: case report and review of the literature.** *World Neurosurg* 2019;128:422–25 [CrossRef Medline](#)
11. Soyland DJ, Goehner DR, Hoerschgen KM, et al. **Hemorrhagic spinal melanotic schwannoma presenting as acute chest pain: a case report and literature review.** *Surg Neurol Int* 2021;12:164 [CrossRef Medline](#)
12. Liu E, Sun T, Liu C, et al. **Giant melanotic malignant peripheral nerve sheath tumor in the pelvis: contrast-enhanced CT and 18F-FDG PET/CT finding.** *Clin Nucl Med* 2019;44:895–97 [CrossRef Medline](#)
13. Solomou G, Dulanka Silva AH, Wong A, et al. **Extramedullary malignant melanotic schwannoma of the spine: case report and an up-to-date systematic review of the literature.** *Ann Med Surg (Lond)* 2020;59:217–23 [CrossRef Medline](#)
14. Hoover JM, Bledsoe JM, Giannini C, et al. **Intramedullary melanotic schwannoma.** *Rare Tumors* 2012;4:e3 [CrossRef Medline](#)
15. Hu L, Wang C. **Intramedullary melanotic schwannoma of the cervical spine: a case report and literature review.** *Mol Clin Oncol* 2018;8:567–70 [CrossRef Medline](#)
16. Santaguida C, Sabbagh AJ, Guiot MC, et al. **Aggressive intramedullary melanotic schwannoma: case report.** *Neurosurgery* 2004;55:1430 [CrossRef Medline](#)

17. Abul-Kasim K, Thurnher MM, McKeever P, et al. **Intradural spinal tumors: current classification and MRI features.** *Neuroradiology* 2008;50:301–14 [CrossRef Medline](#)
18. Koeller KK, Shih RY. **Intradural extramedullary spinal neoplasms: radiologic-pathologic correlation.** *Radiographics* 2019;39:468–90 [CrossRef Medline](#)
19. Rodriguez FJ, Folpe AL, Giannini C, et al. **Pathology of peripheral nerve sheath tumors: diagnostic overview and update on selected diagnostic problems.** *Acta Neuropathol* 2012;123:295–319 [CrossRef Medline](#)
20. Watson JC, Stratakis CA, Bryant-Greenwood PK, et al. **Neurosurgical implications of Carney complex.** *J Neurosurg* 2000;92:413–18 [CrossRef Medline](#)
21. Jackson C, Linos K, Liu X. **Malignant melanotic nerve sheath tumor in pleural effusion: deceitful cytology with significant repercussions.** *Diagn Cytopathol* 2022;50:E76–80 [CrossRef Medline](#)
22. Shen XZ, Wang W, Luo ZY. **18F-FDG PET/CT imaging for aggressive melanotic schwannoma of the L3 spinal root: a case report.** *Medicine (Baltimore)* 2021;100:e24803 [CrossRef Medline](#)
23. Shui C, Davey L, Scholsem M. **Leptomeningeal dissemination of a malignant melanotic nerve sheath tumor: a case report and review of the literature.** *Surg Neurol Int* 2022;13:59 [CrossRef Medline](#)
24. Grebenc ML, Rosado de Christenson ML, Burke AP, et al. **Primary cardiac and pericardial neoplasms: radiologic-pathologic correlation.** *Radiographics* 2000;20:1073–1103; quiz 1110–11, 12 [CrossRef Medline](#)
25. Carney JA. **Psammomatous melanotic schwannoma: a distinctive, heritable tumor with special associations, including cardiac myxoma and the Cushing syndrome.** *Am J Surg Pathol* 1990;14:206–22 [CrossRef Medline](#)
26. Zhang HY, Yang GH, Chen HJ, et al. **Clinicopathological, immunohistochemical, and ultrastructural study of 13 cases of melanotic schwannoma.** *Chin Med J (Engl)* 2005;118:1451–61 [Medline](#)
27. Hall JC, Chang SD, Wilson TJ, et al. **Post-operative stereotactic radiosurgery of malignant melanotic schwannoma.** *Cureus* 2022;14:e22849 [CrossRef Medline](#)
28. Spina A, Gagliardi F, Boari N, et al. **Intracranial melanotic schwannomas.** *J Neurol Surg A Cent Eur Neurosurg* 2015;76:399–406 [CrossRef Medline](#)