



## Discover Generics

Cost-Effective CT & MRI Contrast Agents



WATCH VIDEO

# AJNR








## **Carotid Intraplaque Hemorrhage and Stenosis: At What Stage of Plaque Progression Does Intraplaque Hemorrhage Occur, and When is It Most Likely to Be Associated with Symptoms?**

This information is current as of June 17, 2025.

A.S. Larson, W. Brinjikji, L. Savastano, A.A. Rabinstein, L. Saba, J. Huston and J.C. Benson

*AJNR Am J Neuroradiol* published online 22 April 2021  
<http://www.ajnr.org/content/early/2021/04/22/ajnr.A7133>

# Carotid Intraplaque Hemorrhage and Stenosis: At What Stage of Plaque Progression Does Intraplaque Hemorrhage Occur, and When is It Most Likely to Be Associated with Symptoms?

 A.S. Larson,  W. Brinjikji,  L. Savastano,  A.A. Rabinstein,  L. Saba,  J. Huston, and  J.C. Benson

## ABSTRACT

**BACKGROUND AND PURPOSE:** The relationship between carotid intraplaque hemorrhage and luminal stenosis severity is not well-established. We sought to determine whether intraplaque hemorrhage is related to carotid stenosis and at what degree of stenosis intraplaque hemorrhage most likely contributes to ischemic symptoms.

**MATERIALS AND METHODS:** Consecutive patients who underwent MR carotid plaque imaging with MPRAGE sequences to identify intraplaque hemorrhage were retrospectively reviewed. Degrees of stenoses were categorized as minimal (<30%), moderate (30%–69%), and severe (>70%). Arteries were categorized into 2 groups: symptomatic (ipsilateral to a cerebral ischemic event) and asymptomatic (from a patient without an ischemic event). Multiple regression analyses were used to determine independent associations between the degree of stenosis and intraplaque hemorrhage and the presence of intraplaque hemorrhage with symptoms among categories of stenosis.

**RESULTS:** We included 449 patients with 449 carotid arteries: Two hundred twenty-five (50.1%) were symptomatic, and 224 (49.9%) were asymptomatic. An increasing degree of stenosis was independently associated with the presence of intraplaque hemorrhage (OR = 1.02; 95% confidence interval, 1.01–1.03). Intraplaque hemorrhage was independently associated with ischemic events in arteries with <30% stenosis (OR = 5.68; 95% CI, 1.49–21.69). No such association was observed in arteries with >30% stenosis. Of symptomatic arteries with minimal stenosis, 8.7% had intraplaque hemorrhage versus 1.7% of asymptomatic arteries ( $P = .02$ ). No differences in intraplaque hemorrhage prevalence were found between symptomatic and asymptomatic groups with moderate ( $P = .18$ ) and severe stenoses ( $P = .99$ ).

**CONCLUSIONS:** The presence of intraplaque hemorrhage on high-resolution plaque imaging is likely most useful in identifying symptomatic plaques in cases of minimal stenosis.

**ABBREVIATION:** IPH = intraplaque hemorrhage

Carotid artery disease is a well-known risk factor for cerebral ischemic events such as stroke, transient ischemic attack, and retinal ischemia. It has been estimated that 18%–25% of all strokes result from carotid artery atherosclerotic disease.<sup>1</sup> Conventional features of carotid atherosclerosis, such as the degree of luminal stenosis and surface irregularities, have been used as predictors of ischemic events.<sup>2–4</sup> The severity of luminal narrowing, specifically, has long served a central role in determining whether medical or surgical intervention is indicated to treat such lesions.<sup>5–7</sup> However,

in recent years, attention has been drawn to strokes in patients with mild or moderate carotid artery stenosis, calling into question the reliance on luminal stenosis as the primary prognosticator for ischemic events.<sup>8,9</sup> Instead, interest has turned to the morphologic characteristics of plaques, with the presumption that identifiable vulnerable features may provide crucial information regarding the stability of a plaque.<sup>10,11</sup>

The advent of high-resolution MR plaque imaging has enabled the detection of various carotid plaque components, including intraplaque hemorrhage (IPH), lipid-rich necrotic core, and various plaque characteristics, including neovascularization and inflammation.<sup>12</sup> Of these, IPH is a particularly well-documented risk factor for stroke.<sup>13–15</sup> Prior studies have found patients with carotid IPH to be at increased risk of thromboembolic events in the context of both mild-to-moderate<sup>13,16,17</sup> and severe arterial stenosis.<sup>15</sup> Nevertheless, the degree of stenosis at which IPH is likely to

Received June 23, 2020; accepted after revision February 8, 2021.

From the Departments of Radiology (A.S.L., W.B., J.H., J.C.B.), Neurosurgery (A.S.L., W.B., L. Savastano), and Neurology (A.A.R.), Mayo Clinic, Rochester, Minnesota; and Department of Radiology (L. Saba), University of Cagliari, Cagliari, Italy.

Please address correspondence to Anthony Larson, BS, Mayo Clinic Department of Radiology, 200 First St SW, Rochester, MN 55905; e-mail: lars4689@umn.edu; @TonyLarsonBS; @WBrinjikji; @SavastanoPh

<http://dx.doi.org/10.3174/ajnr.A7133>

contribute most to ischemic symptoms remains largely uncertain. This information would provide clinicians with the ability to identify symptomatic IPHs that are likely contributing to ischemic events.

The objective of this study was to determine the relationship between IPH and the degree of carotid stenosis by answering following questions: 1) Are increasing degrees of stenosis independently associated with the presence of IPH, and 2) does the prevalence of IPH vary across categories of luminal stenosis? Furthermore, we also sought to determine whether carotid IPH was independently associated with ipsilateral ischemic events among varying degrees of luminal stenosis and to compare the prevalence of IPH between symptomatic and asymptomatic arteries on the basis of the degree of stenosis.

## **MATERIALS AND METHODS**

### ***Study Population and Patient Groups***

This was a cross-sectional, retrospective study. Mayo Clinic Institutional review board approval was obtained before the initiation of this study. All patients provided written informed consent for participation in research activities at our institution. All patients from our institution who had a neck MRA with high-resolution carotid vessel wall imaging with MPRAGE sequences from 2015 to 2020 were retrospectively reviewed. Patients were excluded for the following reasons: 1) The MRA protocol did not include MPRAGE sequences, 2) acquired images were of poor quality and/or substantially degraded by artifacts (eg, motion), and 3) radiology reports were incomplete (ie, did not comment on the presence of atherosclerotic plaque) or were unavailable.

All patients underwent an initial evaluation by a staff neurologist, cardiologist, or neurosurgeon at our institution. Neck MRAs with MPRAGE sequences were performed within 6 weeks after an initial evaluation. This evaluation included an assessment for clinical signs of cerebral ischemic events including stroke or TIA as well as any ischemic ophthalmologic events, including retinal artery occlusion or amaurosis fugax. In cases in which patients were found to have an ischemic event (as described below), an assessment for potential cardioembolic sources was pursued with an electrocardiogram, telemetry monitoring, echocardiogram, and Holter monitoring.

Next, patients were first categorized into 2 groups: symptomatic and asymptomatic. Symptomatic patients were defined as those having one of the following unilateral anterior circulation ischemic events: ischemic stroke diagnosed with either MR imaging or CT perfusion studies, TIA as diagnosed by a neurologist, ophthalmologically diagnosed central or branch retinal artery occlusion, or amaurosis fugax as diagnosed by a neurologist or ophthalmologist. Patients with posterior circulation strokes and bilateral anterior circulation strokes were excluded from analysis. Patients with a documented history of atrial fibrillation were excluded from the symptomatic group. Asymptomatic patients were those without a history of one of the preceding ischemic events. Most asymptomatic patients underwent neck MRA for symptoms thought to possibly be related to carotid artery pathology but were ultimately not diagnosed with ischemic stroke, TIA, retinal artery occlusion, or amaurosis fugax. Other indications for neck MRA in asymptomatic patients included follow-up for connective tissue diseases (Ehlers-

Danlos syndrome, Marfan syndrome, and so forth), a history of neoplasm of the neck, fibromuscular dysplasia, or dissection. Patients with connective tissue diseases underwent neck MRAs with MPRAGE sequences at our institution to more thoroughly assess any potential carotid vessel wall abnormalities.

To determine the potential association between carotid stenosis and IPH with ischemic events, we analyzed carotid arteries from each patient group on a per-artery basis. In symptomatic patients, only the artery located ipsilateral to the anterior circulation ischemic event was considered. In asymptomatic patients, the carotid artery with the highest degree of stenosis was selected for analysis. In cases of asymptomatic patients with equivalent degrees of stenosis in each carotid artery (including those without any stenosis at all), an artery was randomly selected using the RANDBETWEEN function in Excel (Microsoft), in which each patient was assigned a number at random (0 or 1). The right carotid artery was used in patients who were assigned a value of 0, and the left was used in patients assigned a value of 1.

### ***MR Imaging Protocol***

Neck MR imaging was performed similar to a previously reported protocol.<sup>18</sup> Carotid vessel wall imaging was performed on a 3T MR imaging scanner (750; GE Healthcare) using a 16-channel head/neck/spine coil and included 3 sequences: 1) 2D TOF; 2) 3D inversion recovery fast-spoiled gradient recalled imaging acquired in the coronal plane; and 3) gadolinium bolus carotid MR imaging acquired in the coronal plane. A 3D MPRAGE sequence was used as previously described.<sup>19</sup> The parameters were the following: TR/TE = 13.2/3.2 ms, flip angle = 15°, in-plane spatial resolution = 0.63 × 0.63 mm, reconstructed resolution = 0.31 × 0.31 mm, section thickness = 1 mm, number of excitations = 2, TI = 304 ms, TR with respect to the nonselective inversion = 568 ms, acquisition time = 3 minutes 50 seconds.

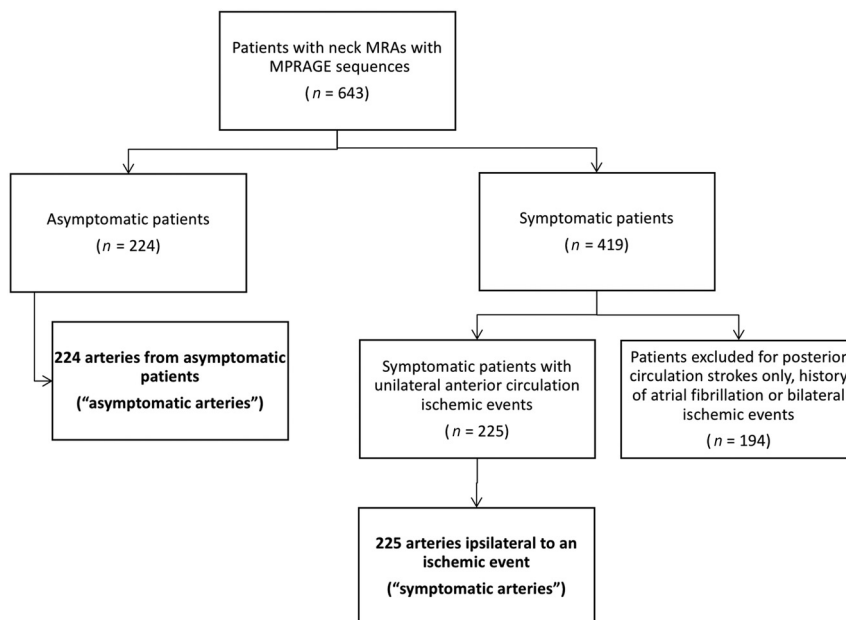
### ***MR Imaging Review Criteria***

Data relating to neck MRAs were abstracted from the original radiology reports. Reports were made by multiple neuroradiologists from our institution who were blinded to the research question, but not to the clinical scenario. Carotid arteries were assessed for the presence and laterality of atherosclerotic plaques, the presence or absence of IPH, and the degree of carotid stenosis. Atherosclerotic plaque was identified on the basis of the presence of circumferential or eccentric wall thickening. Intraplaque hemorrhage was defined as being hyperintense on MPRAGE, with intralesional signal intensity >150% of the ipsilateral sternocleidomastoid muscle. The degree of carotid stenosis was calculated on the basis of the NASCET criteria and was categorized as minimal (<30%), moderate (30%–69%), or severe (>70%).<sup>5</sup>

### ***Statistical Analysis***

To determine whether the degree of carotid stenosis was independently associated with the presence of IPH, we performed multiple regression analysis that used several vascular risk factors as independent variables in addition to the degree of ipsilateral luminal stenosis. The outcome variable was the presence or absence of IPH.

To elucidate any potential independent associations with ischemic events, we performed 3 separate multiple logistic regression



**FIGURE.** Patient- and artery-selection process.

**Table 1: Patient characteristics<sup>a</sup>**

	Overall	Symptomatic	Asymptomatic	P Value
Total patients included	449	225	224	
Total arteries included	449	225	224	
Mean age (SD) (yr)	66.4 (16.3)	67.2 (13.1)	65.6 (18.9)	.30
Male (No.) (%)	245 (54.6)	150 (66.7)	95 (42.4)	<.0001
Comorbidities				
Coronary artery disease (No.) (%)	110 (24.5)	69 (30.7)	41 (18.3)	.003
Hypertension (No.) (%)	269 (59.9)	154 (68.4)	115 (51.3)	.0002
Hyperlipidemia (No.) (%)	287 (63.9)	177 (78.7)	110 (49.1)	<.0001
Diabetes mellitus (No.) (%)	82 (18.3)	56 (28.9)	26 (11.6)	.0003
Peripheral artery disease (No.) (%)	29 (6.5)	17 (7.6)	12 (5.4)	.44
Obstructive sleep apnea (No.) (%)	85 (18.9)	17 (7.6)	12 (5.4)	.44
Ever smoker (No.) (%)	203 (45.2)	125 (55.6)	78 (34.8)	<.0001
Current smoker (No.) (%)	45 (10.0)	29 (12.9)	16 (7.1)	.06
Mean body mass index (SD)	28.3 (5.3)	28.5 (4.8)	28.1 (5.7)	.39
Imaging characteristics				
Arteries without presence of atherosclerotic plaque <sup>b</sup> (No.) (%)	202 (45.0)	47 (20.9)	155 (69.2)	<.0001
Mean degree of stenosis <sup>c</sup> (SD)	23.8 (33.6)	33.5 (35.2)	14.0 (28.8)	<.0001
Presence of IPH <sup>d</sup> (No.) (%)	71 (15.8)	55 (24.4)	16 (7.1)	<.0001

<sup>a</sup>P values pertain to the differences in values between asymptomatic and symptomatic groups.

<sup>b</sup>As mentioned by radiology reports.

<sup>c</sup>Degrees of stenosis were based on NASCET criteria.<sup>5</sup>

<sup>d</sup>Intraplaque hemorrhage was defined as being hyperintense on MPRAGE with intraslesional signal intensity of >150% of the ipsilateral sternocleidomastoid muscle.

analyses in which arteries were stratified by the following degrees of ipsilateral stenosis: <30%, 30%–69% stenosis, and >70%. Input variables were those that differed between symptomatic and asymptomatic patients, with a *P* value of  $\leq .30$  on univariate analysis. The outcome variable was a unilateral anterior circulation ischemic event as described above. The prevalence of IPH in each category of luminal stenosis was calculated for all patients included, as well as symptomatic and asymptomatic patients separately.

Means (SDs) were calculated for continuous variables including age and body mass index. Percentages were calculated for binary variables including sex, comorbidities, the prevalence of ischemic symptoms, the prevalence of each degree of carotid stenosis, and the prevalence of IPH. Each of the aforementioned descriptive statistics was calculated in Excel. The Fisher exact probability test was used to determine the significance among categorical baseline variables between asymptomatic and symptomatic patients and to determine the difference in prevalence of IPH in each category of stenosis between symptomatic and asymptomatic patients. The Student 2-tailed *t* test was used to determine significance among continuous variables. Any *P* values < .05 were considered statistically significant. Each of the aforementioned statistical tests was calculated using STATA statistical software, Version 14.1 (StataCorp).

## RESULTS

### Patients

Our patient and artery-selection process is outlined in the [Figure](#). The final patient cohort comprised 449 patients, yielding 449 carotid arteries. There were 224 asymptomatic patients (49.9%) and 225 symptomatic patients (50.1%). Accordingly, there were 224 asymptomatic carotid arteries (49.9%), and 225 symptomatic arteries (50.1%).

Baseline data from symptomatic and asymptomatic patients are summarized in [Table 1](#). The mean age of all included patients was 66.4 (SD, 16.3) years, and 245 (54.6%) were men.

Regarding ischemic symptoms, 171 of 225 patients (76.0%) were diagnosed with an ischemic stroke; 69 (30.7%), with a TIA; 16 (7.1%), with retinal artery occlusion; and 20 (8.9%), with amaurosis fugax (these numbers

do not add up to 100% because multiple patients had multiple events).

### Intraplaque Hemorrhage and Degree of Stenosis

Increasing degrees of carotid stenosis were independently associated with the presence of ipsilateral IPH (OR = 1.02; 95% CI, 1.01–1.03). Other variables that were independently associated with carotid IPH were male sex (OR = 2.7; 95% CI, 1.43–5.04)

and hyperlipidemia (OR = 4.03; 95% CI, 1.58–10.32). These data are further summarized in Table 2.

On stratified multiple regression analysis, ipsilateral carotid IPH was found to be independently associated with ipsilateral anterior circulation ischemic events in arteries that had <30% stenosis (OR = 5.68; 95% CI, 1.49–21.69). This association was not observed in arteries with 30%–69% or >70% stenosis. In arteries with <30% stenosis, male sex (OR = 1.92, 95% CI, 1.12–3.32), and hyperlipidemia (OR = 2.1; 95% CI, 1.17–3.79) were also found to be independently associated with ischemic events. These data are summarized in Table 3.

The prevalence of IPH in the setting of varying degrees of carotid stenosis is summarized in Table 4. Intraplaque hemorrhage was identified in 71 arteries in total (15.8%), 55 of which (77.5%) were ipsilateral to an ischemic event; 8.7% of symptomatic arteries with minimal (<30%) stenosis had IPH, compared with 1.7% of asymptomatic arteries with minimal stenosis ( $P = .02$ ).

**Table 2: Multiple regression analysis to determine independent associations with the presence of carotid intraplaque hemorrhage<sup>a</sup>**

Variable	OR (95% CI)
Ipsilateral stenosis	1.02 (1.01–1.03)
Male sex	2.70 (1.43–5.04)
Coronary artery disease	1.24 (0.68–2.25)
Hypertension	1.21 (0.61–2.42)
Hyperlipidemia	4.03 (1.58–10.32)
Diabetes mellitus	0.89 (0.47–1.70)
Current smoker	1.16 (0.47–2.83)
Ever smoker	1.06 (0.58–1.94)

<sup>a</sup> All independent variables are listed in the table. The outcome variable was the presence or absence of carotid intraplaque hemorrhage.

**Table 3: Stratified multiple regression analyses to determine independent associations with the presence of an anterior circulation ischemic event<sup>a</sup>**

Variable	OR (95% CI)		
	<30% Stenosis	30%–69% Stenosis	>70% Stenosis
Ipsilateral IPH	5.68 (1.49–21.69)	2.38 (0.67–8.43)	0.95 (0.32–2.80)
Age	0.99 (0.97–1.0)	0.99 (0.95–1.03)	1.02 (0.98–1.06)
Male sex	1.92 (1.12–3.32)	1.64 (0.46–5.90)	2.04 (0.69–6.06)
Coronary artery disease	0.74 (0.33–1.66)	0.75 (0.24–2.35)	0.68 (0.21–2.19)
Hypertension	0.93 (0.50–1.70)	0.93 (0.09–2.95)	0.82 (0.20–3.35)
Hyperlipidemia	2.10 (1.17–3.79)	0.57 (0.05–6.45)	1.25 (0.26–6.02)
Diabetes mellitus	1.51 (0.66–3.49)	1.56 (0.43–5.92)	2.34 (0.59–9.24)
Current smoker	1.68 (0.66–4.28)	1.82 (1.68–19.83)	1.07 (0.25–4.53)
Ever smoker	1.59 (0.87–2.91)	1.33 (0.41–4.41)	0.65 (0.17–2.43)

<sup>a</sup> All independent variables are listed in the table.

**Table 4: Degree of carotid artery stenosis and prevalence of intraplaque hemorrhage in asymptomatic-versus-symptomatic arteries<sup>a</sup>**

Degree of Stenosis <sup>c</sup>	Prevalence of Intraplaque Hemorrhage <sup>b</sup> (%)			P Value
	All (n = 449 Total)	Asymptomatic (n = 224 Total)	Symptomatic (n = 225 Total)	
<30% (n = 295 total)	13/295 (4.4)	3/180 (1.7)	10/115 (8.7)	.02
30%–69% (n = 79 total)	33/79 (41.8)	5/19 (26.3)	28/60 (46.7)	.18
70%+ (n = 75 total)	25/75 (33.3)	8/25 (32.0)	17/50 (34.0)	.99

<sup>a</sup> P values pertain to the difference in the prevalence of IPH between asymptomatic and symptomatic groups and were calculated using the Fisher exact test. Data are number of arteries per group with intraplaque hemorrhage.

<sup>b</sup> Intraplaque hemorrhage was defined as being hyperintense on MPRAGE with intraslesional signal intensity of >150% of the ipsilateral sternocleidomastoid muscle.

<sup>c</sup> Degrees of stenosis were based on the NASCET criteria.<sup>5</sup>

Symptomatic arteries with moderate stenosis (30%–69%) had an IPH prevalence of 46.7%, compared with a prevalence of 26.3% in the asymptomatic group, though this finding did not reach statistical significance ( $P = .18$ ). In arteries with severe (>70%) stenosis, there was no difference in the prevalence of IPH between symptomatic (34.0%) and asymptomatic groups (32.0%,  $P = .99$ ).

## DISCUSSION

The current study has 2 primary findings: First, increasing degrees of carotid stenosis were found to be independently associated with the presence of IPH. This finding corresponds to a higher prevalence of IPH that was observed in all arteries with >30% stenosis compared with arteries with <30% stenosis. Second, ipsilateral IPH was independently associated with symptoms in carotid arteries with <30% stenosis, a finding that was accompanied by a higher prevalence of IPH in symptomatic-versus-asymptomatic patients with ipsilateral stenosis of <30%. Such findings were not observed for arteries with >30% stenosis. Taken together, these results suggest that first, carotid IPH is more likely to be observed in arteries with increasing degrees of luminal stenosis. However, the presence of IPH may be less useful in differentiating symptomatic from asymptomatic plaques in the context of greater degrees of luminal stenosis: IPH is likely most useful in distinguishing between symptomatic and asymptomatic plaques in cases of <30% stenosis. However, large differences were evident in the number of arteries between each degree of stenosis. For example, there were 295 total arteries in the <30% category, while only 154 arteries made up the total of the remaining categories. These smaller sample sizes in arteries with greater degrees of stenosis may have precluded statistical significance from being reached.

Already, IPH is a known risk factor for symptomatic ischemic events in the context of less severe degrees of carotid stenosis. Altaf et al<sup>13</sup> performed a longitudinal prospective study involving a total of 64 symptomatic patients with 30%–69% carotid artery stenosis during a mean follow-up period of 28 months. Fourteen ipsilateral ischemic events were noted on follow-up, 13 of which occurred in patients found to have ipsilateral IPH. Similarly, Singh et al<sup>16</sup> reported a case-control study in which 36 of 98 carotid arteries with 50%–70% stenosis had IPH (75 patients in total). At a minimum follow-up of 1 year, 6 ipsilateral ischemic events occurred in patients with IPH, and no events occurred in patients without evidence of IPH.

The results of this study have a rationale based on the expected histopathologic progression of most plaques. IPH represents a well-described vulnerable feature of atherosclerotic plaques and is associated with a sudden increase in plaque size, thrombosis, and



embolism. Such changes in the setting of nonsevere stenoses might be expected to contribute to symptoms in previously asymptomatic lesions. Plaques resulting in severe stenosis but without IPH, conversely, are often symptomatic likely due to the presence of additional vulnerable characteristics such as increased plaque volume, lipid-rich necrotic core, neovascularization, or inflammation. Hence, it stands to reason that IPH has a larger impact on the development of neurologic symptoms in less severe plaques. Thus, dedicated MR plaque imaging in symptomatic patients with milder stenoses may be particularly useful.

Because IPH was found to be prevalent in a wide range of luminal stenoses, the results of this study provide imaging evidence that plaques of higher histologic grades (and therefore increased vulnerability) do not always exist exclusively in the context of higher degrees of luminal stenosis. Such findings are consistent with several prior reports that have demonstrated the imaging evidence of IPH across the spectrum of carotid stenoses.<sup>13,15,16</sup> This phenomenon is further supported by histologic evidence. A postmortem histopathologic study of specimens with carotid artery disease by Svindland and Torvik<sup>20</sup> noted the presence of IPH in various degrees of carotid stenosis, ranging from 35% to 88%, and they also found that hemorrhage was more commonly seen in arteries with greater stenosis. Albuquerque et al<sup>21</sup> found IPH to be equally prevalent across varying degrees of stenosis ranging from 50% to >90%. Taken together with the results of the current study, these data indicate that IPH may be present in all severities of carotid artery stenosis. Although MR plaque imaging protocols are likely useful in detecting symptomatic plaques with IPH in cases of less-than-severe stenosis, further study is necessary for confirmation.

The current study is limited in its single-center, retrospective design. It is uncertain how many patients from our institution did not provide informed consent for involvement in research; therefore this potential for selection bias cannot be excluded. It is possible that arteries with minimal atherosclerotic plaque may have been excluded from the study on the basis of radiology reports because this may not have been commented on by the reading radiologist. Other, noncarotid sources of cerebral ischemia were not explicitly ruled out in each symptomatic patient, though this potential confounding factor was mitigated by excluding patients with atrial fibrillation. Most cases of IPH were detected within 4 weeks of the ischemic event; however, we did not control for the timeframe of IPH detection relative to the ischemic event in each case, nor was the age of the IPH considered. Prior studies have implied that IPH signals may persist for up to 24 months.<sup>22</sup> It is, therefore, uncertain how the age and evolution of IPH may contribute to ischemic symptoms, and further study is required to address these issues. We used a definition of carotid IPH as being a hyperintensity that is >150% of the adjacent musculature in accordance with prior reports.<sup>13,16</sup> However, other studies have used a hyperintensity threshold of 200%, which may increase the specificity of carotid IPH detection.<sup>23</sup> In this study, IPH and carotid stenosis were the sole plaque features that were evaluated, and other important plaque features such as ulceration, cap thickness, or the presence of a lipid-rich necrotic core were not evaluated, all of which may play confounding roles. Future studies may also consider the size of the plaque because larger plaques are likely at higher risk of developing IPH.

## CONCLUSIONS

Carotid artery IPH is independently associated with the degree of arterial stenosis. Carotid IPH is also independently associated with the presence of ipsilateral symptoms in cases of minimal arterial stenosis. Symptomatic carotid arteries with minimal stenosis also tended to have a higher prevalence of IPH compared with asymptomatic arteries. The presence of IPH on high-resolution plaque imaging is likely most useful in identifying symptomatic plaques in cases of minimal stenosis. However, carotid artery IPH was observed in all degrees of luminal stenosis. High-resolution carotid plaque imaging should, therefore, be considered in patients with suspected carotid artery atherosclerosis regardless of the degree of stenosis.

Disclosures: Alejandro Rabinstein—UNRELATED: Royalties: Elsevier, Wolters Kluwer, Springer; Payment for Development of Educational Presentations: Univadis, Medscape; Other: adverse event adjudicator, Comments: for trials funded by Boston Scientific and Boehringer Ingelheim.

## REFERENCES

- Ooi YC, Gonzalez NR. Management of extracranial carotid artery disease. *Cardiol Clin* 2015;33:1–35 [CrossRef Medline](#)
- Troyer A, Saloner D, Pan XM, et al. Assessment of Carotid Stenosis by Comparison with Endarterectomy Plaque Trial Investigators. Major carotid plaque surface irregularities correlate with neurologic symptoms. *J Vasc Surg* 2002;35:741–47 [CrossRef Medline](#)
- Prabhakaran S, Rundek T, Ramas R, et al. Carotid plaque surface irregularity predicts ischemic stroke: the Northern Manhattan Study. *Stroke* 2006;37:2696–2701 [CrossRef Medline](#)
- Autret A, Pourcelot L, Saudeau D, et al. Stroke risk in patients with carotid stenosis. *Lancet* 1987;1:888–90 [CrossRef Medline](#)
- Barnett HJ, Taylor DW, Haynes RB, et al. North American Symptomatic Carotid Endarterectomy Trial Collaborators. Beneficial effect of carotid endarterectomy in symptomatic patients with high-grade carotid stenosis. *N Engl J Med* 1991;325:445–53 [CrossRef Medline](#)
- Endarterectomy for asymptomatic carotid artery stenosis: Executive Committee for the Asymptomatic Carotid Atherosclerosis Study. *JAMA* 1995;273:1421–28 [Medline](#)
- MRC European Carotid Surgery Trial: interim results for symptomatic patients with severe (70–99%) or with mild (0–29%) carotid stenosis—European Carotid Surgery Trialists' Collaborative Group. *Lancet* 1991;337:1235–43 [Medline](#)
- Freilinger TM, Schindler A, Schmidt C, et al. Prevalence of nonstenosing, complicated atherosclerotic plaques in cryptogenic stroke. *JACC Cardiovasc Imaging* 2012;5:397–405 [CrossRef Medline](#)
- Wasserman BA, Wityk RJ, Trout HH 3rd, et al. Low-grade carotid stenosis: looking beyond the lumen with MRI. *Stroke* 2005;36:2504–13 [CrossRef Medline](#)
- Lovett JK, Gallagher PJ, Hands LJ, et al. Histological correlates of carotid plaque surface morphology on lumen contrast imaging. *Circulation* 2004;110:2190–97 [CrossRef Medline](#)
- Lovett JK, Gallagher PJ, Rothwell PM. Reproducibility of histological assessment of carotid plaque: implications for studies of carotid imaging. *Cerebrovasc Dis* 2004;18:117–23 [CrossRef Medline](#)
- Saba L, Yuan C, Hatsukami TS, et al. Vessel Wall Imaging Study Group of the American Society of Neuroradiology. Carotid Artery Wall Imaging: Perspective and Guidelines from the ASNR Vessel Wall Imaging Study Group and Expert Consensus Recommendations of the American Society of Neuroradiology. *AJNR Am J Neuroradiol* 2018;39:E9–31 [CrossRef Medline](#)
- Altaf N, Daniels L, Morgan PS, et al. Detection of intraplaque hemorrhage by magnetic resonance imaging in symptomatic patients with mild to moderate carotid stenosis predicts recurrent neurological events. *J Vasc Surg* 2008;47:337–42 [CrossRef Medline](#)

14. Takaya N, Yuan C, Chu B, et al. Association between carotid plaque characteristics and subsequent ischemic cerebrovascular events: a prospective assessment with MRI—initial results. *Stroke* 2006;37:818–23 [CrossRef Medline](#)
15. Altaf N, MacSweeney ST, Gladman J, et al. Carotid intraplaque hemorrhage predicts recurrent symptoms in patients with high-grade carotid stenosis. *Stroke* 2007;38:1633–35 [CrossRef Medline](#)
16. Singh N, Moody AR, Gladstone DJ, et al. Moderate carotid artery stenosis: MR imaging-depicted intraplaque hemorrhage predicts risk of cerebrovascular ischemic events in asymptomatic men. *Radiology* 2009;252:502–08 [CrossRef Medline](#)
17. Schindler A, Schinner R, Altaf N, et al. Prediction of stroke risk by detection of hemorrhage in carotid plaques: meta-analysis of individual patient data. *JACC Cardiovasc Imaging* 2020;13:395–406 [CrossRef Medline](#)
18. Brinjikji W, DeMarco JK, Shih R, et al. Diagnostic accuracy of a clinical carotid plaque MR protocol using a neurovascular coil compared to a surface coil protocol. *J Magn Reson Imaging* 2018;48:1264–72 [CrossRef Medline](#)
19. Zhu DC, Ferguson MS, DeMarco JK. An optimized 3D inversion recovery prepared fast spoiled gradient recalled sequence for carotid plaque hemorrhage imaging at 3.0 T. *Magn Reson Imaging* 2008;26:1360–66 [CrossRef Medline](#)
20. Svindland A, Torvik A. Atherosclerotic carotid disease in asymptomatic individuals: an histological study of 53 cases. *Acta Neurol Scand* 1988;78:506–17 [CrossRef Medline](#)
21. Albuquerque LC, Narvaes LB, Maciel AA, et al. Intraplaque hemorrhage assessed by high-resolution magnetic resonance imaging and C-reactive protein in carotid atherosclerosis. *J Vasc Surg* 2007;46:1130–37 [CrossRef Medline](#)
22. Simpson R, Akwei S, Hosseini A, et al. MR imaging-detected carotid plaque hemorrhage is stable for 2 years and a marker for stenosis progression. *AJNR Am J Neuroradiol* 2015;36:1171–75 [CrossRef Medline](#)
23. McNally JS, McLaughlin MS, Hinckley PJ, et al. Intraluminal thrombus, intraplaque hemorrhage, plaque thickness, and current smoking optimally predict carotid stroke. *Stroke* 2015;46:84–90 [CrossRef Medline](#)