



Providing Choice & Value
Generic CT and MRI Contrast Agents

**FRESENIUS
KABI**

CONTACT REP

AJNR

**Centripetal Propagation of Vasoconstriction
at the Time of Headache Resolution in
Patients with Reversible Cerebral
Vasoconstriction Syndrome**

M. Shimoda, S. Oda, A. Hirayama, M. Imai, F. Komatsu, K.
Hoshikawa, H. Shigematsu, J. Nishiyama and T. Osada

This information is current as
of July 7, 2025.

AJNR Am J Neuroradiol published online 14 April 2016
<http://www.ajnr.org/content/early/2016/04/14/ajnr.A4768>

Centripetal Propagation of Vasoconstriction at the Time of Headache Resolution in Patients with Reversible Cerebral Vasoconstriction Syndrome

 M. Shimoda,  S. Oda,  A. Hirayama,  M. Imai,  F. Komatsu,  K. Hoshikawa,  H. Shigematsu,  J. Nishiyama, and  T. Osada



ABSTRACT

BACKGROUND AND PURPOSE: Reversible cerebral vasoconstriction syndrome is characterized by thunderclap headache and diffuse segmental vasoconstriction that resolves spontaneously within 3 months. Previous reports have proposed that vasoconstriction first involves small distal arteries and then progresses toward major vessels at the time of thunderclap headache remission. The purpose of this study was to confirm centripetal propagation of vasoconstriction on MRA at the time of thunderclap headache remission compared with MRA at the time of reversible cerebral vasoconstriction syndrome onset.

MATERIALS AND METHODS: Of the 39 patients diagnosed with reversible cerebral vasoconstriction syndrome at our hospital during the study period, participants comprised the 16 patients who underwent MR imaging, including MRA, within 72 hours of reversible cerebral vasoconstriction syndrome onset (initial MRA) and within 48 hours of thunderclap headache remission.

RESULTS: In 14 of the 16 patients (87.5%), centripetal propagation of vasoconstriction occurred from the initial MRA to remission of thunderclap headache, with typical segmental vasoconstriction of major vessels. These mainly involved the M1 portion of the MCA (10 cases), P1 portion of the posterior cerebral artery (10 cases), and A1 portion of the anterior cerebral artery (5 cases).

CONCLUSIONS: This study found evidence of centripetal propagation of vasoconstriction on MRA obtained at the time of thunderclap headache remission, compared with MRA obtained at the time of reversible cerebral vasoconstriction syndrome onset. If clinicians remain unsure of the diagnosis during early-stage reversible cerebral vasoconstriction syndrome, this time point represents the best opportunity to diagnose reversible cerebral vasoconstriction syndrome with confidence.

ABBREVIATIONS: RCVS = reversible cerebral vasoconstriction syndrome; TCH = thunderclap headache

Reversible cerebral vasoconstriction syndrome (RCVS) is characterized by thunderclap headache (TCH) and diffuse segmental constriction of cerebral arteries that resolves spontaneously within 3 months.^{1,2} RCVS can be spontaneous or evoked by various factors such as postpartum status, vasoactive drugs, catecholamine-secreting tumors, immunosuppressants, or blood products.^{3,4} RCVS is poorly understood and has recently been estimated to be more common than previously thought.² Unpredictable and transient failure of the regulation of cerebral arterial

tone through sympathetic overactivity is thought to play a role in the development of RCVS.^{1,5}


TCH is usually the first symptom of RCVS, and typically recurs for 1–2 weeks after onset.^{3–5} The final TCH occurs at a mean of 7–8 days after onset, and all noteworthy headaches are generally gone within 3 weeks after onset.^{4,6,7} Conventional DSA was crucial to the diagnosis of RCVS in early case reports and typically showed diffuse segmental vasoconstrictions involving major vessels, like a “string of beads” or “string of sausages.”⁴ More recently, MRA has been widely used as a noninferior tool to evaluate vasoconstriction in patients with RCVS.^{3,4,6} Findings of typical segmental vasoconstriction of major vessels are not obtained in about one-third of patients with RCVS if the initial MRA is performed within 10 days of headache onset.^{4,6,8} Ducros et al^{4,9} postulated that the arterial abnormalities first involve small distal arteries and then progress toward major vessels.

This study retrospectively investigated whether centripetal propagation of vasoconstriction on MRA at the time of TCH re-

Received September 30, 2015; accepted after revision February 5, 2016.

From the Department of Neurosurgery (M.S., S.O., A.H., M.I., F.K., K.H.), Tokai University Hachioji Hospital, Tokyo, Japan; and Department of Neurosurgery (H.S., J.N., T.O.), Tokai University School of Medicine, Kanagawa, Japan.

Please address correspondence to Masami Shimoda, MD, Department of Neurosurgery, Tokai University Hachioji Hospital, 1838 Ishikawa-machi, Hachioji, Tokyo 192-0032, Japan; e-mail: mashimoda-nsu@umin.ac.jp

 Indicates article with supplemental on-line table.

<http://dx.doi.org/10.3174/ajnr.A4768>

mission was evident compared with MRA at the time of RCVS onset.

MATERIALS AND METHODS

Patient Population

Patients diagnosed with RCVS in Tokai University Hachioji Hospital according to the following 5 criteria for RCVS were included in our data base: 1) acute and severe headache (often TCH) with or without focal deficits or seizures; 2) a uniphasic course without any new symptoms >1 month after clinical onset; 3) segmental, multifocal vasoconstriction of cerebral arteries as shown by DSA or indirect angiography (eg, MRA or 3D CTA); 4) no evidence of aneurysmal SAH; and 5) complete or substantial normalization of arteries on follow-up DSA or indirect angiography performed within 12 weeks after clinical onset.^{2,4} CSF analysis was not routinely performed on patients in this study.

Subjects were selected from among the 39 patients entered into the RCVS data base at Tokai University Hachioji Hospital between October 2010 and April 2015. Ten of these patients who did not undergo initial MRA/MR imaging within 72 hours of RCVS onset were excluded because they were admitted in the subacute phase (≥ 3 days after onset). In addition, 13 patients with RCVS who did not undergo MRA/MR imaging within 48 hours of TCH remission were excluded because they did not visit an outpatient clinic at the time of TCH remission (subacute phase) due to their comfortable medical condition. The remaining 16 patients with RCVS who underwent MR imaging within 72 hours of RCVS onset, within 48 hours of remission of TCH, and 3 months after RCVS onset were included in this retrospective study.

Clinical and imaging records were evaluated retrospectively. Study approval was obtained from the Institutional Review Board for Clinical Research at Tokai University School of Medicine.

Imaging Protocol

We differentiated primary angiitis of the central nervous system from RCVS on the basis of an insidious onset, low incidence of TCH, mostly irreversible angiographic irregularities, and inflammatory reactions evident in the CSF.^{2,10} At all time points, serial MR imaging included axial conventional T1WI, FLAIR images, DWI, and MRA, all performed by using a 1.5T superconducting magnet (Signa Excite or HDX; GE Healthcare, Milwaukee, Wisconsin) with a quadrature head coil. Pulse sequences were as follows: FLAIR (TR/TE, 8000/120 ms; TI, 2000 ms; section thickness/section gap, 7.0/1.0 mm; FOV, 24 × 24 cm; NEX, 1; matrix, 256 × 224), T1WI (TR/TE, 2000/24 ms; TI, 750 ms; section thickness/section gap, 7.0/1.0 mm; FOV, 24 × 24 cm; NEX, 2; matrix, 256 × 192), and 3D TOF MRA (TR/TE, 27/6.8 ms; flip angle, 16°; bandwidth, 14.7 Hz; FOV, 18 × 18 cm; slab thickness, 70 mm; section thickness, 1.2 mm; matrix, 256 × 192; NEX, 1). MR imaging was completed within 13–15 minutes.

Definition of Variables

“TCH” was defined as a severe pain peaking within seconds. The presence of TCH was diagnosed by a thorough interview of the patient. “TCH remission” was defined as the time at which the last TCH improved. “Hypertensive emergency” was defined as sys-

tolic blood pressure of >180 mm Hg or diastolic blood pressure of >120 mm Hg.

“Cortical SAH” was defined as a nontraumatic, nonaneurysmal SAH characterized by clots distributed over the cerebral convexity, sparing the basal cistern.¹¹ In patients with cortical SAH, conventional DSA or 3D CTA or both were routinely performed to rule out other causes of SAH, such as aneurysm or vessel malformation. “Posterior reversible encephalopathy syndrome” was defined as a characteristic MR imaging pattern of vasogenic edema with hemispheric boundary zones of hyperintensities on FLAIR, with increased ADC values affecting the cortex and subcortical and deep white matter to varying degrees.^{2,12}

Localization of vasoconstriction of the cerebral arteries was evaluated on MRA. “Centripetal propagation of vasoconstriction” was defined as a vasoconstriction that progressed from the distal arteries at the time of TCH (ie, on MRA performed within 72 hours of RCVS onset) to the major cerebral arteries of the circle of Willis (defined as the ICA, the A1 portion of the anterior cerebral artery, and/or the P1 portion of the posterior cerebral artery) and the M1 portion of the MCA, basilar artery, and vertebral artery on MRA performed within 48 hours of TCH remission. A “hyperintense vessel sign” was defined as a focal or tubular hyperintensity in the subarachnoid space on FLAIR¹³ that normalized within 12 weeks of clinical onset.

MR imaging findings were interpreted by at least 2 senior stroke neurosurgeons (M.S. and S.O., with 32 and 27 years of experience, respectively). In the case of disagreement between raters, diagnosis was obtained by consensus decision. Outcomes were assessed at 3 months by using the mRS.

Treatment Protocol

Vasoactive medications were stopped in all patients. Symptomatic analgesic treatment was used in all patients without a standard protocol. Oral administration of lomerizine hydrochloride was recommended for prevention of cerebral vasoconstriction. Steroids were avoided. For patients with severe TCH, a low dose of propofol was infused intravenously at 30–50 mg/h. For patients who experienced a hypertensive emergency, nicardipine was used with intravenous infusion of the dose adapted to normalize blood pressure levels.

RESULTS

Clinical Features and Associated Lesions

The On-line Table summarizes the clinical characteristics of the 16 patients with RCVS who underwent MR imaging within 72 hours of RCVS onset and within 48 hours of the remission of TCH. Ten of these 16 patients had a history of migraine before the onset of RCVS, and 3 of these 10 patients experienced an aura. All 10 patients who had a history of migraine stated that their headaches were completely different and more severe than their usual attacks. The 16 patients with RCVS included 2 postpartum women. Six of the 16 patients were using a vasoactive substance such as a selective serotonin reuptake inhibitor or triptans. Overuse of triptan was identified in only 1 case. Two of the 16 patients experienced bathing-related RCVS. Four showed a “blood pressure surge” defined as a hypertensive emergency during the peak of the TCH, and no patients displayed permanently elevated

Location of vasoconstricted vessels on initial MRA and MRA performed at TCH remission

Case	Initial MRA		Duration of TCH (Days)	MRA at TCH Remission	
	Days after Onset	Location of Vasoconstriction		Days after Onset	Location of Vasoconstriction
1	0	L-M2/3, R-P3	10	10	B-M1/2/3, B-P1/2/3, B-VA
2	0	B-M2/3, B-P2/3	8	10	R-A1, B-P1
3	2	B-M2/3, B-P2/3, B-A2/3	9	9	B-A1, B-M1, B-P1, BA
4	0	L-M3, B-P2/3	5	7	L-M1, L-P1/2
5	1	R-P3, L-M2/3	7	7	R-M1, R-P2
6	1	R-M3, B-P2/3	12	12	R-M1, B-A1, B-P1/2, BA
7	0	B-M3, B-P3	4	4	B-M1/2, B-P1/2
8	2	B-M2/3, B-P2/3	20	20	B-P2/3, B-A1/2, B-IC, L-P1, BA
9	0	B-M2/3, B-P2/3	10	10	B-M1, B-P1
10	2	B-P2/3	7	10	L-P1
11	0	B-M3, B-P2/3	5	5	B-M3, B-P1/2
12	0	B-M2/3, B-P2/3	9	9	L-P2
13	1	L-M2/3, B-P2/3	6	7	Improvement
14	0	B-M3	4	4	B-M2, L-M1
15	2	L-M2/3	8	8	L-M1, L-IC
16	0	B-M2/3, B-P2/3	4	4	L-P1

Note:—B indicates bilateral; L, left; R, right; VA, vertebral artery; BA, basilar artery; IC, internal cerebral artery.

blood pressure. The 4 patients with a hypertensive emergency showed vasoconstriction of the distal MCA and posterior cerebral artery on initial MRA.

All patients reported multiple episodes of TCH. Because the clinical records were insufficient, we were unable to investigate the exact number of events of TCH retrospectively. TCH was the only symptom of RCVS in 13 patients (81.2%).

A mean delay of 0.69 days (range, 0–2 days) was seen between RCVS onset and initial MR imaging. In 9 of the 16 patients (56.2%), initial MR imaging was performed on day 0 (ie, within 24 hours of onset). In the remaining 7 patients, initial MR imaging was performed 1–2 days after onset.

Stroke as a complication of RCVS occurred in 6 of the 16 patients (37.5%). Evidence of cortical SAH was found on MR imaging performed on days 0–2 in 5 patients. Conventional angiography, 3D CTA, MR imaging, and MRA revealed no other causes of SAH. No patients had intracerebral hemorrhage or microbleeds on T2*-weighted imaging. One patient developed MCA/posterior cerebral artery watershed infarction on day 0. Evidence of posterior reversible encephalopathy syndrome was found on MR imaging performed on day 2 in 1 patient. Findings of brain lesions on follow-up MR imaging are summarized in the On-line Table.

Hyperintense vessel signs on FLAIR imaging with the initial MR imaging were found in 5 patients. Of these 5 patients, 4 displayed evidence of some kind of stroke lesion on initial MR imaging as a complication of RCVS (On-line Table). Among these 5 patients who showed findings of vessel hyperintensity on initial MR imaging, the findings remained on MR imaging at the time of TCH remission in 2 patients.

Centripetal Propagation of Vasoconstriction

The Table presents the changes in the location of vasoconstricted vessels from the initial MRA to the time of TCH remission. On initial MRA, bilateral vasoconstriction was found in 15 of the 16

patients (93.8%); vasoconstriction of the M2 or M3 portion of the MCA, in 15 patients (93.8%); vasoconstriction of the P2 or P3 portions of the posterior cerebral artery, in 14 patients (87.5%); and vasoconstriction of the A2 or A3 portions of the anterior cerebral artery, in 1 patient. The duration of TCH ranged from 4 to 20 days (mean, 8.0 days) after onset. MRA at the time of TCH remission was performed from 4 to 20 days (mean, 8.5 days) after onset.

On MRA at the time of TCH remission, centripetal propagation of vasoconstriction had occurred in 14 of the 16 cases (87.5%, all except cases 12 and 13), as indicated by the typical segmental vasoconstriction of major vessels. Bilateral centripetal propagation of vasoconstriction occurred in 10 of the 16 patients (62.5%). Centripetal propagation occurred in the M1 portion of the MCA (10 of 16 patients, 62.5%), the P1 por-

tion of the posterior cerebral artery (10 of 16 patients, 62.5%), the A1 portion of the anterior cerebral artery (5 of 16 patients, 31.3%), the basilar artery (2 of 16 patients, 12.5%), and the ICA (2 of 16 patients, 12.5%). Vasoconstriction outlasted headache remission in all except 1 patient (case 13). Figures 1 and 2 present typical MRA findings for the centripetal propagation of vasoconstriction.

Among the 14 patients who showed findings of centripetal propagation of vasoconstriction, vasoconstriction of the distal arteries was consistently improved, but some findings remained in 2 patients (cases 1 and 8) on MRA at the time of TCH remission. Furthermore, these 2 patients displayed persistent hyperintense vessel signs on FLAIR imaging at the time of TCH remission. No patients showed aggravation of the vasoconstriction of the distal arteries on MRA at the time of TCH remission.

Clinical Features of the Chronic Stage

By definition, all 16 patients with RCVS displayed confirmed multifocal vasoconstriction that resolved within 12 weeks, as assessed by MRA. At the 3-month follow-up, the mRS scores of all 16 patients with RCVS were zero, and all patients were able to return to their prior professional activities.

DISCUSSION

Clinical Course and Mechanisms of TCH of RCVS

In patients with RCVS, TCH is the presenting symptom and usually recurs during ~1 week. In general, TCH occurs before any detectable vasoconstriction and vasoconstriction outlasts TCH.⁴ Whereas TCH, cortical SAH, intracerebral hemorrhage, and posterior reversible encephalopathy syndrome represent early manifestations that lead to a suspicion of RCVS, ischemic stroke can occur as late as 1–2 weeks after clinical onset, sometimes when the headache has resolved or after the patient has been discharged.^{3,4,6,7,9}

Dysregulation of cerebral vascular tone is known to result

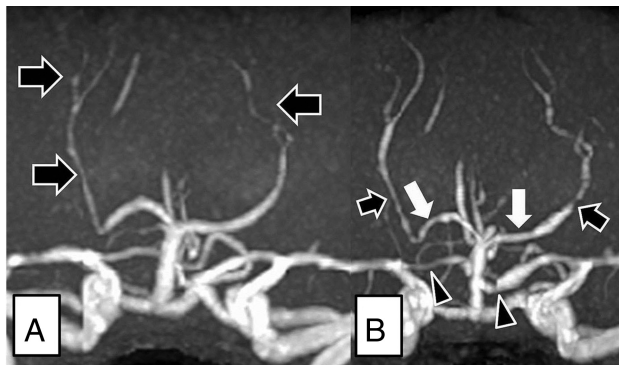


FIG 1. Images from a 28-year-old woman (case 6) with puerperium-related reversible cerebral vasoconstriction syndrome. The patient was admitted to the hospital 1 day after onset. *A*, The initial MRA obtained 1 day after the onset of thunderclap headache shows vasoconstrictions in the bilateral P2–3 portions of the posterior cerebral arteries (black arrows). *B*, MRA obtained at the time of TCH remission (12 days after onset) shows centripetal propagation of vasoconstriction in the bilateral P2 (black arrows) and P1 (white arrows) portions of the posterior cerebral arteries and bilateral A1 portions of the anterior cerebral arteries (black arrowheads).

from sympathetic overactivity, and endothelial dysfunction might be a central element in the pathogenesis of RCVS.^{2,14} Based on the characteristic clinical features of RCVS, Ducros et al⁴ postulated that the differing temporal courses of TCH, vasoconstriction, and stroke suggest that the underlying disturbance in the control of cerebral artery tone first involves small distal arteries responsible for hemorrhages and posterior reversible encephalopathy syndrome and then progresses toward the medium-sized and large arteries responsible for ischemic events. They speculated that at the initial stage of RCVS, sudden alterations in central vascular tone may lead to segmental vasoconstriction and vasodilation in small distal vessels and trigger TCH by abruptly stretching vessel walls, especially in the small distal arteries of the leptomeninges, resulting in stimulation of the trigeminal afferent nerve as a collection of perivascular pain-sensitive fibers.^{2,4,9,14}

Mechanism of Centripetal Propagation of Vasoconstriction in RCVS

Ducros² suggested that vasoconstriction of the second and first segments of large cerebral arteries might represent a reaction to distal blood-flow abnormalities, increasing during the ensuing 1 or 2 weeks. However, the precise mechanisms underlying centripetal propagation of vasoconstriction in RCVS remain unclear.

Centripetal progression of vasoconstriction from the manifestation of recurrent TCH to the remission of headaches has not been precisely delineated by using neuroradiologic imaging modalities such as MRA. Chen et al⁶ showed that vasoconstriction is maximal at TCH remission. However, they did not mention the centripetal propagation of vasoconstriction at TCH remission. Their initial MRA was performed at a mean of 10.4 ± 7.0 days (median, 9 days; range, 1–30 days) after TCH onset. We consider that the lower ratio of patients who underwent initial MRA/MR imaging within 72 hours of RCVS onset would have largely prevented identification of the centripetal propagation of vasoconstriction at TCH remission. Another review by Chen et al¹⁴ described that only a small number of their patients showed cen-

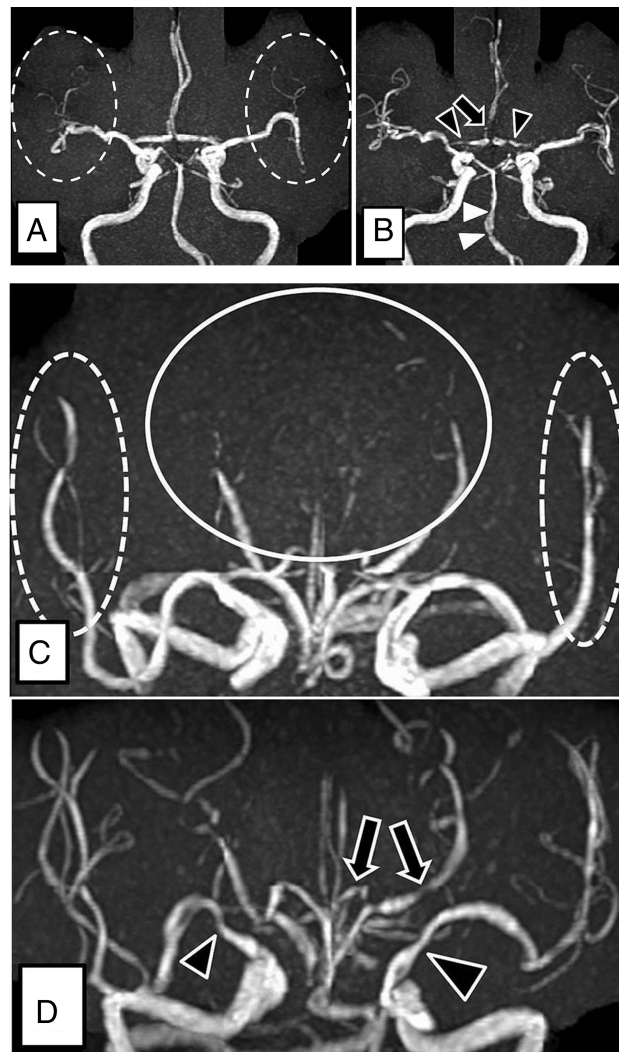


FIG 2. Images from a 60-year-old woman (case 8) with bath-related reversible cerebral vasoconstriction syndrome. The patient was admitted to the hospital 2 days after onset. *A* and *C*, Initial MRA obtained 2 days after onset of thunderclap headache shows vasoconstrictions in the bilateral distal MCAs (dotted circles) and bilateral P2–3 portions of the posterior cerebral arteries (*C*, circle). *B* and *D*, MRA obtained at the time of TCH remission (20 days after onset of TCH) shows centripetal propagation of vasoconstriction in the bilateral A1 portions (*B*, black arrowheads) and A2 portions (*B*, black arrow) of the anterior cerebral artery, bilateral internal cerebral arteries (*D*, black arrowheads), the left P1 portion of the posterior cerebral artery (*D*, black arrows), and the basilar artery (*B*, white arrowheads). Vasoconstriction of the bilateral P2–3 portions was improved, but some findings remained on MRA at the time of TCH remission.

tripetal propagation of vasoconstriction, citing their initial article.⁶

On the other hand, the purpose of this study was to prove centripetal propagation of vasoconstriction on MRA at the time of TCH remission, compared with MRA at the time of RCVS onset. The present investigation showed centripetal propagation of vasoconstriction from RCVS onset to the remission of TCH on MRA in 14 of the 16 patients with RCVS. Although the pathophysiologic mechanisms behind the centripetal propagation of vasoconstriction are unknown, this phenomenon is an important neuroradiologic finding for diagnosis.

Neuroradiologic Diagnosis of RCVS

RCVS should be considered for patients in the acute phase of cortical SAH or cryptogenic stroke with recurrent TCH.⁴ However, in the acute phase of RCVS, clinicians are likely to overlook a diagnosis of RCVS in patients who have no neuroradiologic findings of parenchymal lesions such as posterior reversible encephalopathy syndrome, intracerebral hemorrhage, or SAH on MR imaging because clinicians should diagnose RCVS only from a finding of vasoconstriction on MRA. The diagnosis of RCVS is reportedly missed in one-third of patients who undergo initial MRA within 10 days of headache onset.⁸ The diagnosis of RCVS in the acute phase by using MR imaging remains difficult because the vasoconstricted vessels are located peripherally at this time.

Patients with RCVS are predominantly women 50 years of age or younger. MRA of healthy young individuals usually depicts the MCA, posterior cerebral artery, and anterior cerebral artery branches distal to the circle of Willis and the first branch points of major vessels relatively well. A diagnosis of RCVS should thus be considered in young women reporting TCH if the depiction of peripheral vessels on MRA is poor. Furthermore, at the time of TCH remission, if a clinician confirms centripetal propagation of vasoconstriction with typical segmental vasoconstriction of the circle of Willis vessels, RCVS can be diagnosed with confidence.

Recently, a hyperintense vessel sign on FLAIR images has been reported as one of the neuroradiologic findings of vasoconstriction of a distal artery in the acute phase of RCVS.^{8,15} The hyperintense vessel sign could simply represent slow flow in collateral vessels distal to a proximal narrowing. Chen and Wang⁸ reported the presence of a hyperintense vessel sign on FLAIR images in 22% of patients with RCVS, and this sign in patients with RCVS was associated with more severe vasoconstriction that may progress to ischemic stroke or posterior reversible encephalopathy syndrome. In our study, the incidence of a hyperintense vessel sign on initial MR imaging was also low (5 of 16 patients, 31%). This sign tended to be more frequent in patients with RCVS who experienced stroke. We considered that a hyperintense vessel sign might be an indicator of the severity of RCVS, rather than a diagnostic tool.

Limitations

TOF-MRA is a widely available, noninvasive technique that requires no radiation exposure and no administration of contrast material. However, the limitations of TOF-MRA include a lower spatial resolution than DSA and CTA¹⁶ and the presence of flow-induced artifacts. These limitations may diminish the ability to depict vasoconstriction in small vessels.

Chen et al⁶ reported that vasoconstriction of M1 and P2 is important for the development of posterior reversible encephalopathy syndrome and ischemic stroke in patients with RCVS. Although the present study included only 1 patient with posterior reversible encephalopathy syndrome and 1 patient with cerebral infarction, a high proportion of patients displayed vasoconstriction of M1 or P2. This study thus found no relationship between the location of vasoconstricted vessels and the type of stroke. We believe that a more detailed examination of the relationships between the locations of constricted vessels and the type of stroke is necessary in patients with RCVS.

This was a retrospective study of a small group of patients, and prospective studies with a greater number of cases are necessary.

CONCLUSIONS

Compared with MRA at the time of RCVS onset, this study found evidence of centripetal propagation of vasoconstriction on MRA performed at the time of remission of TCH. This time point therefore may represent a useful opportunity to diagnose RCVS with greater confidence if the clinician remains unsure of the diagnosis during the early stages of RCVS.

REFERENCES

1. Calabrese LH, Dodick DW, Schwedt TJ, et al. **Narrative review: reversible cerebral vasoconstriction syndromes.** *Ann Intern Med* 2007;146:34–44 CrossRef Medline
2. Ducros A. **Reversible cerebral vasoconstriction syndrome.** *Lancet Neurol* 2012;11:906–17 CrossRef Medline
3. Chen SP, Fuh JL, Lirng JF, et al. **Recurrent primary thunderclap headache and benign CNS angiopathy: spectra of the same disorder?** *Neurology* 2006;67:2164–69 CrossRef Medline
4. Ducros A, Boukobza M, Porcher R, et al. **The clinical and radiological spectrum of reversible cerebral vasoconstriction syndrome: a prospective series of 67 patients.** *Brain* 2007;130:3091–101 CrossRef Medline
5. Dodick DW, Brown RD Jr, Britton JW, et al. **Nonaneurysmal thunderclap headache with diffuse, multifocal, segmental, and reversible vasospasm.** *Cephalalgia* 1999;19:118–23 CrossRef Medline
6. Chen SP, Fuh JL, Wang SJ, et al. **Magnetic resonance angiography in reversible cerebral vasoconstriction syndromes.** *Ann Neurol* 2010;67:648–56 CrossRef Medline
7. Chen SP, Fuh JL, Chang FC, et al. **Transcranial color Doppler study for reversible cerebral vasoconstriction syndromes.** *Ann Neurol* 2008;63:751–57 CrossRef Medline
8. Chen SP, Wang SJ. **Hyperintense vessels: an early MRI marker of reversible cerebral vasoconstriction syndrome?** *Cephalalgia* 2014;34:1038–39 CrossRef Medline
9. Ducros A, Fiedler U, Porcher R, et al. **Hemorrhagic manifestations of reversible cerebral vasoconstriction syndrome: frequency, features, and risk factors.** *Stroke* 2010;41:2505–11 CrossRef Medline
10. Chen SP, Fuh JL, Wang SJ. **Reversible cerebral vasoconstriction syndrome: an under-recognized clinical emergency.** *Ther Adv Neurol Disord* 2010;3:161–71 CrossRef Medline
11. Cuvinciu V, Viguier A, Calviere L, et al. **Isolated acute nontraumatic cortical subarachnoid hemorrhage.** *AJNR Am J Neuroradiol* 2010;31:1355–62 CrossRef Medline
12. Covarrubias DJ, Luetmer PH, Campeau NG. **Posterior reversible encephalopathy syndrome: prognostic utility of quantitative diffusion-weighted MR images.** *AJNR Am J Neuroradiol* 2002;23:1038–48 Medline
13. Iancu-Gontard D, Oppenheim C, Touzé E, et al. **Evaluation of hyperintense vessels on FLAIR MRI for the diagnosis of multiple intracerebral arterial stenoses.** *Stroke* 2003;34:1886–91 CrossRef Medline
14. Chen SP, Fuh JL, Wang SJ. **Reversible cerebral vasoconstriction syndrome: current and future perspectives.** *Expert Rev Neurother* 2011;11:1265–76 CrossRef Medline
15. Kameda T, Namekawa M, Shimazaki H, et al. **Unique combination of hyperintense vessel sign on initial FLAIR and delayed vasoconstriction on MRA in reversible cerebral vasoconstriction syndrome: a case report.** *Cephalalgia* 2014;34:1093–96 CrossRef Medline
16. Bash S, Villablanca JP, Jahan R, et al. **Intracranial vascular stenosis and occlusive disease: evaluation with CT angiography, MR angiography, and digital subtraction angiography.** *AJNR Am J Neuroradiol* 2005;26:1012–21 Medline