



## **Minimally Invasive Ablation of a Toxic Thyroid Nodule by High-Intensity Focused Ultrasound**

O. Esnault, A. Rouxel, E. Le Nestour, G. Gheron and L. Leenhardt

This information is current as of July 3, 2025.

*AJNR Am J Neuroradiol* published online 14 January 2010  
<http://www.ajnr.org/content/early/2010/01/14/ajnr.A1979.citation>

## CASE REPORT

O. Esnault  
A. Rouxel  
E. Le Nestour  
G. Gheron  
L. Leenhardt



# Minimally Invasive Ablation of a Toxic Thyroid Nodule by High-Intensity Focused Ultrasound

**SUMMARY:** HIFU is used in the treatment of cancer (prostate, breast) and uterine fibroma but not yet in TNs. This case report describes the first successful ablation of a toxic TN with HIFU. TSH and radioiodine scan normalization were achieved without complications and maintained for 18 months. HIFU treatment is a minimally invasive technique that may be an effective safe alternative to radioiodine or surgery in patients with toxic TNs.

**ABBREVIATIONS:** AFTN = autonomously functioning thyroid nodule; ENT = ears, nose, and throat; FT<sub>3</sub> = triiodothyronine, free; FT<sub>4</sub> = thyroxine, free; HIFU = high-intensity focused ultrasound; <sup>123</sup>I = iodine 123; TN = thyroid nodule; TSH = thyroid-stimulating hormone, thyrotropin

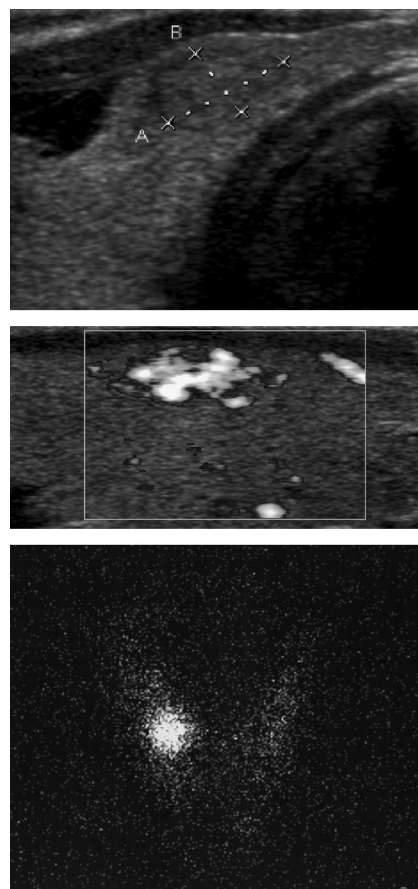
**P**atients with AFTNs present with overt (toxic adenoma) or subclinical (pretotoxic adenoma) hyperthyroidism. Standard definitive treatments are surgery or radioiodine.<sup>1,2</sup> Locally ablative methods, such as percutaneous intranodular ethanol injection,<sup>3,4</sup> radio-frequency,<sup>5</sup> or laser ablation,<sup>6,7</sup> have also been suggested as treatments.

HIFU is a new minimally invasive technique that allows elective thermal tissue destruction (coagulative necrosis and cavitation) within a few seconds by focusing a beam onto a given target.<sup>8</sup> HIFU has been used in the treatment of prostate and breast cancer, as well as uterine fibroma.<sup>9,10</sup> We previously reported our preliminary experience with HIFU in the ewe thyroid<sup>11</sup> and describe in the present case report the first successful ablation of an AFTN by using HIFU.

## Case Report

A 26-year-old man presenting with muscle weakness and asthenia for 3 months was referred to our clinic for hyperthyroidism. The thyrotropin level was low (0.02 mIU/L, normal 0.1–4 mIU/L), but FT<sub>4</sub> and FT<sub>3</sub> levels were normal (16.86 and 4.5 pmol/L, respectively; normal, 10–25 and 2.5–5.8 pmol/L, respectively). An <sup>123</sup>I thyroid scan revealed a hot right isthmolobar nodule with near-total suppression of extranodular iodine uptake and a low overall iodine uptake of 2% (Fig 1). Daily iodine excretion was in the upper limit of normal values (155 µg/24 hours). Symptomatic treatment with beta-blockers was initiated.

The patient was offered enrollment in a pilot monocentric non-comparative study analyzing the effectiveness and safety of an HIFU device (Theraclion, Paris Santé Cochin, France) in patients with AFTNs. The trial was designed to include patients with AFTN on scintigraphy who had TSH levels ≤0.1 mIU/L. After obtaining informed consent, we monitored clinical parameters and administered oral sedation. To prevent pain, we injected the nodule with 1% lidocaine under sonographic guidance. A specialist in ultrasonography performed the procedure under real-time sonographic guidance (Fal-



**Fig 1.** Top, Transversal sonography scan shows a 9 × 8 mm solid isoechoic right isthmolobar nodule. Middle, Longitudinal power Doppler sonography shows hypervascularization before HIFU treatment. Bottom, Hot right isthmolobar nodule with near-total suppression of extranodular iodine uptake is shown by the <sup>123</sup>I thyroid scan.

con; B-K Medical, Copenhagen, Denmark) by using a transducer (56-mm diameter; 38-mm focal length; 3-MHz frequency; focal region dimension, 2.5 × 8 × 1.8 mm). The nodule was spotted and drawn on the screen of a computer-controlled treatment unit (Thyros; Theraclion). This computer sequentially displaced the sonography beam over the nodule, creating multiple contiguous millimetric foci of necrosis. If the patient moved, treatment was automatically stopped. The HIFU session lasted 15 minutes (4 kJ delivered).

Treatment was well tolerated. The patient subjectively assessed his pain as 25 on a visual analog scale of 0–100. Neither blistering nor vocal cord palsy was observed. There was no clinical or biologic exac-

Received July 15, 2009; accepted after revision September 7.

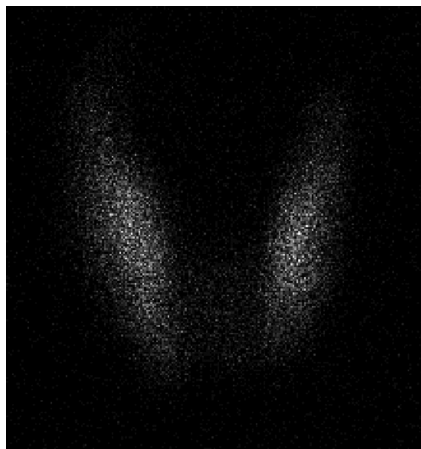
From the ENT and Maxillo Surgery Unit (O.E.), Paris, France; Therapeutic Applications of Ultrasound (O.E.), Inserm U556, Lyon Cedex, France; Department of Nuclear Medicine (A.R., G.G., L.L.), Pitié Salpêtrière Hospital, Paris, France; and Theraclion (E.L.N.), Paris Santé Cochin, Paris, France.

Please address correspondence to Olivier Esnault, MD, Cervico-Facial Surgery Department, 6 rue Puvis de Chavannes, 75017 Paris, France; e-mail: olivier.esnault@wanadoo.fr



Indicates open access to non-subscribers at [www.ajnr.org](http://www.ajnr.org)

DOI 10.3174/ajnr.A1979



**Fig 2.** Recovery of extranodular iodine uptake 18 months after HIFU is shown by the  $^{123}\text{I}$  thyroid scan.

erabation of hyperthyroidism. Two weeks after treatment, the nodule had become cystic. Biologic euthyroidism was achieved at 3 months (TSH, 1.91 mIU/L) and was maintained at 6, 12, and 18 months. At 12 and 18 months, the treated nodule was barely seen as a nonvascularized hypoechoic scar of  $1.4 \times 1.6$  mm. Thyroid scintigraphy showed a recovery of the thyroid iodine uptake (Fig 2).

## Discussion

Definitive treatment is always indicated in AFTNs with overt hyperthyroidism and is often recommended for patients with AFTNs and subclinical hyperthyroidism because of the risk of progression to overt hyperthyroidism.<sup>1,2</sup> Radioiodine is a cost-effective and safe procedure and the first choice of therapy for most patients with AFTNs. However, patients are somewhat reluctant to undergo this procedure in view of the policies and recommendations for reducing radiation hazards. Surgery may be preferred in young patients to avoid radiation exposure. The risks of surgery (vocal cord palsy, unavoidable scar, and general anesthesia) have to be taken into consideration.

Despite the small nodule size and normal  $\text{FT}_4$  and  $\text{FT}_3$ , the treatment decision for our patient was based on the clinical symptoms, nodule autonomy, TSH suppression, and the risk of future overt hyperthyroidism.

Radioiodine and surgery were both considered. The low iodine uptake, likely caused by transient iodine overload, did not favor radioiodine use. Surgery was not indicated because of the small size of the nodule and the patient's reservation toward surgery. Alternative treatments, such as ethanol injection,<sup>3,4</sup> laser,<sup>6,12,13</sup> or radio-frequency ablation,<sup>5</sup> have been reported. Thyroid function is normalized after ethanol injection in approximately 60%–80% of pretoxic nodules and 35%–85% of toxic nodules.<sup>3</sup> Tarantino et al<sup>4</sup> reported complete cure (absent uptake in the nodule and recovery of normal uptake in the thyroid parenchyma) in 93% of patients with AFTNs. After laser ablation, cure rates of 61%–100% have been reported.<sup>6,13</sup> Radio-frequency ablation has also been suggested as a potential nonsurgical therapeutic option.<sup>5</sup>

These procedures are all minimally invasive, requiring, in the case of radio-frequency ablation, the insertion of electrodes into the thyroid nodule and at least 1.5-cm safety margins around the surrounding organs.<sup>12</sup> These treatments often require repeat injections or sessions to achieve total cure, es-

pecially in the case of large nodules.<sup>12</sup> Our procedure simply required local intranodular anesthetic, only 2-mm safety margins, and a single 15-minute HIFU session.

With only 1 case, it is too early to compare complication rates between HIFU and other techniques. A complication rate of 3.2%, including vocal cord palsy, abscess, and hematoma, was reported for percutaneous ethanol injection.<sup>4</sup> In our preliminary animal study, some injuries to neighboring organs, such as skin, trachea, esophagus, and recurrent nerves, were observed; however, the device we used in these studies was not fully suited for this purpose.<sup>11</sup> In other clinical applications of HIFU, skin burns and bowel infarction have been reported.<sup>14,15</sup> Morbidity needs to be assessed on a larger scale. Due to stringent inclusion criteria regarding TSH, the tight deadlines of this pilot study, and the subsequent lack of participants, patient enrollment had to be stopped.

In conclusion, this is the first report of the cure of a small AFTN by using HIFU with excellent clinical, biologic, ultrasonographic, and scintigraphic results at 18 months. This case suggests the feasibility and effectiveness of a technique that is safely repeatable in patients with larger nodules. Although further evaluation is needed to confirm these results, this ambulatory, minimally invasive treatment seems to be a promising therapeutic alternative in clinical settings. Advantages over standard therapies would appear significant in terms of cost and morbidity.

## References

1. Biondi B, Palmieri EA, Klain M, et al. Subclinical hyperthyroidism: clinical features and treatment options. *Eur J Endocrinol* 2005;152:1–9
2. Gharib H, Tuttle RM, Baskin HJ, et al. Subclinical thyroid dysfunction: a joint statement on management from the American Association of Clinical Endocrinologists, the American Thyroid Association, and the Endocrine Society. *J Clin Endocrinol Metab* 2005;90:581–85, discussion 586–87
3. Guglielmi R, Pacella CM, Bianchini A, et al. Percutaneous ethanol injection treatment in benign thyroid lesions: role and efficacy. *Thyroid* 2004;14:125–31
4. Tarantino L, Francica G, Sordelli I, et al. Percutaneous ethanol injection of hyperfunctioning thyroid nodules: long-term follow-up in 125 patients. *AJR Am J Roentgenol* 2008;190:800–08
5. Baek JH, Jeong HJ, Kim YS, et al. Radiofrequency ablation for an autonomously functioning thyroid nodule. *Thyroid* 2008;18:675–76
6. Pacella CM, Bizzarri G, Spiezia S, et al. Thyroid tissue: US-guided percutaneous laser thermal ablation. *Radiology* 2004;232:272–80
7. Cakir B, Gul K, Ugras S, et al. Percutaneous laser ablation of an autonomous thyroid nodule: effects on nodule size and histopathology of the nodule 2 years after the procedure. *Thyroid* 2008;18:803–05
8. Chapelon JY, Margonari J, Theillere Y, et al. Effects of high-energy focused ultrasound on kidney tissue in the rat and the dog. *Eur Urol* 1992;22:147–52
9. Wu F, Wang ZB, Zhu H, et al. Extracorporeal high intensity focused ultrasound treatment for patients with breast cancer. *Breast Cancer Res Treat* 2005;92:51–60
10. Rouviere O, Souchon R, Salomir R, et al. Transrectal high-intensity focused ultrasound ablation of prostate cancer: effective treatment requiring accurate imaging. *Eur J Radiol* 2007;63:317–27
11. Esnault O, Franc B, Monteil JP, et al. High-intensity focused ultrasound for localized thyroid-tissue ablation: preliminary experimental animal study. *Thyroid* 2004;14:1072–76
12. Dossing H, Bennedbaek FN, Hegedus L. Effect of ultrasound-guided interstitial laser photocoagulation on benign solitary solid cold thyroid nodules: one versus three treatments. *Thyroid* 2006;16:763–68
13. Cakir B, Topaloglu O, Gul K, et al. Effects of percutaneous laser ablation treatment in benign solitary thyroid nodules on nodule volume, thyroglobulin and anti-thyroglobulin levels, and cytopathology of nodule in 1 yr follow-up. *J Endocrinol Invest* 2006;29:876–84
14. Hacker A, Michel MS, Marlinghaus E, et al. Extracorporeally induced ablation of renal tissue by high-intensity focused ultrasound. *BJU Int* 2006;97:779–85
15. Li JJ, Xu GL, Gu MF, et al. Complications of high intensity focused ultrasound in patients with recurrent and metastatic abdominal tumors. *World J Gastroenterol* 2007;13:2747–51