



Discover Generics

Cost-Effective CT & MRI Contrast Agents



FRESENIUS
KABI

WATCH VIDEO

AJNR

Carotid cavernous fistula associated with Fogarty catheter angioplasty.

P Flandroy, J Lenelle, J Collignon and A Stevenaert

AJNR Am J Neuroradiol 1988, 9 (6) 1242

<http://www.ajnr.org/content/9/6/1242.citation>

This information is current as
of June 3, 2025.

Carotid Cavernous Fistula Associated with Fogarty Catheter Angioplasty

Carotid cavernous fistulae are usually the consequence of a vascular tear due to head trauma or a ruptured intracranial aneurysm. Although rare, iatrogenic carotid cavernous fistulae can result from percutaneous retrogasserian procedures, transsphenoidal hypophysectomy, and thromboembolectomy via a Fogarty catheter [1-3]. Since the first report on the use of Fogarty catheters in 1963 [4], only 10 iatrogenic cases have been described. We describe an iatrogenic carotid cavernous fistula that occurred in a patient who was treated with a Fogarty catheter for fibromuscular dysplasia. The fistula was closed with a detachable balloon [5].

Case Report

A 50-year-old woman who had fibromuscular dysplasia was referred to our hospital with a clinical diagnosis of presumed left carotid cavernous fistula that occurred after an endoluminal angioplasty of her left carotid artery. Clinical examination showed pulsatile exophthalmos, complete ophthalmoplegia, and blindness on the left side. Carotid angiography confirmed the original diagnosis (Fig. 1A). Closure of the fistula was achieved by means of a 2-ml detachable balloon (Fig. 1B). Within a few days, the exophthalmos diminished, and the patient recovered slowly from her oculomotor palsy. Unfortunately, the blindness in the left eye remained.

Discussion

Most of the cases of iatrogenic cavernous fistulae described in the literature occurred as a result of a carotid artery thromboembolectomy in which a Fogarty catheter was used. Fuentes et al. [3] suggested that the arterial lesion was located on the proximal vertical segment of the carotid siphon (C5). In our case also, the rupture apparently was at this level; the intracavernous part of the carotid artery was never visible on diagnostic angiography. To explain the fistula, we must assume that the distal end of the catheter had caused a direct lesion of the arterial wall. The angioplasty had been performed without fluoroscopic control, and the rather stiff Fogarty

catheter, if pushed too far, could have caused a direct perforation of the anterior wall of the C5 segment, which is in the axis of the carotid canal (Fig. 1C).

Unlike other cases, our patient suffered from internal carotid fibromuscular dysplasia. The Fogarty catheter was used for angioplasty and not for a thromboembolectomy. According to Andre [6], the surgical treatment consists of progressive dilatation with a balloon catheter, but this procedure must be reserved for patients who have neurologic signs. Our patient became blind in the left eye during the angioplasty. On ophthalmologic examination, the papilla was pale, and the diagnosis was thrombosis of the central retinal artery. It is possible that this vessel was embolized with a small blood clot or a piece of arterial wall during the angioplasty. Blindness was the only sign that remained 2 years after the cure of the fistula.

P. Flandroy

J. Lenelle

J. Collignon

A. Stevenaert

University Hospital of Liège

Liège 1, Belgium

REFERENCES

1. Barker WF, Stern WE, Krayenbuhl H, Senning A. Carotid endarterectomy complicated by carotid cavernous sinus fistula. *Ann Surg* 1968;167:568-572
2. Davie JC, Richardson R. Distal internal carotid thrombo-embolectomy using a Fogarty catheter in total occlusion: technical note. *J Neurosurg* 1967;27:171-177
3. Fuentes JM, Benezech J, Joyeux A, et al. Les fistules carotido-caverneuses iatrogènes, complications de la thrombectomie carotidienne. *Neurochirurgie* 1985;31:265-270
4. Fogarty TJ, Cranley JJ, Kruse RJ, et al. A method for extraction of arterial emboli and thrombi. *Surg Gynecol Obstet* 1963;116:241-244
5. Debrun G, Lacour P, Vinuela F, Fox A, Drake CG, Caron JP. Treatment of 54 traumatic carotid cavernous fistulas. *J Neurosurg* 1981;55:678-692
6. Andre JM. Les dysplasies vasculaires systématisées. *L'Expansion Scientifique Française (Paris)* 1973;4:440-469

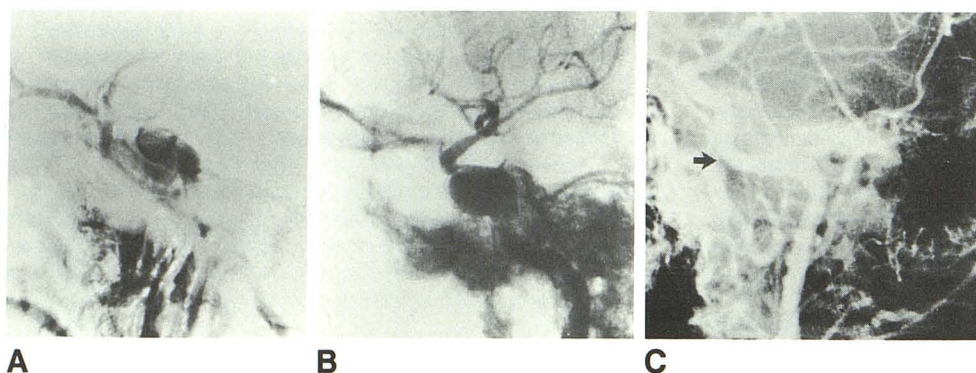


Fig. 1.—Carotid cavernous fistula associated with Fogarty catheter angioplasty.

A and B, Lateral left internal carotid angiograms show carotid cavernous fistula (A) and balloon released in cavernous sinus (B).

C, Oblique left internal carotid angiogram obtained before angioplasty shows presumed point (arrow) of arterial perforation by tip of Fogarty catheter.