



## Discover Generics

Cost-Effective CT & MRI Contrast Agents



FRESENIUS  
KABI

WATCH VIDEO

# AJNR

## Vanishing empty delta sign in cerebral venous thrombosis.

A Matsumura, A Shinohara, Y Komatsu, M Hashikawa and T Nose

*AJNR Am J Neuroradiol* 1988, 9 (6) 1239-1240

<http://www.ajnr.org/content/9/6/1239.citation>

This information is current as  
of June 6, 2025.

## Abbreviated Reports

### Vanishing Empty Delta Sign in Cerebral Venous Thrombosis

The "empty delta sign" is considered a pathognomonic finding in cases of dural venous sinus thrombosis [1–5]. However, the occurrence of this sign in large series has varied from 0 to 86% [1, 3, 5]. We present a case in which the empty delta sign disappeared on repeat CT scan the day after admission.

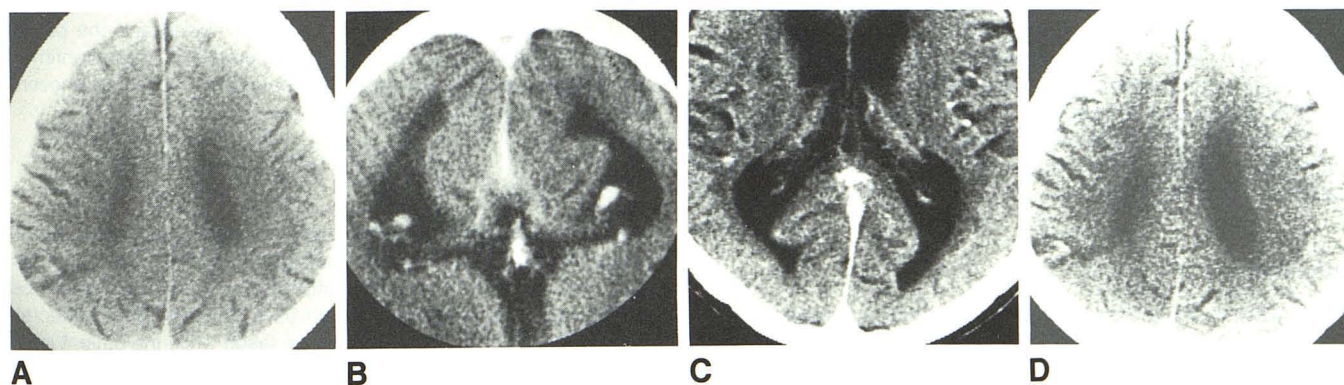
#### Case Report

A 62-year-old man was admitted as an emergency patient at 6 A.M. because of a sudden loss of consciousness. He was a heavy drinker and had consumed a large amount of alcohol the previous night. At 5:30 A.M. his family had noticed that he was snoring unusually loudly and did not respond to verbal stimuli. On admission, he was drowsy and showed increased deep tendon reflexes in his lower extremities, Babinski reflex on his right side, and conjugated deviation of his eyes to the left. Hemoglobin concentration was 17.6 g/dl, and hematocrit was 52% (0.52), suggesting dehydration. Plain CT scan showed an area of high density in the right parietal area (Fig. 1A), and a contrast-enhanced scan showed a triangular filling defect in the superior sagittal sinus (Fig. 1B). This filling defect was interpreted as an empty delta sign. The diagnosis was venous thrombosis. The patient was given large amounts of IV fluids, and his neurologic condition improved within hours. Carotid angiography performed in the afternoon of the day of admission failed to show occlusion of the superior sagittal sinus. The CT scan was repeated

the next day and still showed the high-density area in the right parietal region, but the empty delta sign was no longer apparent, even with thin-slice CT and a wide window setting (Fig. 1C). The high-density area in the right parietal region disappeared about 1 month after onset. Six months after this episode, the patient had recovered fully without any neurologic deficit.

#### Discussion

The CT findings of cerebral venous sinus thrombosis have been described by several authors [1–5]. The filling defect within the superior sagittal sinus, the so-called empty delta sign, was first described by Buonanno et al. [1]. This sign is thought to be of diagnostic value [1–6]. However, its occurrence varies from 0 [3] to 86% [5]. Disappearance of the sign has been described also [2, 4, 6–8], and the significance of this phenomenon recently was emphasized by Shinohara et al. [6]. In two of their cases, the sign disappeared 3 months after onset. They also found that the sign was not observed in the acute stage (i.e., within 5 days of onset). Among other reports, the earliest disappearance of this sign was 12 days after onset [4]. In our case, the diagnosis of venous sinus thrombosis was based on the empty delta sign and the area of high density seen in the first CT scan, which was thought to be due to a venous thrombosis or to hemorrhage. The neurologic deficits and severe dehydration observed at admission also supported the diagnosis.



**Fig. 1.**—The empty delta sign in cerebral venous sinus thrombosis. A and B, Plain (A) and contrast-enhanced (B) CT scans obtained on day of onset show an area of high density in right parietal region (A) and empty delta sign in superior sagittal sinus (B). C and D, CT scans taken 2 days after onset show absence of empty delta sign (C) and persistence of high-density area in right parietal region (D).



Failure to demonstrate the sinus thrombosis by angiography probably was due to the time lag between the first CT scan and angiography, although the delay was only a few hours. Even when careful observation, thin slices, and a wide window setting were used, the CT scan taken on the next day also failed to demonstrate the empty delta sign. Thus, we think that the thrombus in the superior sagittal sinus may have disappeared between the time of the first CT scan and the angiography. The IV hydration therapy, which resulted in rapid clinical improvement, may have contributed to the disappearance of the thrombus. A benign clinical course in cases of cerebral venous thrombosis such as our case has been described by Kusunoki et al. [9]. In such cases, the presence of abundant venous collaterals is thought to be one contributory factor [10]. In our case, we suspect that the thrombus may have been either dissolved or carried away in the very early stage as an abortive form, thus resulting in complete recovery. An empty delta sign on CT scan is pathognomonic for cerebral venous sinus thrombosis. However, disappearance of the sign may occur early, as seen in our case, and should be recognized as a possibility when cerebral venous thrombosis is suspected.

Akira Matsumura  
Akira Shinohara  
Youji Komatsu  
Masanori Hashikawa  
Hata General Hospital  
Ibaraki, 316 Japan  
Tadao Nose  
University of Tsukuba, Ibaraki, 305 Japan

## REFERENCES

1. Buonanno FS, Moody DM, Ball MR, Laster DW. Computed cranial tomographic findings in cerebral sinovenous occlusion. *J Comput Assist Tomogr* 1978;2:281-290
2. Goldberg AL, Rosenbaum AE, Wang H, Kim WS, Lewis VL, Hanley DF. Computed tomography of dural sinus thrombosis. *J Comput Assist Tomogr* 1986;10:16-20
3. Kingsley DPE, Kendall BE, Moseley IF. Superior sagittal sinus thrombosis: an evaluation of the changes demonstrated on computed tomography. *J Neurol Neurosurg Psychiatry* 1978;41:1065-1068
4. Patronas NJ, Duda EE, Mirkfakhraee M, Wollmann RL. Superior sagittal sinus thrombosis in children with acute lymphoblastic leukemia. *Surg Neurol* 1981;15:11-14
5. Rao KC, Knipp HC, Wagner EJ. Computed tomographic findings in cerebral sinus and venous thrombosis. *Radiology* 1981;140:391-398
6. Shinohara Y, Yoshitoshi M, Yoshii F. Appearance and disappearance of empty delta sign in superior sagittal sinus thrombosis. *Stroke* 1986;17:1282-1284
7. Brant-Zawadzki M, Chang GY, McCarty GE. Computed tomography in dural sinus thrombosis. *Arch Neurol* 1982;39:446-447
8. Crimmings TJ, Rockswold GL, Yock DH Jr. Progressive posttraumatic superior sagittal sinus thrombosis complicated by pulmonary embolism: case report. *J Neurosurg* 1984;60:179-182
9. Kusunoki S, Iwata M, Shimada Y, Toyokura Y, Mannen T. Benign superior sagittal sinus thrombosis: report of a case with generalized migratory thrombophlebitis. *Jpn J Stroke* 1986;8:301-305
10. Kalbag RM, Woolf AL. Thrombosis and thrombophlebitis of cerebral veins and dural sinuses. In Vinken PJ, Bruyn GW, eds. *Handbook of clinical neurology*. Amsterdam: North-Holland 1972:422-446

## Intracerebral Biopsy Hemorrhage: Monitoring and Intervention Guided by Intraoperative Sonography

Blind surgical procedures on intracranial masses have long been a problem for neurosurgeons. In recent years, CT guidance has increasingly been used to guide neurosurgical procedures. With the development of CT stereotaxis, biopsies and aspirations of intracranial material can be carried out through a burr hole with minimal invasiveness.

Paralleling the rise in the use of CT stereotaxis has been the use of intraoperative brain sonography to guide cerebral procedures. Intraoperative sonography provides a real-time view of the brain that can be used to monitor procedures. Attachment of a biopsy guide to the sonographic transducer allows accurate biopsies and aspirations of cysts, although at this time a craniotomy usually is needed.

Sonography requires a greater exposure but allows continuous monitoring for complications, such as postbiopsy hemorrhage. In this report of a case of postbiopsy intracerebral bleeding, we describe how monitoring via intraoperative sonography allowed us to take immediate measures to prevent further hemorrhage and confirm stabilization of a hematoma.

### Case Report

The patient was a 59-year-old man who had a history of right hemiparesis. A CT scan showed a cystic lesion approximately 2-2.5 cm in diameter just lateral to the internal capsule in the left cerebral hemisphere. A left craniotomy was performed, and an intraoperative sonographic probe with a 5-MHz transducer connected to an OR 330 Technicare machine was used to identify the lesion and select a route for the biopsy. A cystic lesion approximately 2 cm in diameter was identified just lateral to the internal capsule (Fig. 1A). The lesion was

entered, and cystic fluid was evacuated. The lesion was then biopsied twice. After the second biopsy, active bleeding was noted in real time within the cystic cavity. The bleeding was hypoechoic at first; however, in a matter of minutes, it became hyperechoic, and the diameter of the previous lesion increased (Fig. 1B). At this point, to prevent further hemorrhage, we lowered the patient's blood pressure and maintained it at a systolic pressure of 70-80 mm Hg. The size of the lesion stopped growing, and the blood pressure was maintained at 70-80 mm Hg for approximately 45 min. During that time the lesion was monitored continuously. When the lesion had been stable for approximately 45 min, the blood pressure was slowly raised. Once the lesion was stable, the craniotomy was closed and the patient was sent to the recovery room. A postoperative CT scan confirmed the hemorrhage (Figs. 1C and 1D). The patient recovered uneventfully.

### Discussion

Lillehei et al. [1] have documented the sonographic appearance of acute cerebral hematomas. The hematomas are hypoechoic at first and then become hyperechoic after 22 sec because of red-cell aggregation. If a complication such as a hemorrhage is detected, preventive action could theoretically be taken while the patient is still in the operating room rather than in the recovery room or CT scanner. Knake et al. [2, 3] documented two cases in which postbiopsy hemorrhage did occur and in which they were able to monitor the hemorrhage by sonography. They determined that the hemorrhagic lesion had stopped growing even though they had taken no interventional measures.