



Discover Generics

Cost-Effective CT & MRI Contrast Agents



WATCH VIDEO

AJNR

Mobile intrathecal bullet causing delayed radicular symptoms.

L J Soges, G H Kinnebrew and O G Limcaco

AJNR Am J Neuroradiol 1988, 9 (3) 610

<http://www.ajnr.org/content/9/3/610.citation>

This information is current as
of June 24, 2025.

Mobile Intrathecal Bullet Causing Delayed Radicular Symptoms

It has long been known that projectiles can migrate spontaneously within the CNS [1, 2]. We report a case of an abdominal gunshot wound in which CNS trauma was not suspected for several days, until the migrating bullet caused radicular symptoms.

Case Report

A 27-year-old man who was intoxicated came to the emergency department after he accidentally shot himself in the abdomen with a .25 caliber pistol. The physical examination revealed an entry wound in the right midabdomen and surrounding powder burns on the skin. No exit wound was found. The patient was in stable condition.

After a laparotomy for repair of small bowel and mesentery, the patient began complaining of numbness of and discomfort in the left leg and foot. Neurologic examination showed deficits in the distribution of the sacral nerves, with loss of sensation in the lower left leg, urinary urgency, and no feeling around the anus. Abdominal radiographs obtained at the time showed a metallic density (the bullet) within the spinal canal just above the S1–S2 interspace (Figs. 1A and 1B). Some cortical disruption of the vertebral end plates around the T11–T12 disk suggested that that might have been the site of entry.

A myelogram/CT was performed to ascertain whether the bullet was intradural (Fig. 1C). Under fluoroscopy, the bullet was seen to move around within the thecal sac. The sac was intact up to the L2–L3 level.

Because of the patient's symptoms, removal of the bullet was thought to be indicated, and a sacral laminectomy was performed. When the dura was opened, the bullet had migrated upward. The dural incision was extended until the bullet was encountered. The bullet was removed, and the patient improved clinically.

Discussion

This is an unusual case of a bullet entering the thecal sac via the anterior abdomen, without initially causing detectable neurologic symptoms. Migrating freely within the subarachnoid space, it eventually caused radicular symptoms by compressing the sacral nerve roots. Few such cases have been reported, and we were unable to find any in the radiologic literature. Karim et al. [3] had a similar case in which an intrathecal bullet migrated from the T11–T12 level to the

L4–L5 level within a day, causing delayed radicular symptoms. Tanguy et al. [4] reported the migration of a bullet in the subarachnoid space that moved from the cervical spine to the sacral region. Kerin et al. [5] followed the migration of a bullet from a location posterior to the brainstem, probably the quadrigeminal plate cistern, to the caudal end of the thecal sac over the course of 4 months. The patient's symptoms correlated with the movement of the bullet.

These studies indicate that the general direction of migration of metallic foreign bodies once they reach the spinal subarachnoid space is caudally, under the influence of gravity. Although the natural narrowing of the spinal canal at the level of T10 usually will prevent cephalad migration beyond that point [6], it obviously does not prevent caudal migration. Thus, a subarachnoid foreign body may be located far from its original point of entry, and a metallic density at the tip of the thecal sac may represent something other than residual contrast material.

Laurence J. Soges
SUNY Health Science Center at Syracuse
Syracuse, NY 13210
George H. Kinnebrew
Oscar G. Limcaco
Union Hospital
Terre Haute, IN 47807

REFERENCES

1. Jefferson G. Removal of a rifle bullet from the right lobe of the cerebellum, illustrating the spontaneous movement of a bullet in the brain. *Br J Surg* 1917;5:422–424
2. Vilvandre G, Morgan JD. Movement of foreign bodies in the brain. *Arch Radiol Electrother* 1916;21:22–27
3. Karim NO, Nabors MW, Golocovsky M, Cooney FD. Spontaneous migration of a bullet in the spinal subarachnoid space causing delayed radicular symptoms. *Neurosurgery* 1986;18(1):97–100
4. Tanguy A, Chabannes J, Deubelle A, Vanneville G, Dalens B. Intraspinal migration of a bullet with subsequent meningitis: a case report. *J Bone Joint Surg [Am]* 1982;64-A:1244–1245
5. Kerin DS, Fox R, Mehringer CM, Grinnell V, Miller RE, Hieshima GB. Spontaneous migration of a bullet in the central nervous system. *Surg Neurol* 1983;20(4):301–304
6. Ledgewood AM. The wandering bullet. *Surg Clin North Am* 1977;57:97–109

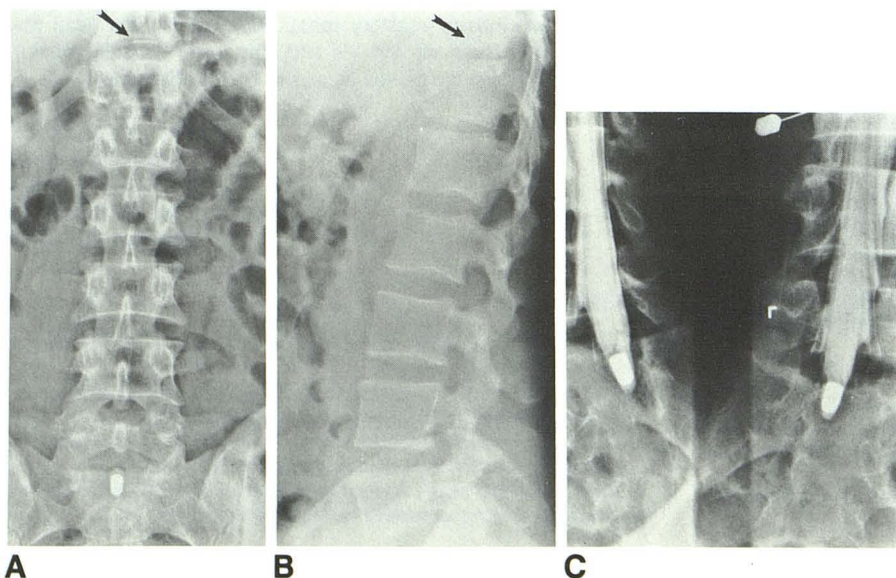


Fig. 1.—Mobile intrathecal bullet in a 27-year-old man.

A and B, Abdominal radiographs show end-plate disruption at T11–T12 (arrows) that indicates suspected point of entry. Radiograph (A) obtained after patient began complaining of leg numbness and pain shows bullet overlying midline of sacrum. Lateral view (B) obtained subsequently localizes bullet within spinal canal.

C, Myelogram confirms intradural location of bullet at caudal end of thecal sac.