



Providing Choice & Value

Generic CT and MRI Contrast Agents



**FRESENIUS
KABI**

CONTACT REP

AJNR

Cranial CT in galactosemia.

G D Marano, W S Sheils, Jr, O F Gabriele and W G Klingberg

AJNR Am J Neuroradiol 1987, 8 (6) 1150-1151

<http://www.ajnr.org/content/8/6/1150.citation>

This information is current as
of July 23, 2025.

started. Postoperatively the patient had no progression of her neurologic deficits and responded well to antituberculous therapy. A CT scan obtained on the 10th postoperative day showed slight prominence of the pons without hemorrhage or mass effect.

Discussion

Before the advent of antituberculous agents, complete surgical excision of intracerebral tuberculoma offered the only chance for survival, generally with poor results [1]. Currently, however, these agents are the treatment of choice for CNS tuberculoma, with surgery reserved for cases of uncontrolled intracranial pressure or failure of medical therapy [2]. Symptomatically, neoplastic and vascular lesions of the brainstem and infection can have similar presentations [1, 3, 5]. Unless a primary focus of infection is identified, histologic confirmation of an intracranial lesion is mandatory before any therapy is started.

Because of its contrast resolution and multiple projections, MR has been shown to be superior to CT for imaging brainstem lesions [6, 7]. As documented by the present case, the true extent of the tuberculoma and its precise relationship to adjacent structures could not be fully appreciated by CT. Use of MR in areas edemic for tuberculosis will allow further characterization of this granulomatous process.

Despite their sensitive locations, biopsy of brainstem lesions can be accomplished with minimal disruption of normal tissue [8]. Further application of MR and MR-directed stereotaxis will provide precise three-dimensional localization of brainstem lesions, increasing the likelihood of successful biopsy with diminished risks.

Benjamin H. Venger
Francoise M. Dion
Emilie Rouah
Stanley F. Handel
Baylor College of Medicine
Houston, TX 77030

REFERENCES

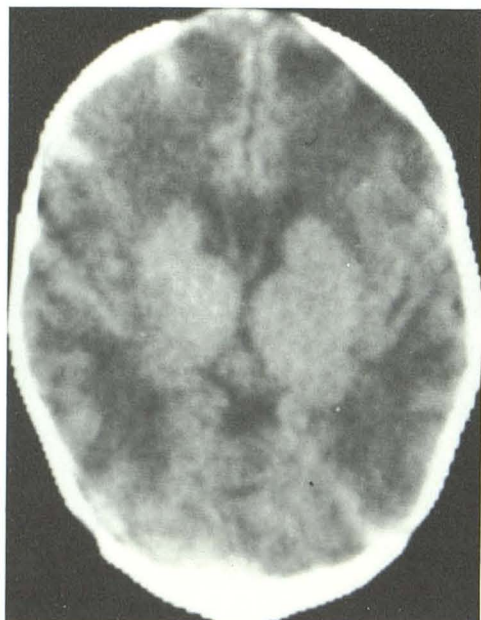
1. Dastur HM. Diagnosis and neurosurgical treatment of tuberculous disease of the CNS. *Neurosurg Rev* 1983;6:111-117
2. DeAngelis LM. Intracranial tuberculoma: case report and review of the literature. *Neurology* 1981;31:1133-1136
3. Mayers MM, Kaufman DM, Miller MH. Recent cases of intracranial tuberculomas. *Neurology* 1978;28:256-260
4. Bobrowitz ID. Active tuberculosis undiagnosed until autopsy. *Am J Med* 1982;72:650-658
5. Mahanta A, Kalra L, Maheshwari MC, Mishra NK. Brainstem tuberculoma: an unusual presentation. *J Neurol* 1982;227:249-253
6. Lee BCP, Knelland JB, Walker RW, Posner JB, Cahill PT, Deck MDF. MR imaging of brainstem tumors. *AJNR* 1985;6:156-163
7. Hans WS, Bonstelle CT, Kaufman B, et al. Magnetic resonance imaging in the evaluation of the brainstem. *Radiology* 1984;150:705-712
8. Coffey RJ, Lunsford LD. Stereotactic surgery for mass lesions of the midbrain and pons. *Neurosurgery* 1985;17:12-18

Cranial CT in Galactosemia

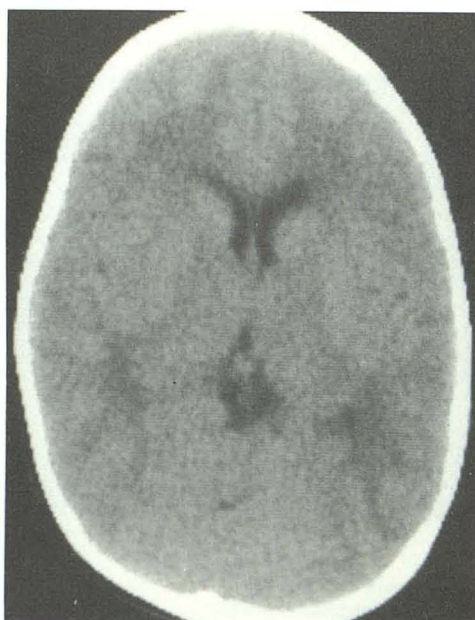Galactosemia is an autosomal recessive disorder occurring in one in 40,000 live births. Cranial CT changes in galactosemia before and after treatment have been reported only recently in the literature [1]. This case is the second. In both cases, CT findings were strikingly similar, and their resolution corresponded to clinical improvement.

Case Report

A 5-week-old boy was admitted to the hospital for evaluation of ascites; the presumptive diagnosis was phenylketonuria. The direct bilirubin was moderately elevated. Head circumference was at the 35th percentile, and the weight was at the 5th percentile. The neurologic examination was unremarkable except for a mild developmental delay. Galactosemia was suspected after a urine glucose test was performed, and the diagnosis was confirmed by enzyme assay that showed no activity of galactose-1-phosphate uridyl transferase. The infant also was found to have cataracts. Head CT revealed symmetric low attenuation in the white matter, with sparing of the basal ganglia and a moderate degree of ventricular dilatation (Fig. 1). After 20 months of milk restriction, follow-up CT was performed. It showed significant recovery of normal white-matter attenuation, with only a minimal degree of ventricular dilatation (Fig. 2). Follow-up physical examination revealed normal liver and spleen size, normal neurologic development, and resolution of cataracts.



1



2

Fig. 1.—Unenhanced CT scan of head at 5 weeks of age shows decreased attenuation diffusely throughout white matter, with relative sparing of basal ganglia. Mild ventricular dilatation is also present.

Fig. 2.—Follow-up unenhanced CT scan of head 19 months later, after dietary restriction of lactose, shows return to normal appearance of white matter; ventricles are still somewhat prominent for age.

Discussion

Cranial CT changes associated with metabolic and storage disorders have been well documented. However, until recently [1], CT findings in galactosemia had not been shown.

Previous neuropathologic autopsy findings in galactosemia have been described by Crome [2] as a "microencephaly caused by a mainly burnt out gliotic encephalomyelopathy." Hypothesized causes for this encephalopathy include hypoglycemia and competitive inhibition from hyperbilirubinemia or galactose-1-phosphate [3]. The toxic effect of galactose has been shown in animal models; it caused early and permanent injury to fetal nervous tissue and affected both growth and maturation [3]. Another study [4] showed the interference of galactose and galactitol in the metabolism of myelin constituents.

In our patient, the dramatic reversibility of diffuse white-matter low attenuation suggests the presence of an interstitial intracerebral edema that is secondary to the toxic effect of galactose, perhaps because of osmolar effects as suggested by Belman et al. [1]. Another possibility for the intracerebral edema is that, with a dysmyelinating process, the loss of myelin, which is normally hydrophobic, causes an influx of water. The reversibility of edema coincided with initiation of a lactose-free diet and correlated with significant improvement in affected end organs, specifically the liver, spleen, lens, and CNS.

Gary D. Marano

William S. Sheils, Jr.

Orlando F. Gabriele

William G. Klingberg

West Virginia University Medical Center

Morgantown, WV 26506

REFERENCES

1. Belman AL, Moshe SL, Zimmerman RD. Computed tomographic demonstration of cerebral edema in a child with galactosemia. *Pediatrics* 1986;78:606-609
2. Crome L. A case of galactosemia with the pathological and neuropathological findings. *Arch Dis Child* 1962;37:431-447
3. Haberland C, Perou M, Brunngraber Hof H. The neuropathology of galactosemia. *J Neuropath Exp Neurol* 1971;30:432-447
4. Wells HJ, Wells WW. Galactose toxicity and myoinositol metabolism in the developing rat brain. *Biochemistry* 1967;6:1168-1173

Primary Spinal Primitive Neuroectodermal Tumor with Extraneural Metastases

Primary spinal primitive neuroectodermal tumor (PNET) is rare [1]. Although extraneural metastases of CNS tumors once were considered rare, a recent review documented 282 cases, one of which was a primary spinal PNET [2]. We describe a case of a 26-year-old man with a primary spinal intradural PNET and subsequent metastases to bone, lymph nodes, pleura, and spinal extradural space.

Case Report

A 26-year-old man presented with a 6-month history of progressive lethargy and dyspnea. Three years before admission, he had presented with symptoms of cervical spinal cord compression, and a myelogram had shown an intradural, extramedullary mass at the C2 level, producing high-grade, incomplete obstruction to the flow of contrast (Fig. 1). Chest radiograph and CT scan of the head were normal. Subsequently, a large intradural extramedullary mass involving the C2-C3 level was excised surgically. The histologic diagnosis was PNET. Total neuraxis radiotherapy was administered. He was then lost to follow-up.

On admission, the patient was cachectic and had diffuse lymphadenopathy. Hematologic examination showed pancytopenia. A chest radiograph on admission showed diffuse sclerotic bone metastases, bilateral pleural effusions, and multiple pleural mass lesions (Fig. 2). The patient refused treatment and died 10 days after admission.

Autopsy showed spinal extradural and systemic metastases that were morphologically identical (by standard histologic techniques, immunoperoxidase studies, and electron microscopy) to the original surgically removed cervical intradural lesion (Fig. 3). Extradural tumor was present from C8 to T6. No residual intradural tumor was found. Extensive parietal pleural and paravertebral metastatic deposits and a large right apical visceral pleural metastasis were present. Widespread bone and lymph node metastases were found. The brain and intracranial leptomeninges were free of tumor. A small focus of extradural tumor was present in the posterior fossa.

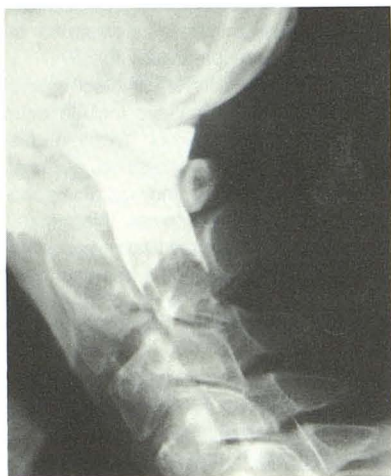

Fig. 1.—Cervical myelogram, lateral view, shows intradural extramedullary mass at C2.

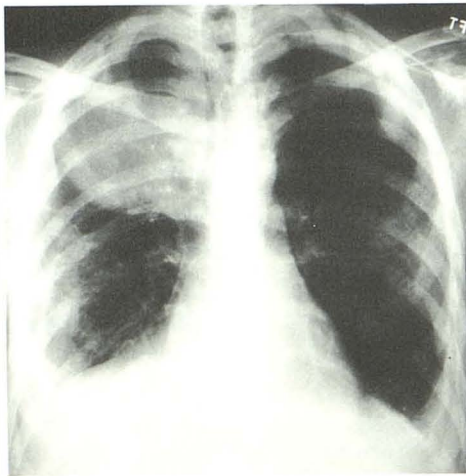


Fig. 2.—Posteroanterior chest radiograph shows sclerotic bone metastases, bilateral pleural effusions, and multiple pleural mass lesions.

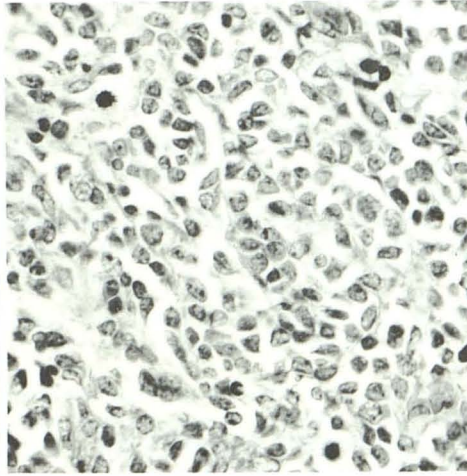


Fig. 3.—Photomicrograph of biopsy specimen from cervical extramedullary lesion shows "small dark cell" tumor. (H and E $\times 40$)