



Discover Generics

Cost-Effective CT & MRI Contrast Agents



WATCH VIDEO

AJNR

Cerebellar calcification in central neurofibromatosis: CT in two cases.

P Van Tassel, J W Yeakley and K F Lee

AJNR Am J Neuroradiol 1987, 8 (5) 913-915

<http://www.ajnr.org/content/8/5/913.citation>

This information is current as
of June 21, 2025.

Cerebellar Calcification in Central Neurofibromatosis: CT in Two Cases

Pamela Van Tassel,^{1,2} Joel W. Yeakley, and K. Francis Lee

Manifestations of central von Recklinghausen's neurofibromatosis are well known and may include bilateral acoustic neuromas in the absence of peripheral neurofibromatosis or associated gliomas, meningiomas, other cranial nerve neuromas, optic nerve gliomas, and ependymomas [1]. A few reports deal specifically with the cranial CT findings in central neurofibromatosis [2-4]. One series [3] includes a case with cerebellar calcification unassociated with a mass lesion. We report two additional cases of central neurofibromatosis, both of which exhibited bilateral acoustic neuromas and nonneoplastic calcification in the cerebellar hemispheres on CT.

Case Reports

Case 1

A 24-year-old woman presented with a 1-year history of intermittent vertigo and headaches, as well as hearing loss on the right during the preceding 2 years. Physical examination was positive for sensorineural hearing loss on the right. Her gait was wide-based and shuffling. Axillary freckles and café au lait spots were present. Biopsy of a raised lesion on the chest wall revealed a neurofibroma. Audiometric testing disclosed moderate sensorineural hearing loss on the right and mild loss on the left. A CT scan revealed a large, enhancing left cerebellopontine angle (CPA) mass compressing the fourth ventricle and eroding the left internal auditory canal (Figs. 1A and 1B). Multiple calcifications were present in or over the folia of the right cerebellar hemisphere, without abnormal enhancement in that region (Figs. 1C and 1D).

A CT air cisternogram was performed to exclude right-sided intracanalicular pathology. This study revealed a small acoustic neuroma filling the right internal auditory canal and bulging slightly into the right CPA cistern, with thickening of the cisternal portion of the eighth cranial nerve (Fig. 1E). The patient underwent a suboccipital craniotomy for debulking of the left CPA tumor; the surgical pathology was acoustic neuroma.

Case 2

A 31-year-old man was evaluated elsewhere 10 years previously for decreased hearing in the left ear. A diagnosis of otosclerosis was

made at that time. The left-sided hearing loss progressed, and there was new onset of decreased hearing on the right. Physical examination was now positive for bilateral cochlear nerve dysfunction and for multiple raised skin lesions of the face and trunk. Biopsy of one of these revealed neurofibroma. There were no café au lait spots. Audiometrics revealed profound sensorineural hearing loss in the left ear and moderate loss on the right. CT scanning showed bilateral enhancing CPA masses, larger on the right, and associated funneling of the internal auditory canals (Fig. 2A). There was also a laminated type of calcification in the lateral right cerebellar hemisphere (Fig. 2B) not associated with abnormal enhancement or mass lesion. The patient declined surgery on the presumed acoustic neuroma on the right because of the possibility of becoming totally deaf.

Discussion

The cases illustrated by CT in this report demonstrate an interesting association of bilateral acoustic neuromas, peripheral neurofibromatosis, and unilateral calcification in the cerebellar folia. Three reports have described the cranial CT findings in central neurofibromatosis in recent years [2-4]. The series by Jacoby et al. [3] illustrated one case of a unilateral cerebellar hemispheric calcification with a pattern and location similar to that seen in our two cases. In the case reported by Jacoby et al., there was no association with acoustic neuromas but there was an optic nerve sheath meningioma.

The pathology literature describes an entity known as meningoangiomatosis in association with central neurofibromatosis [5-7]. In this condition there is an infiltration of meningotheelial cells and small blood vessels into the cortex, and it is most frequently seen in the frontal and temporal lobes [6]. Grossly, the cortex is granular and firm and associated with leptomeningeal thickening [7]. Psammomatous calcification may be seen in the brain or meninges, and more frequently occurs in the latter [7]. Meningoangiomatosis has been likened to a meningioma en plaque, which infiltrates the brain by way of perforating blood vessels [7]. However, the proliferating cells do not behave in a malignant fashion and are more compatible with a hamartomatous process. Occasional cases of meningoangiomatosis have been seen at

Received August 1, 1985; accepted after revision October 22, 1985.

¹ All authors: Department of Radiology, University of Texas Health Science Center, Houston, Texas 77030.

² Present address: Division of Diagnostic Imaging, Department of Diagnostic Radiology, The University of Texas M. D. Anderson Hospital and Tumor Institute at Houston, 6723 Bertner Ave., Houston, TX 77030. Address reprint requests to P. Van Tassel.

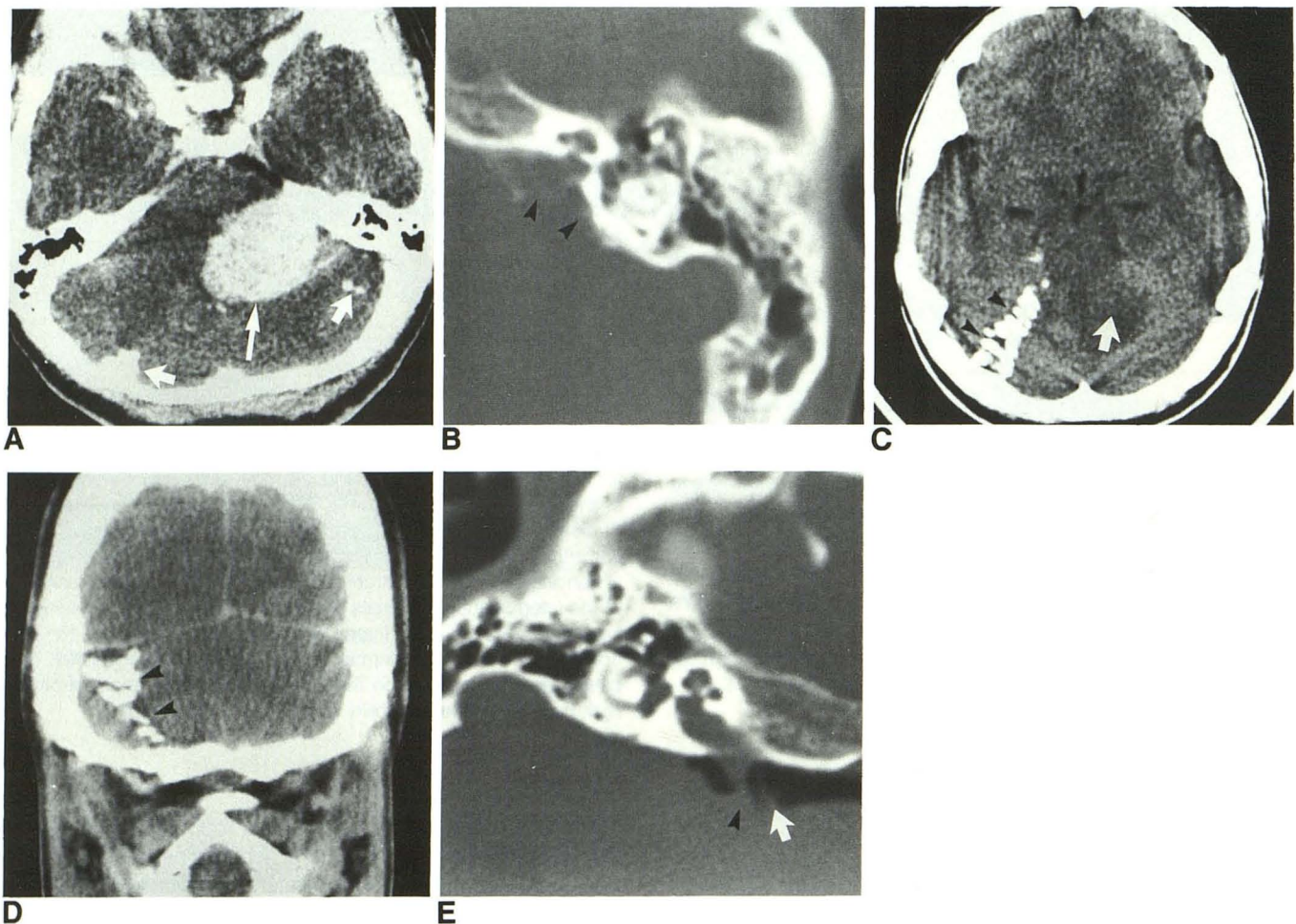


Fig. 1.—Case 1. Bilateral acoustic neuromas and cerebellar calcifications.

A, Postcontrast scan demonstrating enhancing left cerebellopontine angle mass compressing fourth ventricle (*thin arrow*) and portions of cerebellar calcifications (*thick arrows*).

B, Erosion of posterior wall of left internal auditory canal (*arrowheads*) by acoustic neuroma.

C, Precontrast scan at a higher level than part A shows multiple layered calcifications peripherally in or over folia of right cerebellar hemisphere (*arrowheads*). Arrow indicates upper extent of left cerebellopontine angle tumor and edema.

D, Postcontrast coronal scan shows depth of cerebellar calcifications (*arrowheads*) and no abnormal associated enhancement or mass effect.

E, CT air cisternography reveals an intracanalicular tumor on right, which also involves cisternal portion of 8th cranial nerve (*arrowhead*). Arrow indicates 7th cranial nerve.

autopsy unassociated with neurofibromatosis [6]. Jacoby et al. [3] thought that the cerebellar calcification in their case represented a hamartomatous lesion. It is our opinion that the cerebellar calcifications in our two cases of central neurofibromatosis are also most likely secondary to meningoangiomatosis.

Another condition that may produce a similar CT appearance of layered cerebellar calcification is lead poisoning (Fig. 3). Graham et al. [8] reported a higher frequency of cerebellar calcification and plumbism in Queensland, Australia, than elsewhere in the world and remarked that cerebellar folial calcification appears to be a marker for lead poisoning. They described cerebellar calcification in 24 of 2019 cranial CT scans reviewed, and reported that in these 24 there was either documented lead exposure or a strong suggestion of such from renal function abnormalities or environmental fac-

tors. In 23 of the 24 cases there were bilateral, curvilinear cerebellar calcifications. In mild cases the calcification was near the midline in the folia, producing transverse linear densities. In the more florid cases there was diffuse calcification throughout both cerebellar hemispheres. Isolated dentate nucleus calcification was not seen. Lead appears to be a stimulus for deposition of sialopolysaccharides within the walls of cerebellar vessels and around them, and calcium is later bound to the polysaccharides [9].

There was no known history of lead intoxication in the two cases reported here. The fact that the calcification in our cases was largely unilateral and asymmetrical, as well as being located somewhat peripherally in the cerebellum, should distinguish it from the calcification of lead poisoning. The appearance of the cerebellar calcification in this report is also distinct from that seen in hypoparathyroidism, pseudohypo-

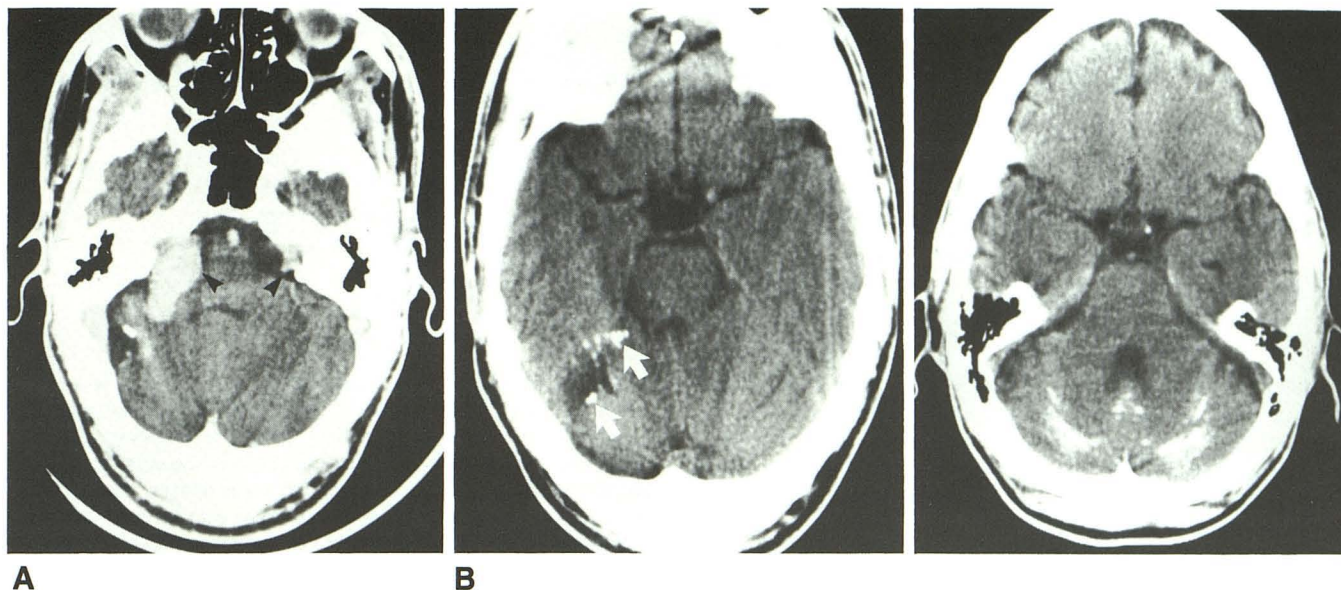


Fig. 2.—Case 2. Bilateral acoustic neuromas and cerebellar calcification.
A, Postcontrast scan showing bilateral enhancing cerebellopontine angle masses (arrowheads), larger on the right, and funneling of internal auditory canals.
B, Precontrast scan demonstrating layered calcification (arrows) peripherally in or over right cerebellar folia. There is associated widening of right cerebellar cisternal space.

Fig. 3.—Cerebellar calcification in a patient with a history of occupational exposure to lead. Bilateral, symmetrical calcification is seen in cerebellar hemispheres near midline and also in vermis.

parathyroidism, and physiologic cerebellar calcification. In these instances the calcification is located bilaterally in the dentate nuclei and corpus medullaris region [10]. There was no known abnormality of calcium metabolism in either of the two patients in this report. There was also no history of previous ischemic insult or trauma to the cerebellar region in either patient, and no neurologic symptoms were present prior to the onset of hearing loss. The CT findings did not suggest that the cerebellar calcifications were part of a mass lesion.

In conclusion, meningoangiomatosis is a known associated finding in central neurofibromatosis in the pathologic literature. It is thought to be the most likely cause of the calcifications observed in the two cases in this report, although pathologic correlation was not obtained. High-resolution CT scanning could be expected to detect meningoangiomatosis when psammomatous calcification is present. When this entity occurs in the cerebellum, a pattern of peripheral, essentially unilateral, calcification over or in the folia may permit its distinction from other causes of cerebellar calcification such as lead poisoning, hypoparathyroidism, pseudohypoparathyroidism, and physiologic calcification. Demonstration of such calcification may help confirm a diagnosis of central neurofibromatosis when other stigmata of this disease are present

intracranially. It might also stimulate a careful search for bilateral acoustic nerve tumors.

REFERENCES

1. Casselman ES, Miller WT, Lin SR, Mandell GA. Von Recklinghausen's disease: incidence of roentgenographic findings with a clinical review of the literature. *CRC Crit Rev Diagn Imaging* 1977;9:387-419
2. Salvolini U, Pasquini U, Babin E, Gasquez P. Von Recklinghausen's disease and computer tomography. *J Belge Radiol* 1978;61:313-318
3. Jacoby CG, Go RT, Beren RA. Cranial CT of neurofibromatosis. *AJR* 1980;135:553-557, *AJNR* 1980;1:311-315
4. Gardeur D, Palmieri A, Mashaly R. Cranial computed tomography in the phakomatoses. *Neuroradiology* 1983;25:293-304
5. Worster-Draught C, Dickson WEC, McMenemey WH. Multiple meningeal and perineural tumors with analogous changes in the glia and ependyma (neurofibromatosis). *Brain* 1937;60:85-117
6. Kepes JJ. *Meningiomas*. New York: Masson Monographs in Diagnostic Radiology, 1982:134-148
7. Russell DS, Rubinstein LJ. *Pathology of tumors of the nervous system*, 4th ed. Baltimore: Williams & Wilkins, 1977:48-55
8. Graham J, Jaysinghe L, Baddeley H. Cerebellar calcification. *Diagn Imag* 1981;50:99-106
9. Saal JR, Coombe IF, Thomas BW, Tonge JI, Burry AF. Cerebellar calcification—ultrastructure and histochemistry. *Pathology* 1978;10:351-363
10. Koller WC, Klawans HL. Cerebellar calcification on computerized tomography. *Ann Neurol* 1980;7:193-194