



## Discover Generics

Cost-Effective CT & MRI Contrast Agents



WATCH VIDEO

# AJNR

### **"Truncation" artifact in MR images of the internal auditory canal.**

D L Daniels, L F Czervionke, R K Breger, J A Strandt, L E Hendrix, R Falk, K W Pojunas, A L Williams and V M Houghton

*AJNR Am J Neuroradiol* 1987, 8 (5) 793-794

<http://www.ajnr.org/content/8/5/793>

This information is current as of June 21, 2025.

# "Truncation" Artifact in MR Images of the Internal Auditory Canal

David L. Daniels<sup>1</sup>  
 Leo F. Czervionke  
 Robert K. Breger  
 Julie A. Strandt  
 Lloyd E. Hendrix  
 Robert Falk  
 Kathleen W. Pojunas  
 Alan L. Williams  
 Victor M. Haughton

Dry skulls and a phantom were studied to determine whether an intracanalicular dark band in MR images of some acoustic neuromas could be artifactual. A "truncation" artifact was detected in the internal auditory canals of the dry skulls and in a simulated internal auditory canal of the phantom when the width of the canal approximately equaled  $4 \times (\text{field of view}) / N$ , where  $N$  equals 128 or 256, depending on the number of gradient steps chosen.

The "truncation" artifact should not be confused with CSF between normal nerves when a canal contains tumor.

In evaluating MR images of the temporal bone, we observed an intracanalicular, central, thin, dark band nearly transversely oriented in some acoustic neuromas, especially small ones (Fig. 1) [1]. At surgery, no anatomic correlate of these bands was identified. The tumors were found to be solid, with no cystic regions or calcification. A "truncation" artifact has been described in detail [2]. Briefly, this artifact appears as a series of equidistant dark lines or curves parallel to a high-contrast interface, gradually becoming less obvious the further the lines or curves are from the interface. With a  $128 \times 256$  matrix, the artifact is more prominent at the interfaces that are perpendicular or nearly so to the 128 direction. Between parallel high-contrast interfaces, such as vertebral endplates, the "truncation artifact" may appear as a central, transversely oriented, thin, dark band because of the overlapping of artifactual bands arising from each margin. For the artifact to be conspicuous in the center of the space, the width of the space must approximately equal  $4 (\text{field of view}) / N$ , where  $N$  equals 128 or 256, depending on the number of gradient steps chosen (Breger R and Haughton V, unpublished data). To test whether the dark band could be caused by a "truncation" artifact, we used MR imaging to study dry skulls and a phantom immersed in a  $\text{CuSO}_4$  solution.

## Materials and Methods

In two series of studies, dry skulls with normal internal auditory canals and with canals widened with a Dremel Moto-tool were placed in a plastic dish containing water doped with copper sulfate (0.1 mmol/l) and then evaluated with MR.

A phantom was designed to simulate an internal auditory canal. Two polyethylene plastic containers were filled with corn oil and positioned in the plastic dish containing  $\text{CuSO}_4$  solution so that they formed an acute angle. MR studies were then performed.

Technical factors for the MR images included 3-mm-thick contiguous head-coil images, axial and coronal sections, repetition time (TR) of 600 msec, echo times (TE) of 20 and 40 msec, fields of view of 12, 16, and 20 cm, one or four excitations (NEX 1 or 4), and a  $128 \times 256$  matrix without and with gradient reversal. MR images were obtained with a 1.5-T GE Signa system.

Received February 5, 1987; accepted after revision April 11, 1987.

<sup>1</sup> All authors: Department of Radiology, Medical College of Wisconsin, Froedtert Memorial Lutheran Hospital, 9200 W. Wisconsin Ave., Milwaukee, WI 53226. Address reprint requests to D. L. Daniels.

AJNR 8:793-794, September/October 1987  
 0195-6108/87/0805-0793

© American Society of Neuroradiology

## Results

All MR images demonstrated a midline, thin, transverse, dark band in the internal auditory canals of the dry skulls and in the angle formed by the phantom when the field of view and gradient steps were chosen so that the width of the canal or space approximately equaled  $4 \times (\text{field of view})/N$  (Figs. 2-4). The band was best seen when the long axis of the

canal or space was nearly parallel to the 128 direction. Better seen in the phantom were dark bands adjacent to each margin and a short central dark band representing the overlapping of bands.

## Discussion

In a series of 15 tumors that involved the internal auditory canal, a dark band was seen in five cases and tended to obscure the acoustic neuroma in one [1]. Many of these bands are consistent with a "truncation" artifact. To one observer, the band suggested CSF between normal cranial nerves. While the full intracanalicular extent of the acoustic neuroma was not seen by the observer, the tumor in the canal was subsequently seen after IV gadolinium administration. Tumor extending to the apex of the canal was verified surgically. We conclude that the effect of the "truncation" artifact should be recognized.

## ACKNOWLEDGMENTS

We thank Jeff Smith, Jacob Biller, and Bradley Berger for their help in performing this study.

## REFERENCES

1. Daniels DL, Millen SJ, Meyer GA, et al. MR detection of tumor in the internal auditory canal. *AJNR* 1987;8:249-252, *AJR* 1987;148:1219-1222
2. Lufkin RB, Pusey E, Stark DD, Brown R, Leikind B, Hanafie WN. Boundary artifact due to truncation errors in MR imaging. *AJR* 1986;147:1283-1287

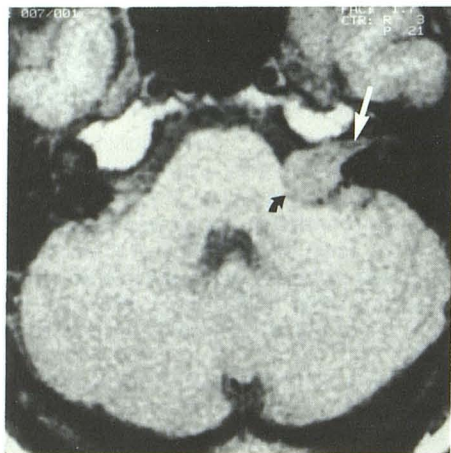


Fig. 1.—Short TR/TE image reveals a thin dark band (straight arrow) in internal auditory canal of a patient with a solid acoustic neuroma (curved arrow) that filled the canal (surgically verified). The band had no anatomic correlate at surgery.

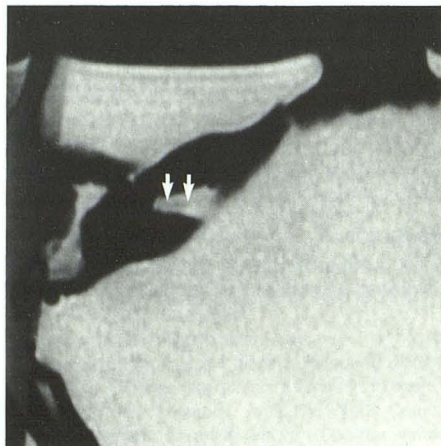


Fig. 2.—Axial short TR/TE image, 12-cm field of view. Thin, dark, central band (arrows) represents a "truncation" artifact in flared internal auditory canal of a dry skull.

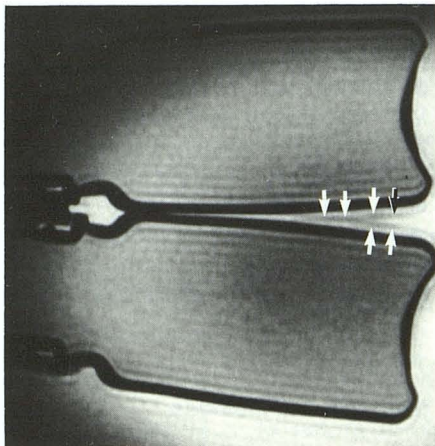


Fig. 3.—Coronal short TR/TE image, 16-cm field of view. Dark band (arrows) in center of normal-sized internal auditory canal is artifactual.

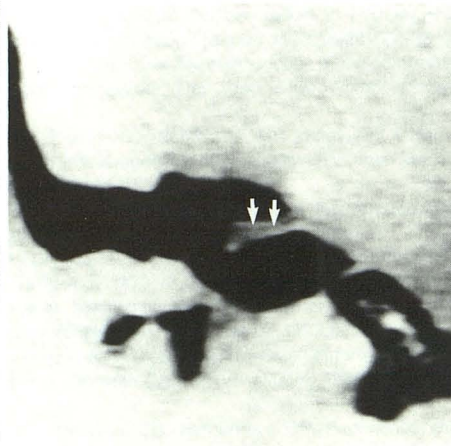


Fig. 4.—Short TR/TE image, 12-cm field of view, of phantom consisting of plastic bottles positioned to form a space simulating an internal auditory canal. In the space, dark bands (arrows) adjacent to each interface overlap in the center. The image was obtained with gradient reversal (i.e., the 128 direction is in the y axis). Note the "truncation" artifacts are more prominent at interfaces nearly perpendicular to the 128 direction.