



## Discover Generics

Cost-Effective CT & MRI Contrast Agents



FRESENIUS  
KABI

WATCH VIDEO

# AJNR

## Intraoperative sonography of a spinal cord arteriovenous malformation.

J M Rubin and J E Knake

*AJNR Am J Neuroradiol* 1987, 8 (4) 730-731

<http://www.ajnr.org/content/8/4/730.citation>

This information is current as  
of June 10, 2025.

# Intraoperative Sonography of a Spinal Cord Arteriovenous Malformation

Jonathan M. Rubin,<sup>1</sup> and James E. Knake

Spinal cord arteriovenous malformations (AVMs), although comparatively rare, are important because of their potential to be cured surgically. Yet they are often undiagnosed preoperatively because of their protean natural history [1]. Preoperative myelography and/or CT scanning may demonstrate only a mass without other clues to the vascular nature of the lesion, thus not prompting a definitive spinal angiogram. Intraoperative sonography provides a means to evaluate the spinal cord and subarachnoid space before incising the dura mater and performing a potentially dangerous myelotomy or exploratory cord retraction. We report a case of an unsuspected spinal AVM in which intraoperative sonography played a significant diagnostic role.

## Case Report

A 30-year-old woman had a 7-year history of insidious onset of numbness of the fourth and fifth digits of her left hand progressing to include her entire hand. There was some lower extremity numbness and weakness as well. Cervical myelography showed high cervical spinal cord expansion with a C1–C2 level intramedullary cyst that filled with metrizamide immediately during the injection (Figs. 1A and 1B). Levels above C1 could not be evaluated myelographically, but a spinal CT scan performed immediately after the myelogram showed a thinned cervical spinal cord and confirmed the presence of an intramedullary cyst (Fig. 1C). There was no convincing evidence of an intracranial abnormality. A delayed CT scan showed the upper cervical focal expansion, but the cyst no longer retained sufficient metrizamide to outline it (Fig. 1D). A cervical laminectomy was performed, and intraoperative sonography performed with a 7.5-MHz transducer demonstrated an expanded upper cervical spinal cord containing a 1 × 2.5-cm cystic space (Fig. 2) [2]. Cephalad to the cyst was a complex 1.5-cm intramedullary mass that pulsated prominently at the cardiac rate. Cephalad to the mass was a second larger cyst above the cervicomedullary junction. This more cephalad cyst had not been suspected preoperatively, apparently because it retained just enough metrizamide to make it virtually isodense with brainstem on CT. Its discovery prompted extension of the surgical

exposure to a suboccipital craniotomy. The two cysts, both containing brownish fluid, and the pulsatile mass, an AVM, were removed.

## Discussion

Spinal AVMs can be quite challenging to neurosurgeons. Those that are dorsal and of the low-flow type can frequently be identified and completely removed. However, intramedullary or ventral components, usually associated with the high-flow type, can be more challenging. Precise localization is paramount in dealing with these lesions [1]. Spinal angiography, the imaging test of choice in evaluating AVMs, can be dangerous and may not be performed if there is not sufficient suspicion that an AVM is present.

In this case, intraoperative sonography provided additional useful information to the neurosurgeon. The solid, intramedullary AVM was immediately localized. By its marked pulsations, the neurosurgeon and sonographer realized that they were dealing with an unusual lesion. Although oscillations induced by spinal lesions compressing the anterior spinal artery have been observed by sonography [3, 4], primary pulsations of a mass have not been described. In this case, the lesion was clearly increasing and decreasing in volume. The larger, more cephalad cyst was not suspected at all before sonography. However, once it was identified, the neurosurgeon extended the laminectomy to a suboccipital craniectomy in order to resect this cyst along with the rest of the lesion.

## REFERENCES

1. Ommaya AK. Spinal arteriovenous malformations. In: Wilkins RH, Rengachary SS, eds. *Neurosurgery*. New York: McGraw-Hill, 1985:1495–1499
2. Knake JE, Gabrielsen TO, Chandler WF, Latack JT, Gebarski SS, Yang PJ. Real-time sonography during spinal surgery. *Radiology* 1984;151:461–465
3. Jokich PM, Rubin JM, Dohrmann GJ. Intraoperative ultrasonic evaluation of spinal cord motion. *J Neurosurg* 1984;60:707–711
4. Rubin JM, Dohrmann GJ. The spine and spinal cord during neurosurgical operations: real-time ultrasonography. *Radiology* 1985;155:197–200

Received May 23, 1985; accepted after revision September 8, 1985.

<sup>1</sup> Both authors: Department of Radiology, University of Michigan Hospitals, Ann Arbor, MI 48109. Address reprint requests to J. M. Rubin.



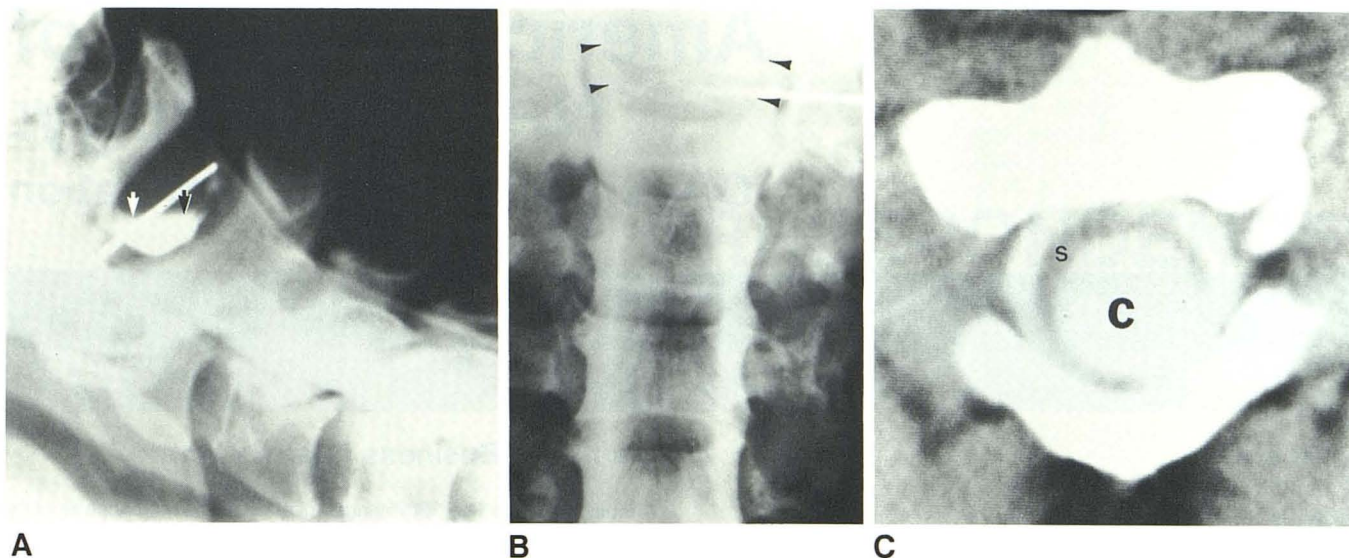


Fig. 1.—A, Cervical metrizamide myelogram, spot lateral view, with patient prone. Upper cervical spinal cord appears widened, and metrizamide has pooled in an intramedullary cavity, producing a fluid/fluid level (arrows).

B, Posteroanterior myelogram. Expansion of cord at level of needle is faintly visible (arrowheads). There are no prominent or tortuous blood vessels.

C, Axial CT image at C2 level (patient supine) defines full diameter of intramedullary smooth-walled cyst (C) and confirms the expanded, thinned nature of surrounding spinal cord (S).

D, Sagittal reconstruction from delayed postmyelographic axial CT images. Spinal cord is focally expanded at C2 (arrows), corresponding to more caudal cyst. In retrospect, there may be subtle lucency suggesting the large intracranial cyst just above foramen magnum. B = basion; O = opisthion.

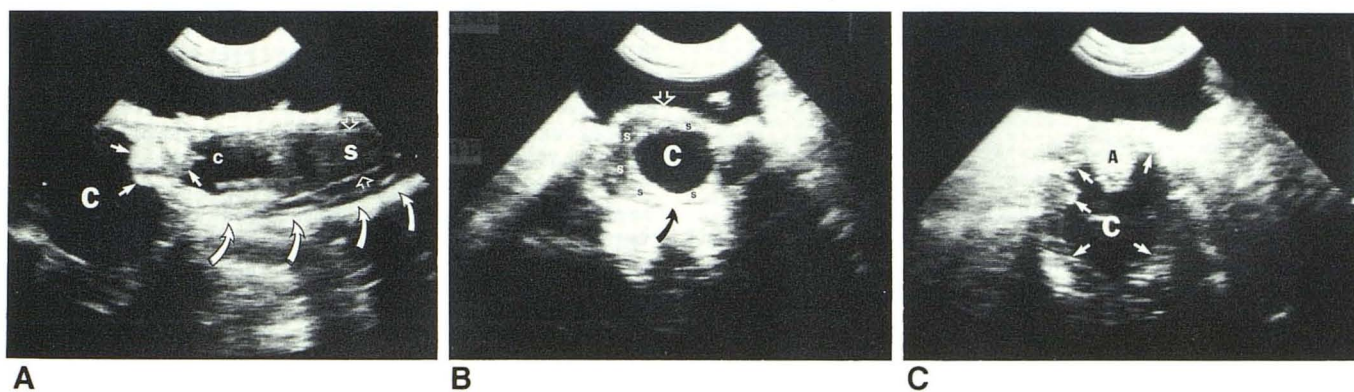
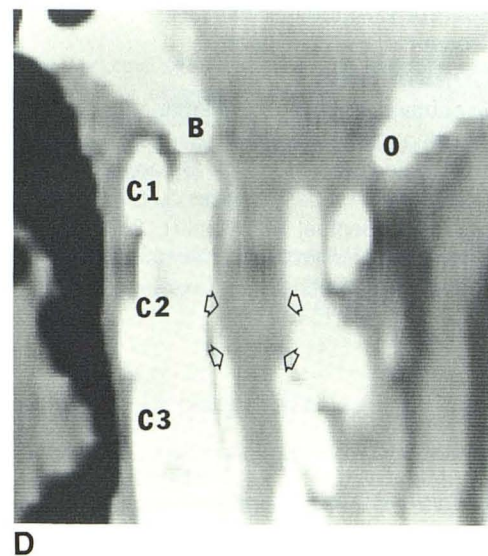


Fig. 2.—A, Longitudinal intraoperative sonogram (cephalad to left, dorsal at top) showing intramedullary AVM delineated by small arrows. Large cephalad cyst (C) and smaller caudal cyst (c) are seen. The more normal, echogenic spinal cord (S) is seen inferiorly. Anterior and posterior edges of spinal cord are marked (open arrows). Note how diameter of spinal cord decreases as it goes inferiorly. Strong reflections from posterior surfaces of several vertebral bodies (curved arrows) are seen ventrally.

B, Transverse scan (patient's right on left side of image, dorsal at top of image) showing caudal spinal cord cyst (C). Spinal cord completely fills subarachnoid space. A rim of residual spinal cord tissue (s) is present around cyst. Spinal cord is more thinned on left than on right, consistent with CT scan. Posterior dural surface (open arrow) and posterior surface of a vertebral body (curved arrow) are labeled for reference.

C, Transverse scan demonstrating cephalad cyst (C) with a rim of tissue around it (arrows). The slice is somewhat oblique, and a portion of the AVM (A) is visible on dorsal surface.