



Discover Generics

Cost-Effective CT & MRI Contrast Agents



WATCH VIDEO

AJNR

Cerebral venous distention associated with cardiac failure in infants.

M A Kuharik and M K Edwards

AJNR Am J Neuroradiol 1987, 8 (4) 657-659

<http://www.ajnr.org/content/8/4/657>

This information is current as
of June 22, 2025.

Cerebral Venous Distention Associated with Cardiac Failure in Infants

Michael A. Kuharik¹
Mary K. Edwards

Three infants with congestive cardiac failure demonstrated dilated and hyperdense intracranial veins and sinuses on noncontrast cranial CT. Intracranial venous thrombosis and arteriovenous malformation were excluded in two infants by autopsy and in one infant by MR imaging. We believe the CT findings were secondary to an elevated central venous pressure caused by the cardiac failure. This CT pattern suggests venous congestive failure, and it should alert the clinician and radiologist to the risk of subsequent sinus thrombosis.

A previously unreported CT pattern of central venous distention in three infants with congestive cardiac failure is described. An arteriovenous malformation (AVM) or dural sinus thrombosis may create a similar CT pattern, but the clinical history of the three infants in this series favored congestive failure as the cause. Autopsy correlation was available in two cases. Sinus thrombosis and AVM were excluded in the third case by MR imaging. We present and discuss the three cases, review the literature on dense, nonthrombosed dural sinuses, and speculate on a possible mechanism.

Subjects and Methods

The cranial CT examinations of the three infants were performed on either a Picker 1200 SX or a Technicare HPS 1440. The MR images in one case were obtained on a Technicare Teslacon operating at 0.15 T, using a spin-echo technique. Relatively T1- and T2-weighted images were obtained with a TR of 550 msec and a TE of 32 msec (550/32), and with a TR/TE of 2000/120, respectively. The two autopsies were performed by the Indiana University Medical Center, Department of Pathology. In each case, the clinical presentation, hospital course, and laboratory and consultation results were obtained from the hospital records.

Case Reports

Case 1

An 8-hour-old boy was transferred to the medical center after an uncomplicated cesarean section. The infant was hypotonic and cyanotic, requiring intubation. Cardiology consultation revealed congenital heart disease, including dextrocardia, pulmonary stenosis, and atrial septal defect. By age 4 days he was exhibiting signs of biventricular congestive heart failure. A cranial CT without contrast, obtained at age 5 days, demonstrated a hyperdense (relative to the brain) and dilated vein of Galen and straight, transverse, superior sagittal, and inferior sagittal sinuses (Fig. 1A). These findings raised the possibility of intracranial venous sinus thrombosis or AVM. A contrast-enhanced cranial CT scan demonstrated intense enhancement of these dilated intracranial veins and sinuses (Figs. 1B and 1C) without evidence of intraluminal filling defects or thrombosis. Because of the abnormally large size of these vessels, a vascular malformation was considered, but venous distention secondary to cardiac failure was favored. The cardiac failure worsened, the infant developed bilateral pulmonary infiltrates, and died at age 16 days. An autopsy performed the same day demonstrated

Received August 22, 1986; accepted after revision November 25, 1986.

¹ Both authors: Department of Radiology, Indiana University School of Medicine, Indianapolis, IN 46202. Address reprint requests to M. K. Edwards.

AJNR 8:657-659, July/August 1987

0195-6108/87/0804-0657

© American Society of Neuroradiology

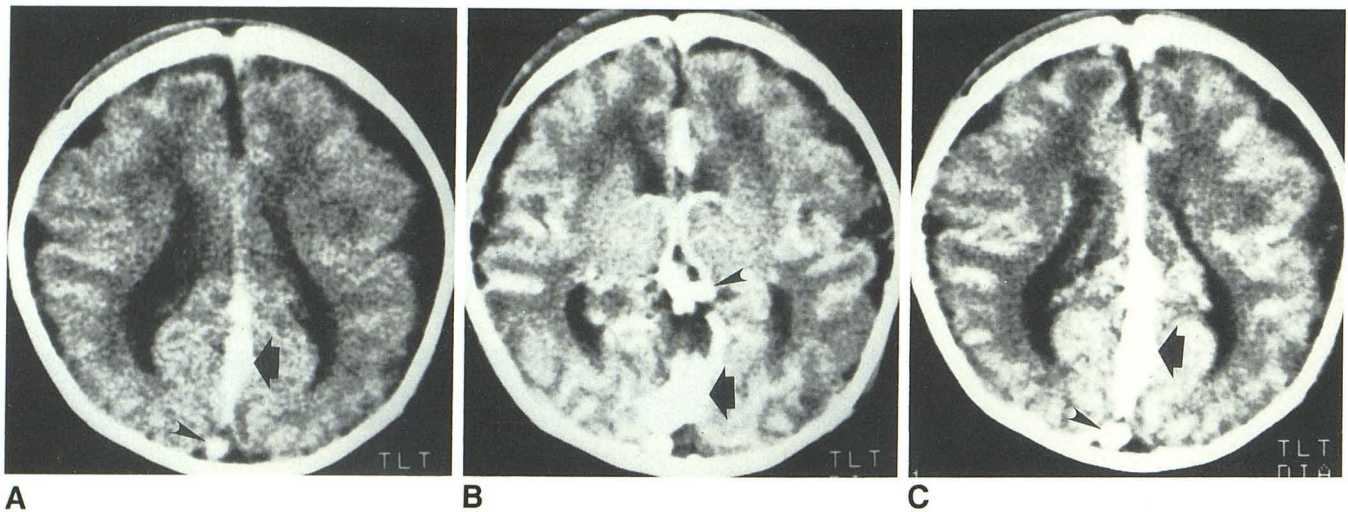


Fig. 1.—Case 1. 5-day-old boy.

A, Noncontrast cranial CT. Note presence of hyperdense, dilated inferior sagittal sinus (*thick arrow*) and superior sagittal sinus (*arrowhead*).

B and C, Contrast cranial CT. Intense contrast enhancement of dilated straight sinus (B, *thick arrow*), vein of Galen (B, *arrowhead*), superior sagittal sinus (C, *arrowhead*), and inferior sagittal sinus (C, *thick arrow*) without filling defects or thrombosis.

cardiac anomalies, including common atria and a hypertrophied right ventricle. There was evidence of pulmonary and liver congestion secondary to the elevated pulmonary and systemic venous pressures. Intracranially, there was no evidence of an AVM or venous sinus thrombosis, but a dilated inferior sagittal sinus was found.

Case 2

A 7-day-old girl was brought to the emergency room by ambulance in complete cardiac arrest. According to the infant's mother, the child was found cyanotic and without respirations lodged between her bed and the wall after falling out of bed. Forms of suspicion of child abuse were filed at that time. Upon arrival to the emergency room, the infant was intubated and countershock was performed, which initiated a sinus rhythm. Physical examination revealed fixed and dilated pupils, no spontaneous respirations, and lack of withdrawal to painful stimulus. A noncontrast cranial CT scan was obtained and demonstrated dilated and hyperdense vein of Galen and straight, transverse, and superior sagittal sinuses (Figs. 2A and 2B). The brain death protocol was initiated the next day. The infant was 10 days old when the mechanical support was removed and she died. An autopsy performed the same day revealed extensive cardiac hemorrhage and necrosis of the posterior walls of the right and left ventricles and intraventricular septum. There were multifocal bilateral posterior pulmonary contusions in all lobes, with congestion. Intracranially, normal venous sinuses were observed without evidence of thrombosis or vascular malformations.

Case 3

This 2-month-old girl was referred to the medical center for evaluation of a heart murmur, edema, and respiratory distress. That evening she required intubation because of worsening pulmonary congestion. Cardiac catheterization was performed the following day and revealed dextrocardia, patent foramen ovale with left to right shunt, and right ventricular dilatation with moderate tricuspid insufficiency. A cranial CT scan was obtained because of changing mental

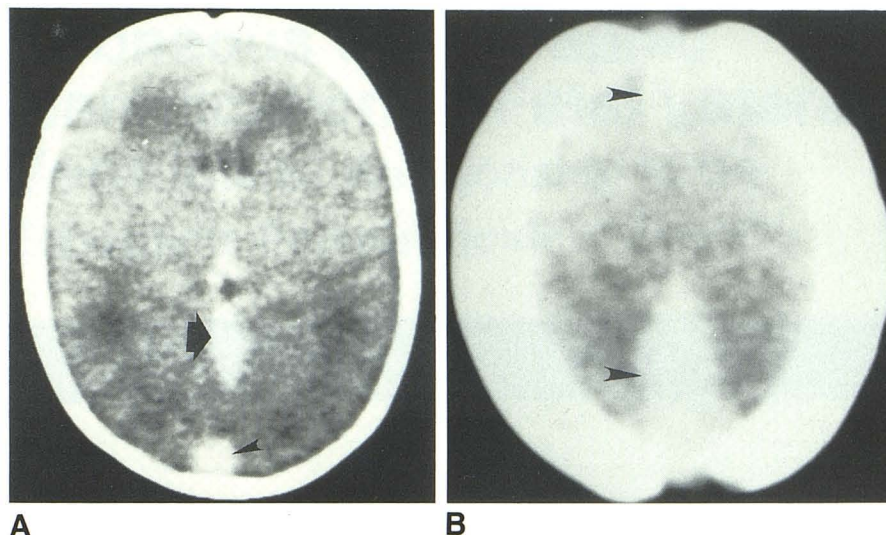
status. The noncontrast scan revealed hyperdense, dilated transverse and superior sagittal sinuses, which raised the question of venous sinus thrombosis. A contrast-enhanced cranial CT scan was not obtained because of the infant's renal failure. Axial and sagittal MR demonstrated lack of signal due to flow artifact in the transverse and superior sagittal sinuses without evidence of filling defect or thrombosis. The cardiac failure slowly responded to therapy, and the patient was extubated the following week. She was subsequently discharged to home on oxygen after a 3-month hospital stay.

Discussion

In all three cases presented, the noncontrast cranial CT examinations demonstrated similar findings—hyperdense and abnormally dilated venous sinuses and intracerebral veins. These findings suggested the possibility of intracranial venous thrombosis, particularly when one considers that congestive failure, a predisposing factor for sinus thrombosis, was present in each infant [1–5]. The possibility of sinus thrombosis can generally be excluded by the demonstration of homogenous contrast enhancement in the central venous sinuses. In our series, further confirmation of the absence of intracranial venous thrombosis was obtained at autopsy or on MR. Both autopsies revealed anatomically normal cranial venous sinuses without intraluminal thrombus. In case 3, MR demonstrated transverse and superior sagittal sinus intraluminal signal loss in both the T1- and T2-weighted images in the axial and sagittal planes, characteristic of rapidly flowing blood [6].

Osborn et al. [7] and Segall et al. [5] reported that elevated density in the region of the vein of Galen, straight, superior sagittal, and inferior sagittal sinuses can be visualized on noncontrast cranial CT scans in "normal" children without a history of trauma or intracranial hemorrhage. These authors inferred that such visualization could be accounted for by the

Fig. 2.—Case 2. 7-day-old girl
A and B, Noncontrast cranial CT. Grossly dilated and hyperdense vein of Galen (A, thick arrow) and superior sagittal sinus (A and B, arrowheads).



circulating blood. However, unlike the three infants presented here, there was no discussion of enlarged or dilated intracranial veins or dural sinuses.

Nelson et al. [8] studied the cranial noncontrast CT scans of 15 patients (11 neonates) with hyperdense dural sinuses in which all had an elevated hematocrit. This dural sinus radiodensity was considered a sign of increased blood viscosity. Again, unlike our cases, they did not describe associated dilated dural sinuses. Also, in each of our three cases, the hematocrit was within normal limits for age.

Each of the three infants presented here had cardiac abnormalities with associated venous congestion. Cases 1 and 3 had congenital cardiac anomalies with a left to right shunt and biventricular cardiac failure. In case 2 the infant sustained severe cardiac contusions of the left and right ventricles resulting in infarction and pump failure. We believe the elevated right heart and systemic venous pressures were transmitted to the intracranial veins and sinuses causing "back pressure" engorgement and dilatation. This dural sinus enlargement was associated with an increase in the relative intraluminal blood volume and was manifest on the noncontrast CT as increased sinus attenuation. The presence of dilated intracranial veins with cyanotic congenital heart disease has been reported as long ago as 1942 [9]. Cottrill and Kaplan [4] studied 29 children with cerebrovascular accidents complicating cyanotic congenital heart disease. They found that almost three-fourths of the children had abnormally dilated and engorged intracranial veins at autopsy. In a large proportion of these children (72%), they found coexistent venous sinus thrombosis.

The presence of dilated, hyperdense intracranial veins or sinuses on noncontrast CT scans in infants with cardiac

abnormalities should suggest congestive dilatation of the dural sinuses in addition to sinus thrombosis and vascular malformation. Contrast-enhanced CT or MR should exclude sinus thrombosis. To our knowledge there have been no previous reports of the CT appearance of dilated intracranial veins or sinuses caused by cardiac failure in infants. Recognition of this CT pattern may aid in the correct diagnosis of cardiac failure. Because of venous stasis, these children are at risk for developing sinus thrombosis, and careful clinical and radiographic monitoring should be performed as long as the venous congestion persists.

REFERENCES

1. Rao KCV, Knipp HC, Wagner EJ. Computed tomographic findings in cerebral sinus and venous thrombosis. *Radiology* 1981;140:391-398
2. Eick JJ, Miller KD, Bell KA, Tutton RH. Computed tomography of deep cerebral venous thrombosis in children. *Radiology* 1981;140:399-402
3. Gabrielsen TO, Seeger JF, Knake JE, Stilwell EW. Radiology of cerebral vein occlusion without dural sinus occlusion. *Radiology* 1981;140:403-408
4. Cottrill CM, Kaplan S. Cerebral vascular accidents in cyanotic congenital heart disease. *Am J Dis Child* 1973;125:484-487
5. Segall HD, Ahmadi J, McComb JG, Zee CS, Becker TS, Hans JS. Computed tomographic observations pertinent to intracranial venous thrombotic and occlusive disease in childhood. *Radiology* 1982;143:441-449
6. Bradley WG, Waluch V. Blood flow: Magnetic resonance imaging. *Radiology* 1985;154:443-450
7. Osborn AG, Anderson RE, Wing SD. The false falx sign. *Radiology* 1980;134:421-425
8. Nelson MD, Thompson JR, Hinshaw DB, Hasso AN. Radiodense dural sinuses: new CT sign in patients at risk for hypoxic insult. *AJNR* 1981;2:545-548
9. Hunter A, Lipscomb JM. Congenital pulmonary atresia with cerebral thrombosis and hemiplegia. *Br Heart J* 1942;4:124-130