



Discover Generics

Cost-Effective CT & MRI Contrast Agents



WATCH VIDEO

AJNR

Actinomycotic granuloma of the trigeminal ganglion.

M Atri, W D Robertson, F A Durity and C L Dolman

AJNR Am J Neuroradiol 1987, 8 (1) 167-169

<http://www.ajnr.org/content/8/1/167.citation>

This information is current as
of June 15, 2025.

Actinomycotic Granuloma of the Trigeminal Ganglion

Mostafa Atri,¹ William D. Robertson,² Felix A. Durity,³ and Clarisse L. Dolman⁴

Actinomycosis is a chronic, suppurative, bacterial disease characterized by extensive fibrosis, occasional granulomas, abscess formation, and sinus discharge containing sulfur granules. In actinomycosis, the CNS is involved in only 3.3% of cases [1]. This report documents an actinomycotic granuloma simulating a trigeminal neuroma clinically, radiologically, and surgically. It is also the first CT report of intracranial actinomycosis that has spread through the perineural space.

Case Report

A 13-year-old boy was investigated for numbness of the right side of his face and headaches. He had a 9-month history of steady aching pain in the right temporal region that spread into the occipital region. The headaches were severe, constant, and unvarying. Four months before hospital admission, the pain spread to the angle of his jaw and subsequently he noticed numbness of the right side of his face and difficulty with chewing. Physical examination revealed a right sixth nerve palsy, a diminished right corneal reflex, and reduction of all modalities of sensation on the right side of his face. Wasting of the temporalis and masseter muscles was present. He was unable to open his mouth fully.

A CT scan performed after contrast infusion demonstrated a bilobed well-defined homogeneously enhancing soft tissue mass in the right middle fossa lying lateral to and separate from the cavernous sinus. A noncontrast CT scan was not obtained. The mass extended into the medial portion of the posterior fossa, lying anterior and medial to the apex of the petrous bone, indenting the lateral border of the pons and widening the adjacent ambient cistern (Figs. 1A and 1B). The mass measured 2.5 cm in anteroposterior diameter, 1.7 cm in transverse diameter, and 2.2 cm in height. Bone settings of the skull base showed enlargement of the right foramen ovale with a well-defined cortical margin (Fig. 1C). A poorly defined enhancing mass in the infratemporal fossa was noted along with loss of the normal fat plane between the lateral pterygoid and temporalis muscles (Figs. 1B and 1D). Right internal and external carotid angiograms were normal.

At surgery, a mass was found extending from the junction of the fifth nerve with the brainstem to the posterior edge of the cavernous sinus, filling Meckel's cave and continuing along the branches of the fifth nerve to the foramen ovale and rotundum. The lesion was initially thought to represent a tumor but, on indenting it, a bead of apparent purulent material was obtained. The intracranial component of the mass was totally removed.

The pathologic specimen consisted of 3 cm³ of multiple firm gray nodular fragments. Microscopy revealed numerous microabscesses embedded in dense fibrous tissue, filled with polymorphonuclear leucocytes and surrounded by proliferating endothelial cells and fibroblasts, lymphocytes, and plasma cells (Fig. 2A). Portions of myelinated nerve entered the mass, which could be identified as trigeminal ganglion by the presence of a few residual ganglion cells. In the center of one of the abscesses lay a typical "sulfur granule," surrounded by club-shaped extensions and staining diffusely with hematoxylin and PAS. Gram and Grocott's methenamine silver stains demonstrated filiform threads, the cocco-bacillary forms characteristic of *Actinomyces* in this colony (Fig. 2B). Ziehl-Nielsen and modified acid-fast stains were negative. No other organisms could be identified in the other microabscesses, and swabs from the lesion at the operation were negative on culture. Although positive culture identification was not obtained, the overwhelming evidence points to the causative organism being *Actinomyces*.

The patient was placed on penicillin, the drug of choice, for 1 year. Clinical examination and follow-up CT scans performed at 9 months and 2 years showed no recurrence.

Discussion

In actinomycosis, the CNS is involved in only 3.3% of cases [1]. The usual pathologic picture of actinomycosis is that of a chronic suppurative, fibrosing, inflammatory process that spreads by contiguity. Small abscesses and pus-filled sinus tracts are characteristic [2]. The gross pathologic process in the CNS may be classified as: (a) localized (i.e., abscesses and neoplastic-like conditions) or (b) diffuse (i.e., meningitis and diffuse extradural involvement with or without concomitant abscess formation); the latter is the more common type of CNS involvement [3]. Meningitis is almost always basal.

Cases of actinomycosis mimicking neoplasm have been reported in the third ventricle [4] as well as in the Gasserian ganglion. In 1951, Maltby [3] described a case of actinomycosis involving the Gasserian ganglion. In 1981, Perna et al. [5] reported a case of actinomycotic granuloma of the Gasserian ganglion with the primary site of infection in a dental rest. Both cases were thought to indicate spread by way of nerve or perineural pathways; neither case had CT.

As far as the mode of CNS invasion is concerned, the

Received November 28, 1984; accepted after revision March 7, 1985.

¹ Department of Radiology, Montreal General Hospital, Montreal, Quebec, Canada.

² Department of Radiology, University of British Columbia, Vancouver, B.C., Canada V5Z 1M9. Address reprint requests to W. D. Robertson, Department of Radiology, Vancouver General Hospital, 855 West 12th Ave., Vancouver, B.C., Canada V5Z 1M9.

³ Division of Neurosurgery, Department of Surgery, University of British Columbia, Vancouver, B.C., Canada V5Z 1M9.

⁴ Division of Neuropathology, Department of Pathology, University of British Columbia, Vancouver, B.C., Canada V5Z 1M9.

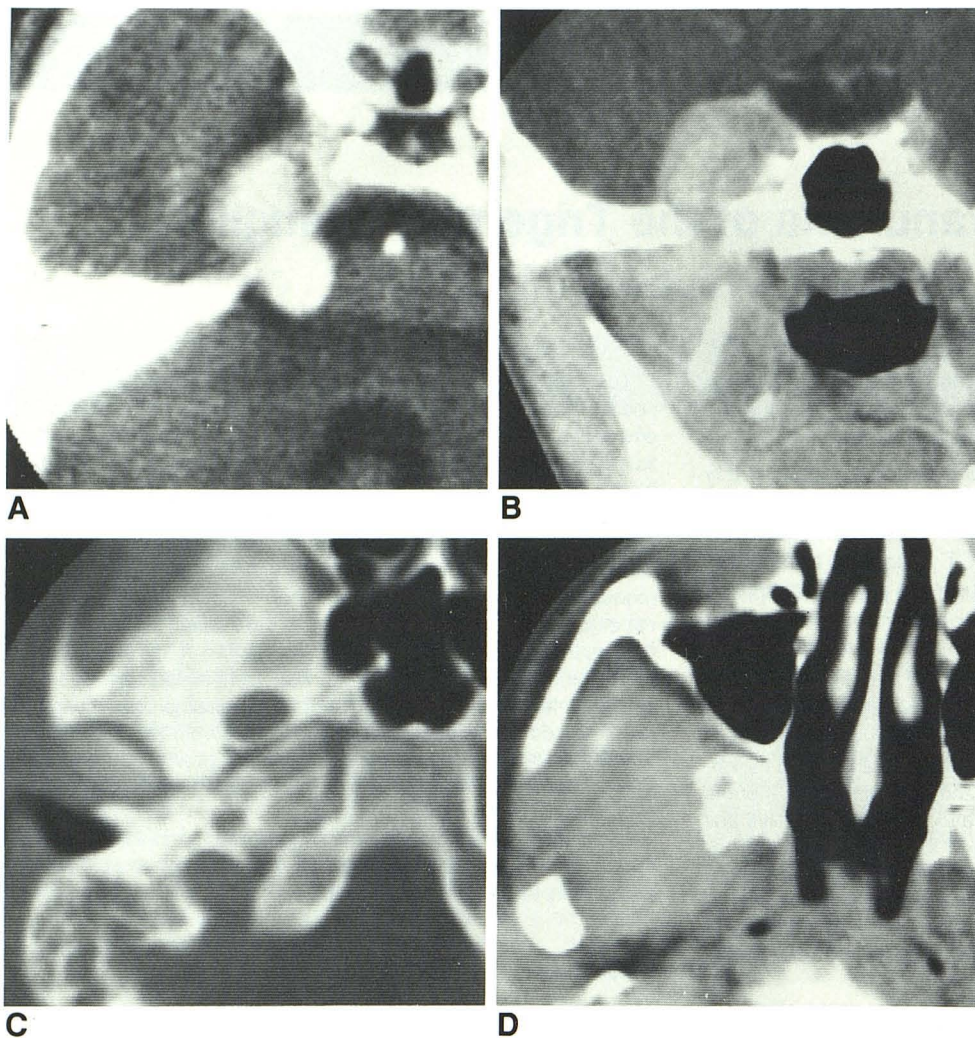


Fig. 1.—Contrast-enhanced CT scans.

A, Bilobed enhancing granuloma of right trigeminal ganglia involving both right middle and posterior fossae.

B, Coronal view showing parasellar location of lesion with extension inferiorly to level of foramen ovale and mild enhancement of infratemporal fossa soft tissues.

C, Bone settings of skull base show enlarged right foramen ovale.

D, Axial view of infratemporal fossa showing poorly defined enhancing mass with loss of fat plane between right lateral pterygoid and temporalis muscles.

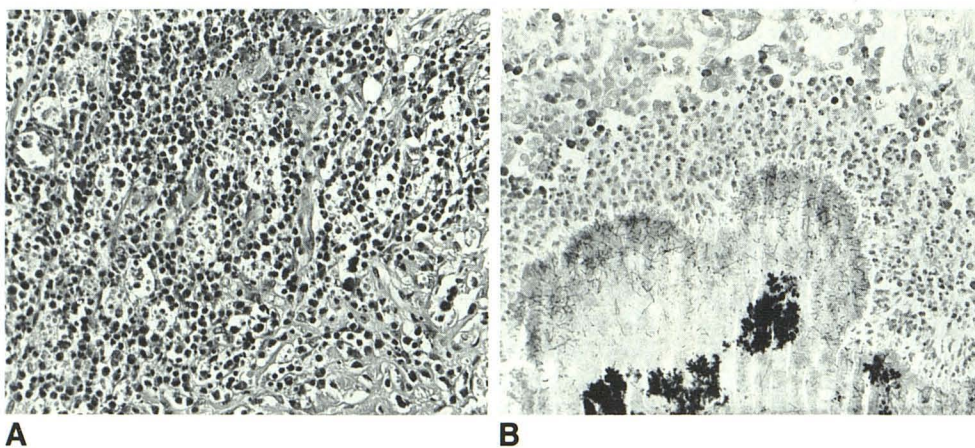


Fig. 2.—A, Within fibrous mass on trigeminal nerve are budding capillaries and sheets of lymphocytes and plasma cells. (H and E $\times 443$.)

B, The "sulfur granule," seen in lower half of picture, has serpiginous edge. In the center lie dense granular aggregates of microorganisms. At the margins the fine threads typical of bacillary forms of *Actinomyces* are seen. A halo of polymorphs surrounds the colony. (Grocott's methenamine silver stain $\times 443$.)

general opinion is that primary actinomycosis of CNS does not exist; if a careful search is carried out, a primary lesion can always be found elsewhere in the body even though it may not be active [3]. Most commonly, the disease reaches

the CNS through the bloodstream from other foci in the body, usually the lung, resulting in brain abscess or meningitis [6]. The second most common route is direct extension from lesions in the paranasal sinuses, ear, pharynx, face, and jaws,

giving rise to basal meningitis that may be associated with cortical abscesses. The spread is usually along connective tissue planes, with entrance to the cranial fossa being gained through the various foramina or, less commonly, directly through bone [6]. In this case, it is postulated the lesion began in the pharynx and spread via the foramen ovale and perineural pathways to involve the trigeminal ganglion.

Orr [4] and Eckhoff [7] have raised the possibility of perineural spread of actinomycosis in cases involving the olfactory bulbs. Cases reported by Gonzalez-Torres [8], Maltby [3], and Perna et al. [5] strongly suggest spread via fifth nerve branches. The present case adds further support to this concept, especially in view of the well-encapsulated extension of disease through the foramen ovale, enlarging this foramen.

The differential diagnosis includes trigeminal neuroma, meningioma, metastatic meningeal disease, and carcinoma of the soft tissues of the skull base extending superiorly. A trigeminal neuroma may occupy the posterior or middle fossa or extend like a dumbbell to both fossae; it has well defined margins, enhances homogeneously, and may enlarge the foramen ovale. However, the presence of infratemporal soft-tissue swelling and poor definition of the fat planes, as in our case, should be a clue to the inflammatory nature of the lesion. Cavernous sinus and parasellar meningiomas may have a similar appearance to the middle fossa component of the lesion and may extend to the skull base; presumably, infratemporal extension would be better defined. Metastatic disease such as neuroblastoma may involve the skull base and may have an extradural or subdural component. Although

nasopharyngeal carcinoma usually spreads intracranially directly through the sphenoid bone, it may also spread via the foramen ovale with a soft-tissue mass present both in the middle fossa and the infratemporal fossa.

In summary, this report describes a rare case of actinomycotic granuloma of the trigeminal ganglion that involved the CNS through perineural pathways. The lesion simulated the clinical, radiographic, and surgical findings of a trigeminal ganglion neuroma.

REFERENCES

1. Causey WA. Actinomycosis. In: Vinken PJ, Bruyn GW, eds. *Handbook of clinical neurology* 35. *Infections of the nervous system*, Part III. Amsterdam: North Holland Publishing, 1978: 383-394
2. Emmons CW, Binford CH, Utz JP, Kwon-Chung KJ. *Medical mycology*, 3rd ed. Philadelphia: Lea & Febiger, 1977:89-102
3. Maltby GL. Intracranial actinomycosis. Report of an unusual case. *J Neurosurg* 1951;8:674-678
4. Orr TG Jr. Actinomycoma of the third ventricle, probably primary. *JAMA* 1945;127:757-758
5. Perna E, Loguori T, Petrone B, Mannarino E. Actinomycotic granuloma of the Gasserian ganglion with primary site in a dental rest. *J Neurosurg* 1981;54:553-555
6. Lewin W, Morgan AD. Actinomycosis of the brain. *J Neurol Neurosurg Psychiatry* 1947;10:163-170
7. Eckhoff NL. Actinomycosis of CNS. Report of two cases. *Lancet* 1941;1:7-8
8. Gonzalez-Torres DM. *Ann Fac Med Sao Paulo* 1939;15:235 (cited in [6]).