



## Discover Generics

Cost-Effective CT & MRI Contrast Agents



WATCH VIDEO

# AJNR

## **Sideways dislocation of the temporomandibular joint meniscus: the edge sign.**

M B Khoury and E Dolan

*AJNR Am J Neuroradiol* 1986, 7 (5) 869-872

<http://www.ajnr.org/content/7/5/869>

This information is current as  
of June 16, 2025.

# Sideways Dislocation of the Temporomandibular Joint Meniscus: The Edge Sign

Maroon B. Khoury<sup>1</sup>  
Edward Dolan<sup>2</sup>

Seventy temporomandibular joint arthrograms of 49 patients with symptoms of internal joint derangement were reviewed. Twenty-three of these arthrograms (33%) were abnormal but atypical for anteriorly dislocated meniscus. The lower temporomandibular joint space had a well-defined edge located inferiorly, which was attributed to pressure from a sideways-dislocated meniscus. We called this appearance the "edge sign." Seven patients with radiologically apparent sideways dislocation were operated on. The meniscus was dislocated laterally in six and medially in one. The incidence of irreducibility and perforation was higher in sideways-dislocated than in anteriorly dislocated menisci.

Temporomandibular joint (TMJ) dysfunction is a common ailment. It is estimated to afflict up to 28% of the adult population [1]. Numerous publications have outlined the techniques and use of arthrography in the evaluation of derangements of the TMJ meniscus [2-7]. According to these reports, the meniscus most commonly dislocates anteriorly and rarely dislocates posteriorly. We have observed on several arthrograms an abnormal appearance of the lower-TMJ space, suggesting sideways dislocation of the meniscus. Sideways dislocation was confirmed at surgery in seven cases. To the best of our knowledge, this type of dislocation has not previously been described in the literature. The radiologic appearance, incidence, and clinical implications of sideways dislocation of the TMJ meniscus are the subject of this report.

## Materials and Methods

Seventy TMJ arthrograms were performed on 49 patients referred to us because of symptoms suggesting internal derangement. Forty-five were women and four were men. The ages ranged from 16 to 50 years. The arthrograms were performed in a conventional manner. Using the preauricular approach with the patient in the lateral position, a 1.5-in. long, 22-gauge needle was used to inject the lower-joint space with a mixture of 60% renographin and 0.1% epinephrine. Spot films were obtained with the mouth closed and during various degrees of opening. The joint was also videotaped while the patient opened and closed the mouth. The upper-joint space was not injected with contrast material. Arthrotomography was not performed routinely because it increases radiation exposure and is unnecessary in most patients. Arthrotomography was reserved for cases in which the position or integrity of the meniscus could not be ascertained on the basis of the standard arthrogram alone.

## Results

The meniscus was in normal position in eight of the 70 joints examined (11%). Thirty-nine menisci were anteriorly dislocated (56%). Eighteen of the 39 (46%) reduced to normal positions on opening the mouth, while 21 (54%) remained dislocated on maximum opening. Five of the 39 menisci (13%) were perforated. All perforated menisci failed to reduce on maximum opening of the mouth.

Received October 23, 1985; accepted after revision February 27, 1986.

<sup>1</sup>Department of Radiology, Duke University Medical Center, Box 3808, Durham, NC 27710. Present address: Radiology Department, St. Louis Regional Medical Center, 5535 Delmar Blvd., St. Louis, MO 63112.

<sup>2</sup>Division of Oral and Maxillofacial Surgery, Box 2955, Duke University Medical Center, Durham, NC 27710. Address reprint requests to E. Dolan.

*AJNR* 7:869-872, September/October 1986  
0195-6108/86/0705-0869

© American Society of Neuroradiology



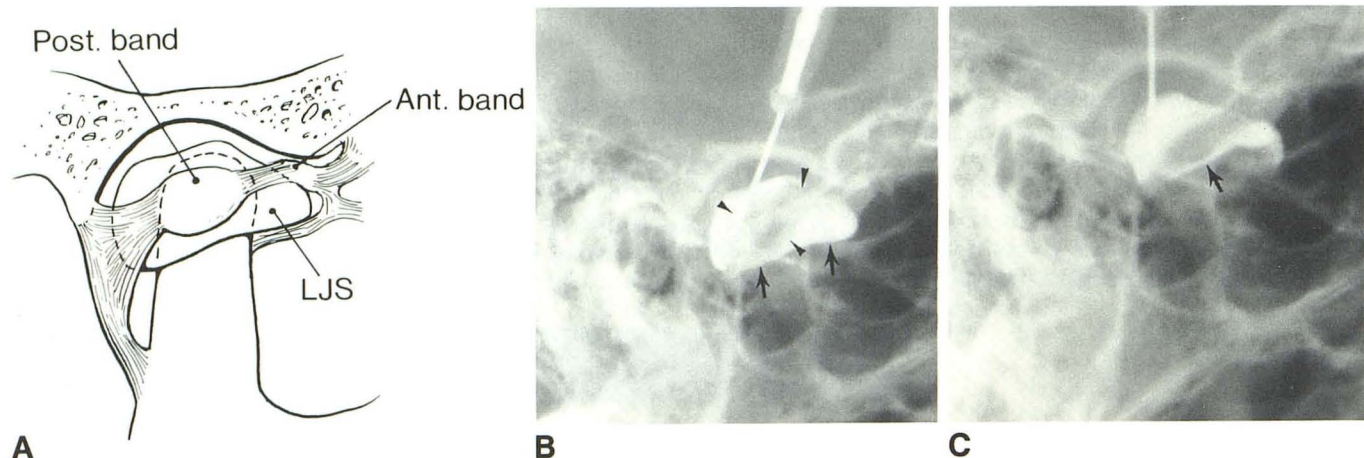


Fig. 1.—A, Schematic representation of sideways dislocation of temporomandibular joint meniscus. Posterior band presses on lower-joint space resulting in sharp delineation of border of meniscus and inferior margin of joint space. B, Arthrogram of a sideways-dislocated meniscus in closed-mouth position.

Meniscus is identified as a filling defect (arrowheads). Inferior margin of contrast-filled lower-joint space is seen as a sharp edge: the "edge sign" (arrows). C, The edge becomes even sharper when mouth is open (arrow).

### *Sideways Dislocation: The "Edge Sign"*

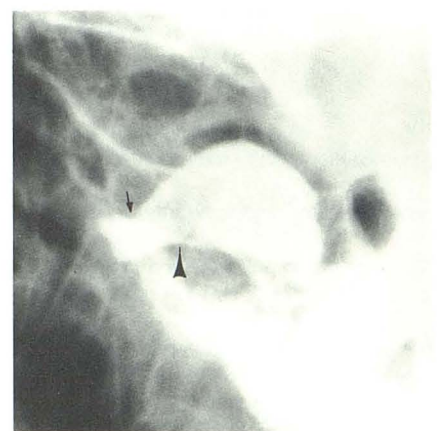
Based on the arthrographic appearance, 23 of the 70 menisci (33%) were judged to be dislocated anteriorly and sideways, or only sideways. The sideways-dislocated meniscus presses on the contrast material in the lateral or medial aspect of the lower-joint space, producing a margin, or an edge (Fig. 1). We called this the "edge sign." The sideways-dislocated meniscus appears as a filling defect surrounded by contrast material. The "edge sign" can appear in combination with the more classic sign of anterior meniscal dislocation, as seen in Figure 2, or it can be the only evidence of a dislocated meniscus.

Of the 23 sideways-dislocated menisci, 21 (91%) did not reduce on maximum opening of the mouth. The meniscus was perforated in nine cases (39%). Seven joints were operated on and the sideways position of the meniscus was surgically confirmed in all seven cases. Six menisci were dislocated laterally and one medially. A variable degree of anterior displacement was present in all cases.

### **Discussion**

The TMJ meniscus is considered to be in normal position when the posterior band (the thickest portion of the meniscus) is situated over the mandibular condyle. The normal lower-joint arthrogram shows no abnormal impression on the anterior recess (Fig. 3). The joint capsule inserts on the condyle and contrast material normally covers the condyle. The inferior limit of the joint, however, is not well defined, and does not have a sharp edge either in the closed- or in the open-mouth position. When the posterior attachment of the meniscus is stretched or torn, the posterior band dislocates anteriorly (Fig. 4). The lower-joint arthrogram shows an abnormal impression on the anterior recess. The inferior border of the lower-joint space remains poorly defined in both the closed- and open-mouth positions.

Fig. 2.—The "edge sign" of sideways-dislocated meniscus (arrowhead) is concomitantly seen with the more familiar impression of anterior meniscal dislocation (arrow).



In 23 of 70 arthrograms (33%), we found an abnormal radiographic appearance dissimilar to the classical description of an anteriorly dislocated meniscus. In these cases, the lower-joint space had a well-defined sharp margin, or edge, located inferiorly. This edge became sharper and better defined on opening the mouth. We called this new finding the "edge sign." We attributed this edge to a sideways-dislocated meniscus pressing on the contrast-filled lower-joint space. The sideways-dislocated meniscus is seen as a filling defect in the lower-joint space surrounded partly or completely by contrast material. The "edge sign" was frequently seen concomitantly with the more familiar impression of an anteriorly dislocated meniscus. In five cases, however, the "edge sign" was the only indication of a dislocated meniscus. Ninety-one percent of sideways-dislocated menisci failed to reduce on maximum opening of the mouth, compared with 54% of anteriorly dislocated menisci. The difference is statistically significant ( $p < 0.005$ ). The incidence of perforation was also higher in sideways-dislocated (39%) than in anteriorly dislocated (13%) menisci. The difference is statistically significant.



Fig. 3.—**A**, Schematic representation of normal anatomy of temporomandibular joint (TMJ) and meniscus. Posterior band of meniscus (pb) is superior to mandibular condyle. **B**, A normal lower-TMJ arthrogram. There is no abnormal impression on contrast-filled lower-joint space (arrow). Notice lack of sharp definition of contrast material overlying condyle.

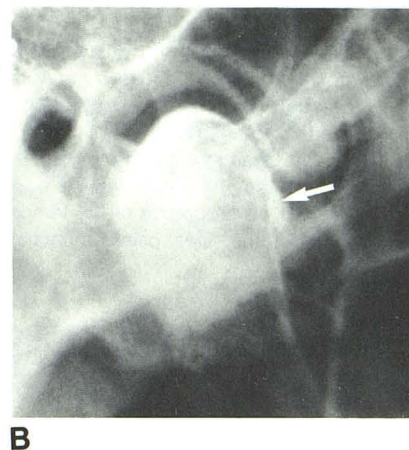
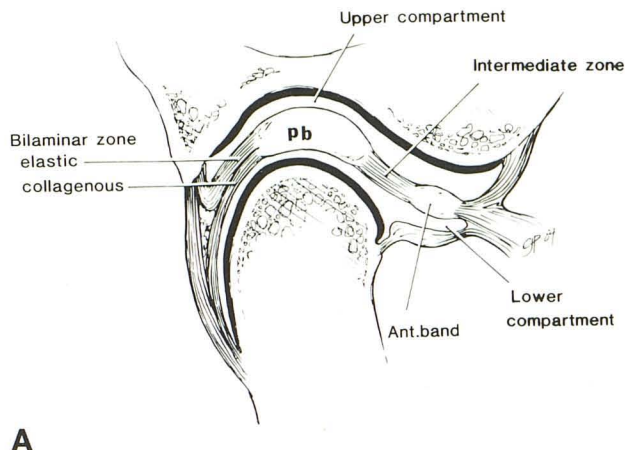
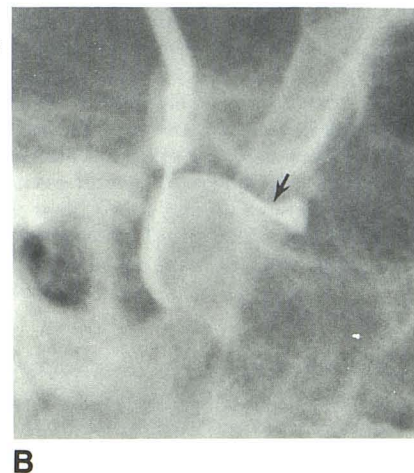
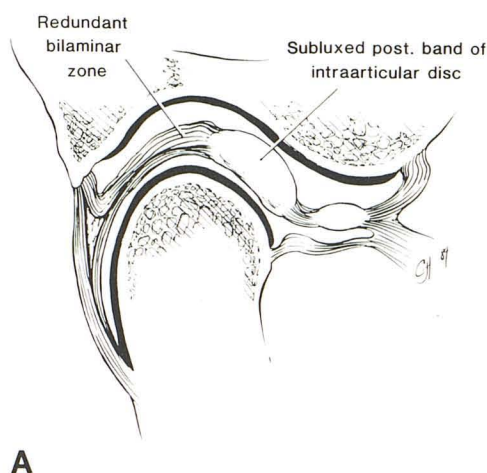


Fig. 4.—**A**, Schematic representation of anteriorly displaced posterior band due to laxity and redundancy of bilaminar zone. **B**, Arthrogram showing corresponding abnormal impression on lower-joint space caused by dislocated posterior band (arrow).

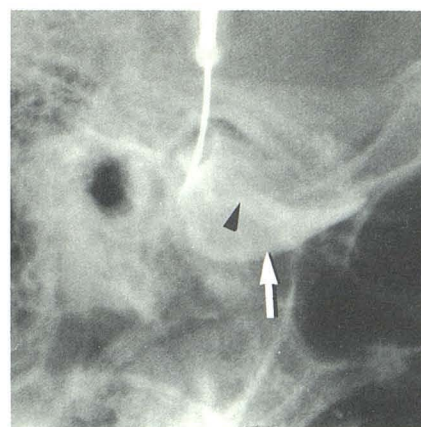


( $p < 0.01$ ). When the meniscus is perforated, contrast material filling the upper-joint space overlies the mandibular condyle. The well-defined inferior margin of the upper-joint space should not be mistaken for the "edge sign" of a sideways-dislocated meniscus. The upper-joint space extends farther than the edge of the lower-joint space in all directions (anteriorly, superiorly, and inferiorly) (Fig. 5).

The true incidence of sideways dislocation of the TMJ meniscus is higher than that detected radiologically. Since we became aware of this entity, a slight degree of sideways dislocation, not noticed radiologically, has become a frequent finding at surgery. Despite its common occurrence, to our knowledge, sideways dislocation of the TMJ meniscus has not previously been reported in the English radiologic literature. We suspect that the reason for this failure may be the almost routine use of and dependence on arthrotomography. A tomographic section at the level of a sideways-dislocated meniscus will give an appearance similar to that of an anteriorly dislocated meniscus.

In conclusion, sideways dislocation of the TMJ meniscus is a common finding both radiologically and surgically. This type of dislocation has a higher incidence of irreducibility and perforation of the meniscus. The radiologist should be aware

Fig. 5.—Sideways dislocation and perforation of temporomandibular joint meniscus. The "edge sign" of a sideways-dislocated meniscus (arrowhead) should not be confused with lower and longer edge of contrast-filled superior-joint space (arrow).



of the "edge sign" on TMJ arthrography, because it may be the only indication of an abnormally positioned meniscus.

#### ACKNOWLEDGMENT

We thank Kathy McClellan for preparing the manuscript.

## REFERENCES

1. Solberg WK, Woo MW, Houston JB. Prevalence of mandibular dysfunction in young adults. *J Am Dent Assoc* **1979**;98:25-34
2. Norgaard F. Temporomandibular joint arthrography (thesis). Copenhagen: Munksgaard, **1947**
3. Toller PA. Opaque arthrography of the temporomandibular joint. *Int J Oral Surg* **1974**;3:17-28
4. Wilkes CH. Arthrography of the temporomandibular joint in patients with the TMJ pain-dysfunction syndrome. *Minn Med* **1978**;61:645-652
5. Lynch TP, Chase DC. Arthrography in the evaluation of the temporomandibular joint. *Radiology* **1978**;126:667-672
6. Katzberg RW, Dolwick MF, Bales DJ, Helms CA. Arthrotomography of the temporomandibular joint: new technique and preliminary observations. *AJR* **1979**;132:949-955
7. Helms CA, Katzberg RW, Dolwick MF, eds. Internal derangements of the temporomandibular joint. San Francisco: Radiology Research and Education Foundation, **1983**