



Discover Generics

Cost-Effective CT & MRI Contrast Agents



FRESENIUS
KABI

WATCH VIDEO

AJNR

Percutaneous transluminal angioplasty of the carotid artery.

F Y Tsai, V Matovich, G Hieshima, D C Shah, C M Mehringer, G Tiu, R Higashida and H F Pribram

AJNR Am J Neuroradiol 1986, 7 (2) 349-358

<http://www.ajnr.org/content/7/2/349>

This information is current as
of June 4, 2025.

Percutaneous Transluminal Angioplasty of the Carotid Artery

Fong Y. Tsai¹
 Violet Matovich¹
 Grant Hieshima²
 Dipak C. Shah¹
 C. Mark Mehringer³
 Gregory Tiu¹
 Randall Higashida²
 Henry F. W. Pribram⁴

Percutaneous transluminal angioplasty (PTA) is being extensively applied to treat arteriosclerotic lesions. However, this application has not been widely accepted for the treatment of carotid artery stenosis. Successful attempts to relieve cerebral ischemia from extracranial carotid arterial stenosis by PTA are reported. Twenty-seven patients with arteriosclerotic stenosis, fibromuscular disease, and Takayasu carotid arterial stenosis were treated by PTA. All anatomic carotid stenotic lesions were corrected without any neurologic complication. Follow-ups ranged from 3 months to 4 years without recurrent symptoms in any patient. These results may suggest that some patients with cerebral ischemia secondary to extracranial carotid artery stenosis may be treated safely and effectively by PTA.

Percutaneous transluminal angioplasty (PTA), an angiographic but nonsurgical treatment for vascular occlusive disease, was first described by Dotter and Judkins [1] in 1964. It has become popular in the recent years after the introduction of the Grüntzig and Hopff [2] balloon dilatation catheter. Angioplastic dilatations have been reported in coronary, renal, mesenteric, celiac, aortoiliac, femoral, and more peripheral arteries. Recently, angioplasty has been applied to brachiocephalic arteries, but primarily to the subclavian, innominate, vertebral, or external carotid artery [3-7]. Transluminal dilatation of the carotid artery has been performed rarely because of the fear of cerebral emboli from ulcerative plaque. There have been only few scattered cases reported in the past years [3-12]. We report our successful experience with PTA at different levels of the carotid artery in 27 patients.

Subjects and Methods

Thirty-four patients were referred for carotid angioplasty. Twenty-seven patients undergoing 29 procedures are included in this report. Twenty-one patients had arteriosclerotic stenosis, five had fibromuscular dysplasia, and one had Takayasu arteritis. Among the 27 patients, 12 were male and 15 were female. They were 34-84 years old (average age, 72). (Males were younger than females by about 12-15 years.) The fibromuscular dysplasia and Takayasu patients tended to be younger than those having atherosclerosis (the youngest was 34 years old with Takayasu and 40 years old with fibromuscular dysplasia). Seven patients had proximal common carotid artery stenosis, three had distal common carotid artery stenosis, four had stenosis at the carotid bifurcation, six had internal carotid artery stenosis, two had external carotid artery stenosis, five had fibromuscular disease of the internal carotid artery, and two had bilateral carotid artery disease.

All patients were monitored, with electroencephalography (EEG) during the procedure, except those undergoing external carotid artery PTA. The patients were medicated with intravenous Valium 5-10 mg and Decadron 10 mg. Heparin 5000 units was given right after the PTA catheter was introduced into the carotid artery. Injection of heparinized arterial blood into the carotid artery through a balloon catheter without the placement of a guide wire was performed during inflation of the balloon. Persantine 50 mg was administered orally three times a day for about 3 months after dilatation. Prednisone was also given to patients (the

Received August 29, 1984; accepted after revision September 20, 1985.

Presented at the annual meeting of the American Society of Neuroradiology, Boston, June 1984.

¹ Department of Radiology, University of Missouri-Kansas City School of Medicine, Truman Medical Center, 2301 Holmes, Kansas City, MO 64108. Address reprint requests to F. Y. Tsai.

² Department of Radiology, UCLA Medical Center, Los Angeles, CA 90024.

³ Department of Radiology, Harbor/UCLA Medical Center, Torrance, CA 90509.

⁴ Department of Radiology, University of California, Irvine, CA 92664.

AJNR 7:349-358, March/April 1986

0195-6108/86/0702-0349

© American Society of Neuroradiology

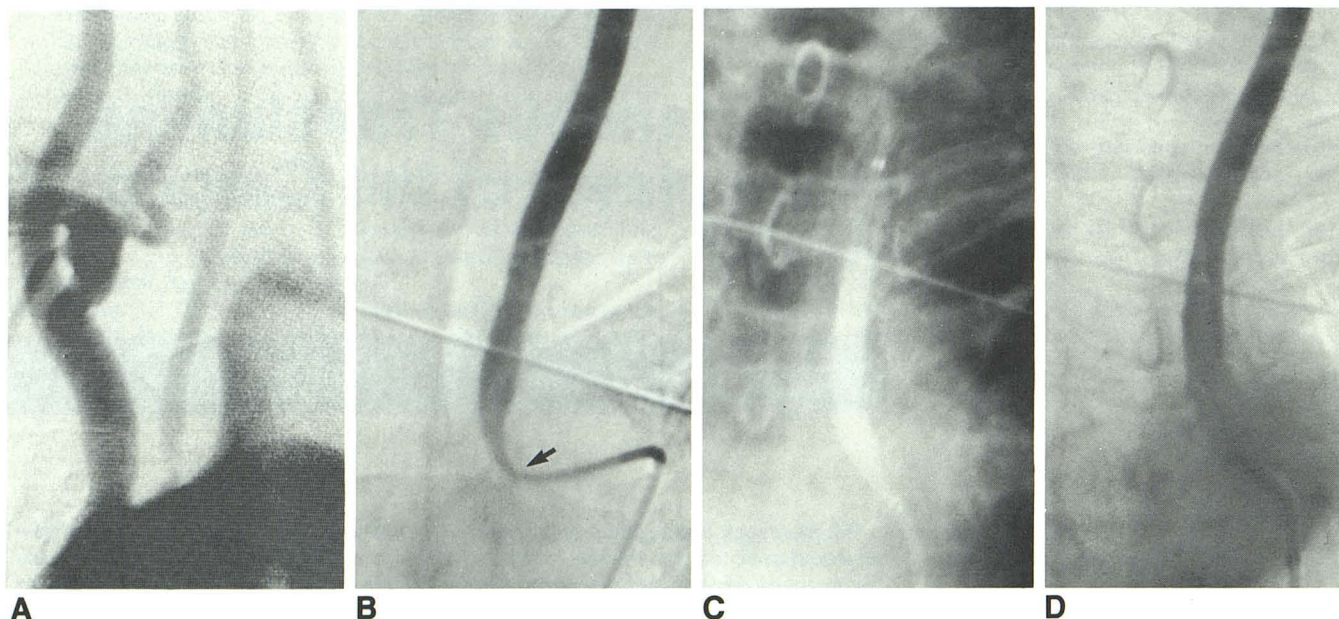


Fig. 1.—Case 1. Proximal common carotid artery angioplasty. DSA of aortic arch (A) and selective left common carotid angiogram (B) show severe stenosis of left proximal common carotid artery (arrow). C, Inflated balloon in proximal

left common carotid artery. D, Left carotid angiogram after PTA clearly shows full dilatation of proximal left common carotid artery.

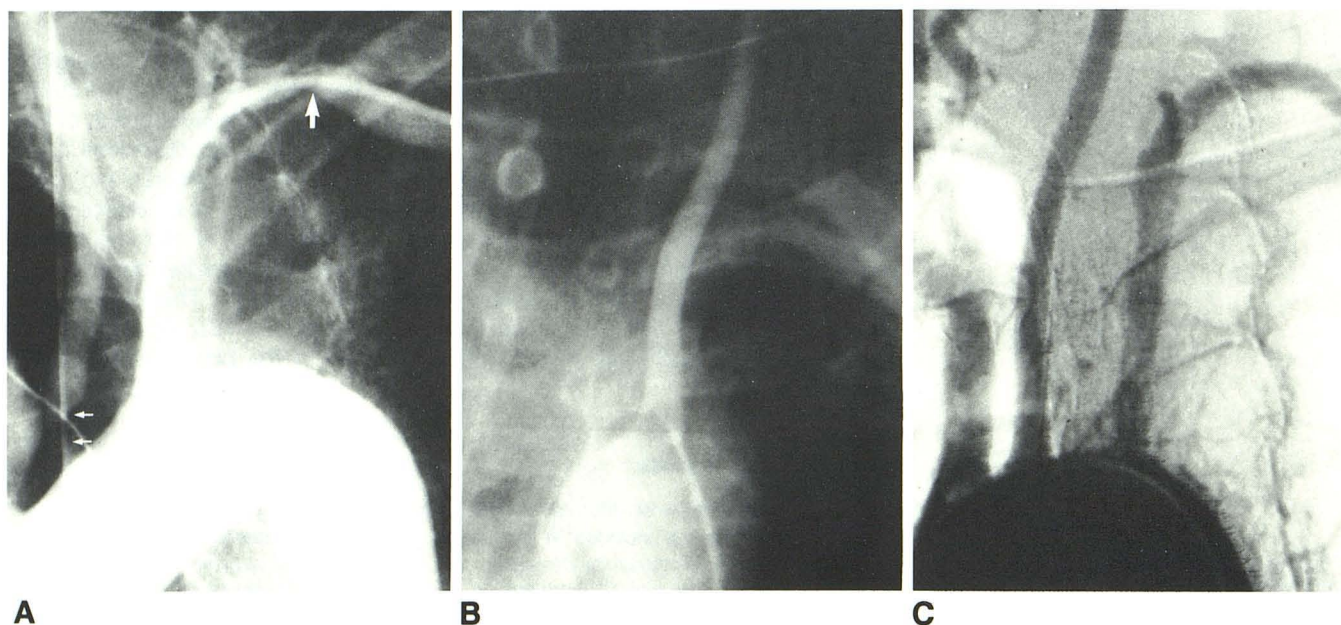


Fig. 2.—Case 2. Proximal common carotid artery angioplasty. A, Arch angiogram with left axillary catheter. High-degree stenosis in left subclavian artery (large arrow) and severe stenosis at origin of left common carotid artery

(small arrows). Left vertebral artery was occluded. B, Postangioplasty angiogram. Full dilatation of origin of left common carotid artery. C, Repeat arch angiogram. Full dilatation of left subclavian and left common carotid arteries.

last 19 patients) for 1 week (tapering from 30 mg to 5 mg over a 6 day period). The balloon catheter was made by Medi-Tech; it was ordered specially with a 5 mm short tip. The size of the balloon was tailored to the length of stenosis and caliber of the carotid artery (balloon diameter ranged from 4 to 10 mm).

Results

In seven of the 34 patients referred for PTA, it could not be performed: Two of the seven were terminated because loose plaque and ulcerative plaque were demonstrated by conven-

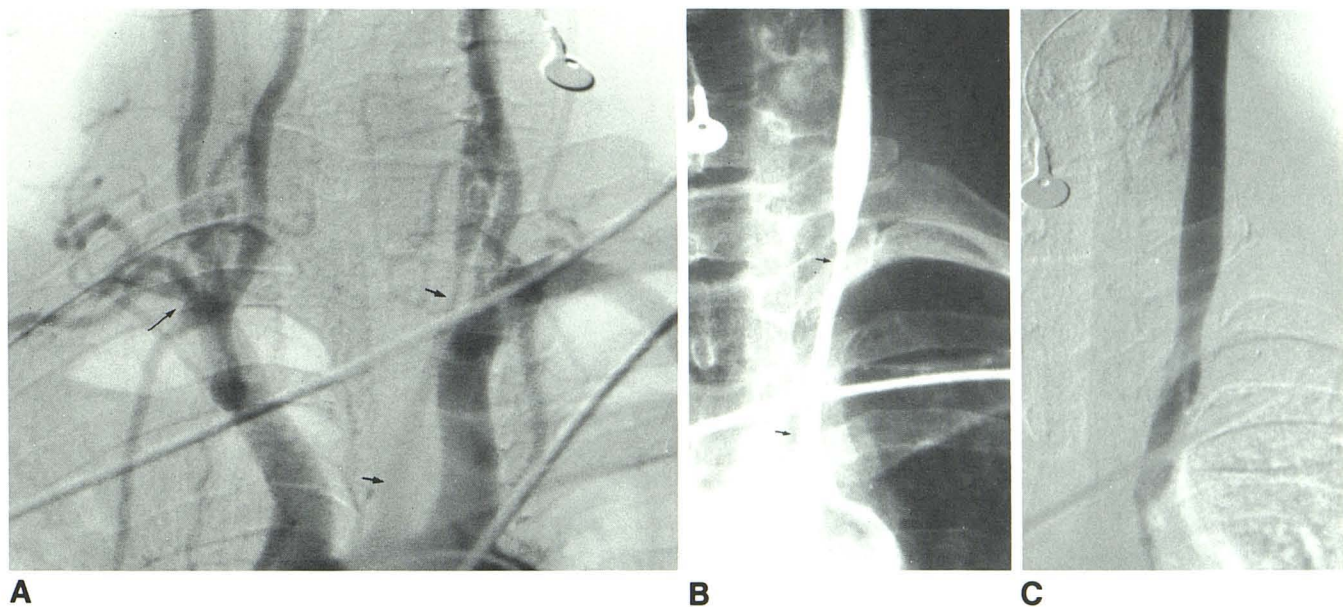


Fig. 3.—Case 3. Proximal common carotid artery angioplasty. Arch (A) and selected carotid (B) angiograms show total occlusion of right subclavian artery just distal to origin of right vertebral artery (*long arrow*). Long-segment stenosis

of left proximal common carotid artery (*short arrows*). C, Postangioplasty angiogram. Full dilatation of proximal left common carotid artery.

tional angiography (not seen on digital subtraction angiography [DSA]); two patients had a very tortuous proximal internal carotid artery (one with fibromuscular dysplasia and one with stenosis); and in three patients the procedure was discontinued because of EEG changes with spiking and slow waves occurring while passing a balloon catheter through the stenotic segment. We did not have any complications during or after the angioplastic procedure except for a large groin hematoma. All 27 patients have been well during follow-up periods of 3 months to 4 years.

Representative Case Reports

Case 1 (fig. 1)

A 72-year-old woman was admitted for evaluation of intermittent right and left hemiparesis, slurred speech, and blurred vision of the left eye. DSA disclosed stenosis of the right common carotid bifurcation and severe stenosis of the left proximal common carotid artery. Conventional carotid angiography confirmed the DSA findings and a smooth luminal stenosis of left proximal common carotid measuring about 2.5 mm. PTA was performed with a 10 mm by 4 cm balloon catheter. The caliber was dilated up to 10 mm, and after angioplasty, she was able to speak better and had no blurring of vision. She then had a right carotid endarterectomy. Since then, she was well after more than 18 months later.

Case 2 (fig. 2)

A 57-year-old man presented with increasing difficulty in speech, right-sided weakness for several weeks, and left arm pain. Angiography demonstrated severe stenosis of the proximal left common carotid artery and total occlusion of the left vertebral artery with

moderate stenosis of the left subclavian artery distal to it. PTA of the left subclavian artery was performed through the left transaxillary approach and the left proximal common carotid artery was dilated from 2 mm to 8 mm with a 8 mm \times 3 cm balloon catheter via the femoral route. He was still symptom-free 25 months later.

Case 3 (fig. 3)

A 34-year-old woman with previous diagnoses of Takayasu disease was transferred to our hospital after a few months of increasingly blurred vision in the left eye, slurred speech, and difficulty in finding words. She also had right arm pain with very faint brachial and radial pulses, a palpable right axillary pulse, and pain in her left arm after exercise. DSA showed a total occlusion of right subclavian artery and a long-segment stenosis of the left proximal common carotid artery. Conventional angiography demonstrated the same findings, yet no definite abnormality was found in the left subclavian artery. The stenotic segment measured about 6 cm in length, tapering from 3.5 mm to 0.5 mm from its proximal origin. PTA was performed with an 8 mm \times 4 cm balloon catheter from the distal to the proximal portion of the segment. She was still free of visual complaints and had no speaking problems 5 months later.

Case 4 (fig. 4)

A 66-year-old woman presented with staggering gait and increasing dysarthria, dysphasia, and a right hemiparesis over 2 days. Her left arm blood pressure measured about 65 mm Hg less than her right arm. Diffuse posterior fossa atrophy as well as left frontal lobe and basal ganglia infarcts were noted on CT. Angiography disclosed nonfilling of both vertebral arteries and severe stenosis of the left subclavian artery. The left internal carotid artery was totally occluded and there was moderate stenosis of the distal common carotid artery. PTA of the left subclavian artery was performed with an 8 mm by 3

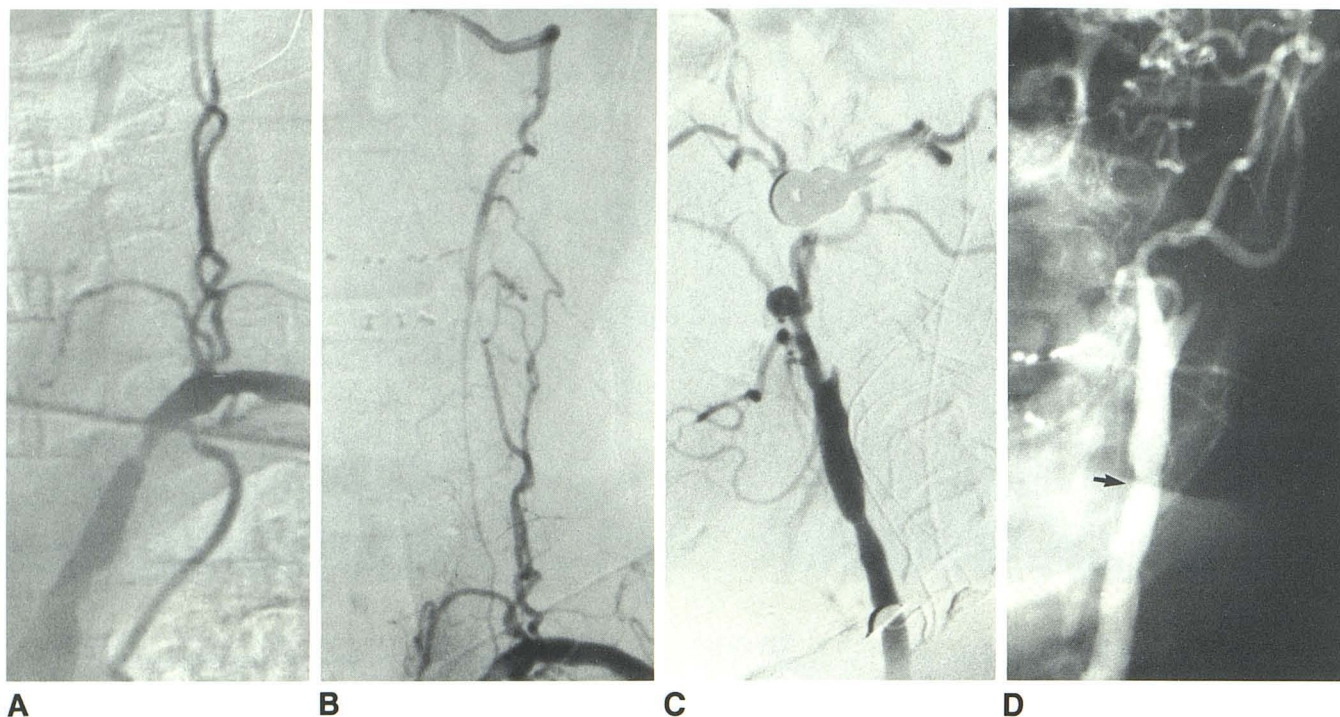


Fig. 4.—Case 4. Subclavian and distal common carotid artery angioplasty. A, Left subclavian angiogram. Nonfilling of left vertebral artery with severe stenosis of left subclavian artery. B, Postangioplasty angiogram. Full dilatation of stenotic subclavian artery. Reopacification of left vertebral artery antegrade and collaterals through cervical trunk. C, Stenosis of distal common carotid

artery with total occlusion of left internal carotid artery. Basilar artery was supplied via collaterals through occipital artery. (Basilar artery is not seen well.) D, Postangioplasty angiogram. Full dilatation of distal common carotid artery (arrow).

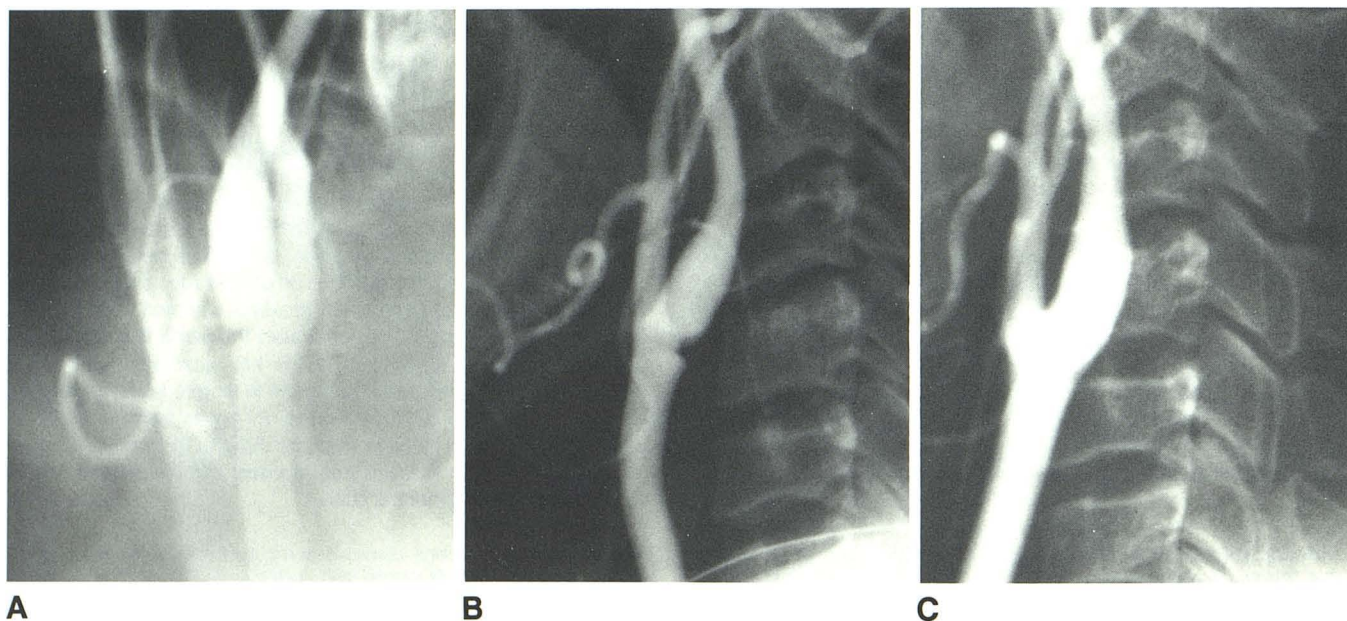


Fig. 5.—Case 5. Weblike stenosis of common carotid bifurcation. Frontal (A) and lateral (B) views of right common carotid arteriogram. Partial weblike

stenosis at right common carotid bifurcation. C, Web stenosis was dilated by angioplasty.

cm balloon catheter. Despite significant improvement in her gait, she was readmitted 5 months later with a dense hemiparesis and aphasia. Repeat angiography showed no evidence of restenosis of the previously dilated left subclavian artery. A small left vertebral artery was

demonstrated; it had not opacified before angioplasty. The left distal common carotid artery was dilated with an 8 mm × 3 cm balloon catheter in an effort to improve collateral supply via the external carotid artery. Better opacification of the basilar and internal carotid

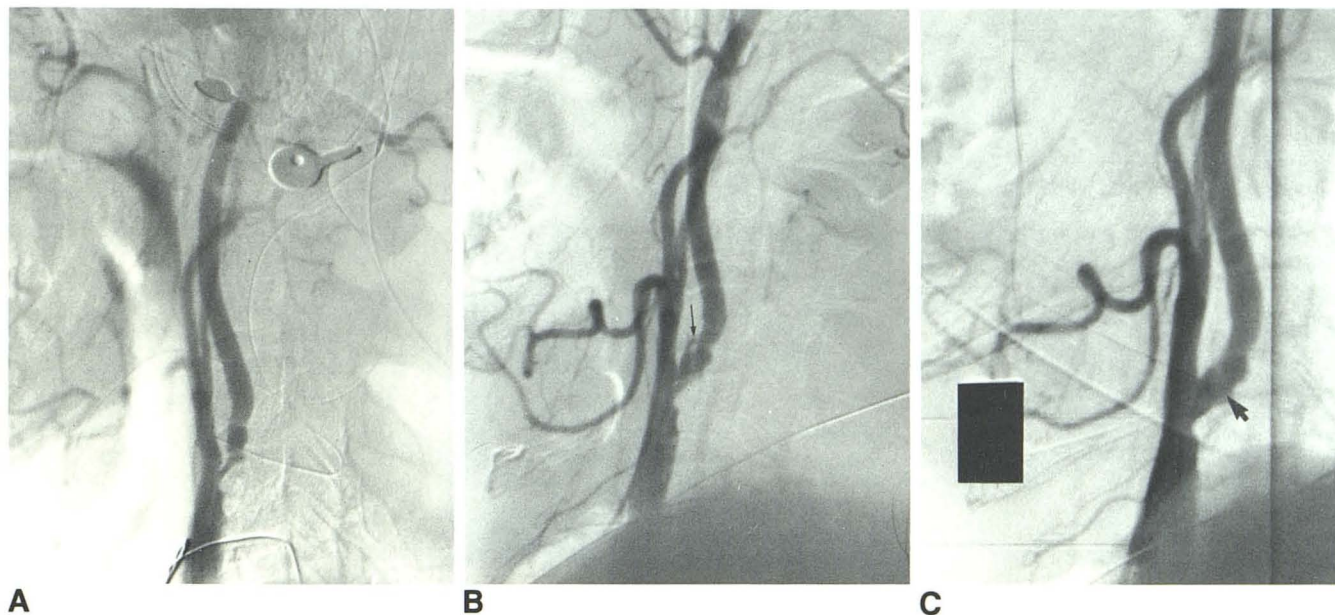


Fig. 6.—Case 6. Carotid bifurcation and proximal internal carotid artery stenosis. A, Severe stenosis was seen at both proximal internal carotid arteries. Ulcerative plaque at left carotid bifurcation. Right internal carotid artery is much

narrower than left. B, Immediate postangioplasty arteriogram shows wider caliber of right internal carotid artery; intimal split (arrow). C, Arteriogram 6 months later. Healing of right internal carotid artery. No intimal split (arrow).

arteries through the occipital and internal maxillary arteries was obtained. Six months after the second angioplasty, she was found to have no significant ataxia and better strength in the right leg. She still had a marked dysphasia but was able to speak a few words. Her right arm weakness was unchanged.

Case 5 (fig. 5)

A 64-year-old man was admitted because of a syncopal episode and transient loss of consciousness. He also had slight weakness in his left extremities. He has been treated for hypertension over the previous 4 years. A loud bruit was heard in the right side of his neck. Angiography disclosed a weblike stenosis at the right common carotid bifurcation. The vertebral arteries were normal. Angioplasty of the distal common carotid artery was performed with a 10-mm-diameter and 2-cm-long balloon catheter. The patient had been followed for over 17 months without recurrent symptoms.

Case 6 (fig. 6)

A 54-year-old man was admitted for evaluation of increased drowsiness and weakness in both extremities. Occasionally he felt numbness in his left arm. He has been a heavy smoker and alcoholic for more than 30 years. He also had transient slurred speech. Angiography demonstrated a high-degree stenosis of both carotid bifurcations, stenosis of the left subclavian artery, and narrowing at the origin of both vertebral arteries. Ulcerative plaques were seen at the left carotid bifurcation. He had right internal carotid artery angioplasty before left carotid endarterectomy. The stenotic segment of the right internal carotid artery was only 1.5 mm, just enough to pass the 5-mm-diameter balloon catheter. Subsequently, he had several episodes of right hemiparesis and a speech problem after left carotid endarterectomy, but he recovered with mild weakness. At 1 and 6 months after surgery, follow-up angiography showed total occlusion

of left carotid artery. The right internal carotid artery had further healing of the intimal split, and the lumen appeared smoother and remained open. After surgery, he also had left proximal subclavian artery angioplasty with a 10-mm-diameter and 3-cm-long balloon to improve his left arm ischemia and gait problem. After that, he was well after more than 18 months later.

Case 7 (fig. 7)

A 67-year-old woman was admitted for evaluation of left-sided weakness and increasing confusion for several weeks. She also complained of pain and tingling in her left arm. Before admission, she was found on the floor at home with an injury to her left hip and leg. Multiple small lacunar infarcts were seen on CT. Angiography disclosed a long, 3.0 cm segment of severe stenosis in the proximal right internal carotid artery. Angioplasty of the right internal carotid artery was performed with a 6 mm × 5 cm balloon catheter before her pelvic surgery. She was well with very mild residual hemiparesis after more than 11 months later.

Case 8 (fig. 8)

A 63-year-old man presented with recent myocardial infarct with multiple coronary arterial stenoses. He also had intermittent left-sided weakness and a right carotid bruit. A high-degree stenosis of the right proximal internal carotid artery was disclosed by angiography. Anticoagulant with heparin, Persantine, and aspirin were initiated after angiography. Dilatation of the right internal carotid artery was recommended before cardiac bypass surgery. Angioplasty was performed with a 6 mm × 3 cm catheter, but the lumen was dilated to 5 mm only. Despite that, the intermittent right-sided weakness resolved. He then underwent cardiac triple bypass surgery. He was still well after about 4 months later.

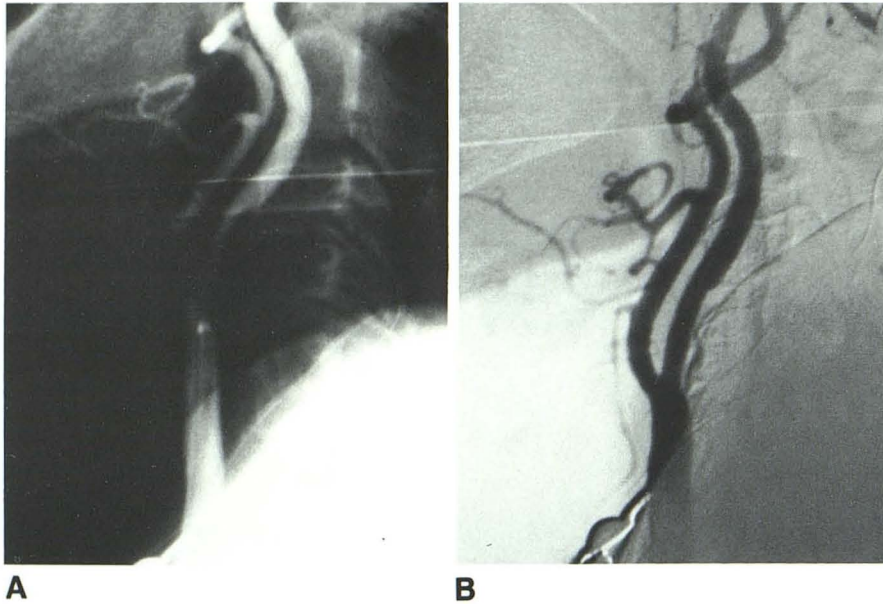


Fig. 7.—Case 7. Proximal internal carotid artery. A, Right common carotid angiogram. Long segment, about 3.0 cm; severe stenosis of right internal carotid artery. (Note.—Balloon catheter was in the distal common carotid artery.) B, Postangioplasty angiogram. Good dilatation of right internal artery.

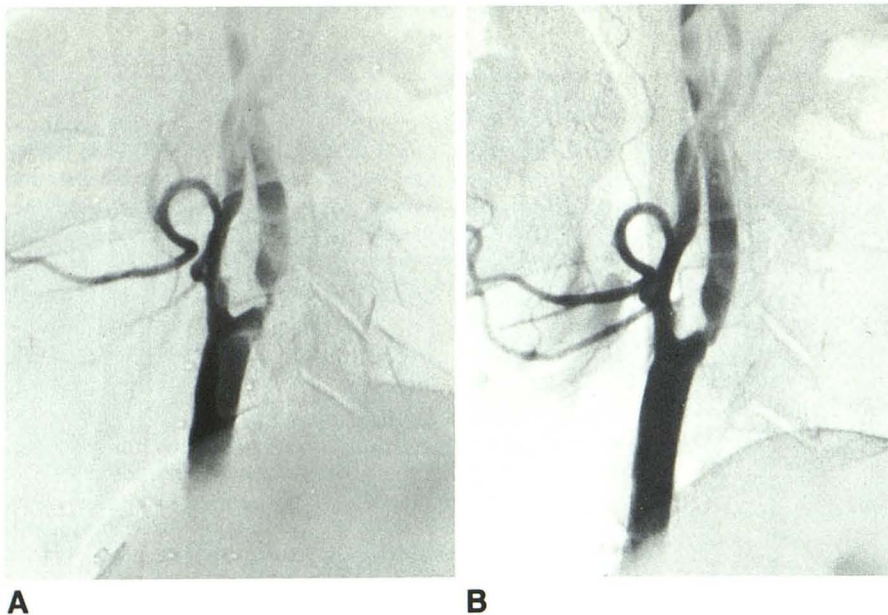


Fig. 8.—Case 8. Internal carotid artery. A, Preangioplasty angiogram. Marked stenosis of proximal right internal carotid artery. B, Postangioplasty angiogram. Partial dilatation of right internal carotid artery.

Case 9 (fig. 9)

A 73-year-old woman began to have left ophthalmoplegia with decreasing visual acuity of the left eye after having several left frontal headaches. She also had diplopia and dropping of the left eyelid. Angiography demonstrated a 2-cm-long stenotic segment of the left internal carotid artery just distal to the petrous and proximal to the cavernous segment. In addition, a large aneurysm was seen in the cavernous internal carotid artery. Angioplastic dilatation of the distal internal carotid artery was performed at the time of balloon embolization. The aneurysm was then embolized with a detachable balloon. About 2 months later, repeat angiography showed the dilated segment still patent.

Case 10 (fig. 10)

A 60-year-old woman was admitted to evaluate the cause of intermittent attacks of aphasia and mild weakness in both sides. She had had a right cerebral stroke 1 year before with mild residual left-sided weakness. Angiography disclosed a total occlusion of the right internal carotid artery and about a 40% stenosis of the left proximal internal carotid artery. DSA, however, showed a very small, slitlike residual lumen and stopped at about 3 cm above the origin of the right internal carotid artery. The origin of the right external carotid artery was also slightly narrowed. PTA of the right external carotid artery and possibly the internal carotid artery was recommended before external-internal carotid bypass and left carotid artery endar-

Fig. 9.—Case 9. Distal internal carotid artery. **A**, Preangioplasty angiogram. Segmental stenosis at distal left internal carotid artery (*arrows*) between petrous and cavernous segments. Huge aneurysm is at cavernous part of internal carotid artery. **B**, Angiogram after angioplasty and balloon embolization. Detached balloon in aneurysm and dilatation of narrowed segment of internal carotid artery.

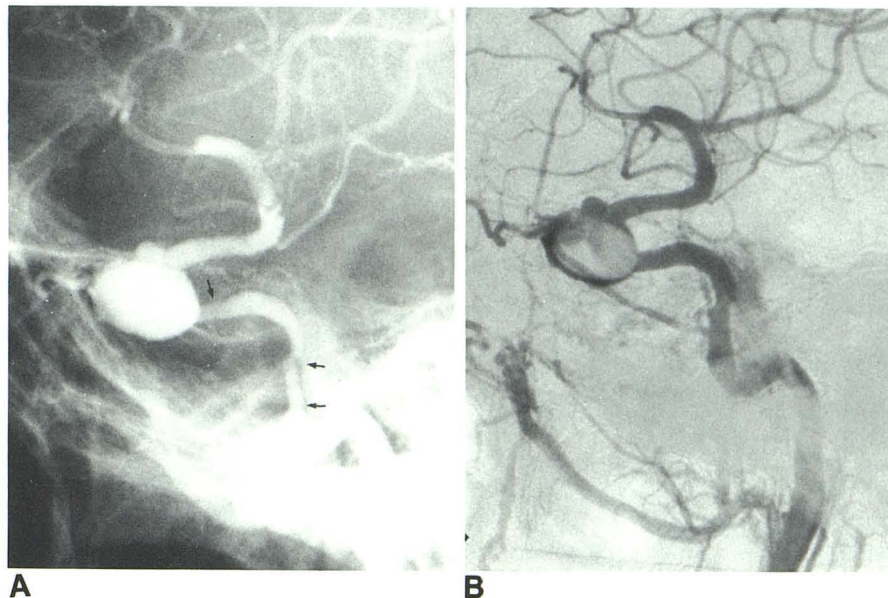
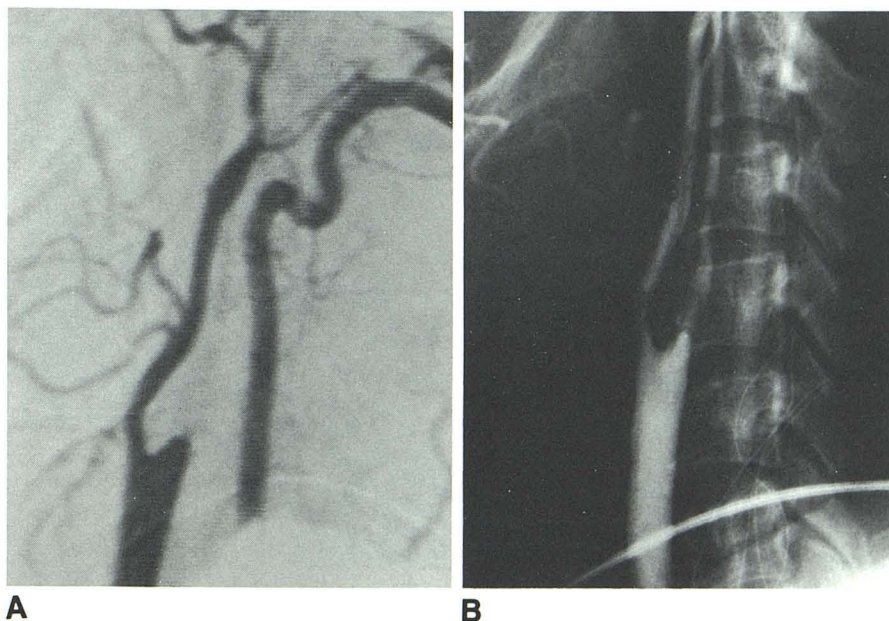


Fig. 10.—Case 10. Internal carotid artery. **A**, DSA. Total occlusion of proximal right internal carotid artery. Retrograde filling of slitlike right internal carotid artery. **B**, Postangioplasty angiogram. Filling of both external and internal carotid arteries (also reflux into vertebral artery). Right internal carotid artery was quite small until it reached cavernous segment.



terectomy. PTA of the right external carotid artery was performed with 6 mm \times 3 cm balloon catheter. After that, the right internal carotid artery was reopened with guide wire and the same balloon catheter. Right after reopening the occluded segment of internal carotid artery, blood was suctioned out with a large syringe, and irrigation with heparinized saline was performed. Six weeks later the right internal carotid artery remained open, and she was still well 3 months later.

Case 11 (fig. 11)

A 56-year-old woman was admitted for evaluation of increasing left-sided weakness over a period of 2 months before admission. She also had pain and tingling in her face. She had had a left cerebral

stroke 4 years before. Angiography demonstrated fibromuscular dysplasia in both internal carotid arteries. Balloon angioplasty dilatations were performed to treat the bilateral internal carotid artery stenosis caused by fibromuscular dysplasia. She was still symptom-free after more than 16 months later.

Case 12 (fig. 12)

An 84-year-old man had sudden onset of left-sided weakness 4 days before admission. He also had severe right-sided headaches and vertigo with dizziness and mild ataxia. He had a suprapubic catheter because of a chronic urethral stricture. A huge vesical stone was found. Angiography disclosed a total occlusion of the right internal carotid artery with severe stenosis of the proximal right

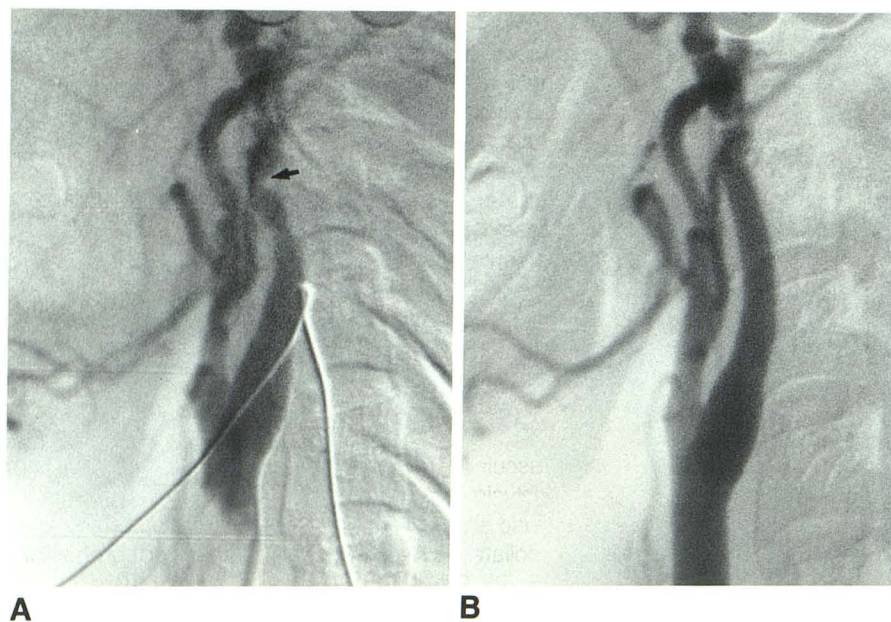


Fig. 11.—Case 11. Fibromuscular dysplasia and internal carotid artery. **A**, Severe narrowing of mid-internal carotid artery from fibromuscular dysplasia (*arrow*). **B**, Stenotic segment is fully dilated. There is still some residual stringlike appearance of internal carotid artery.

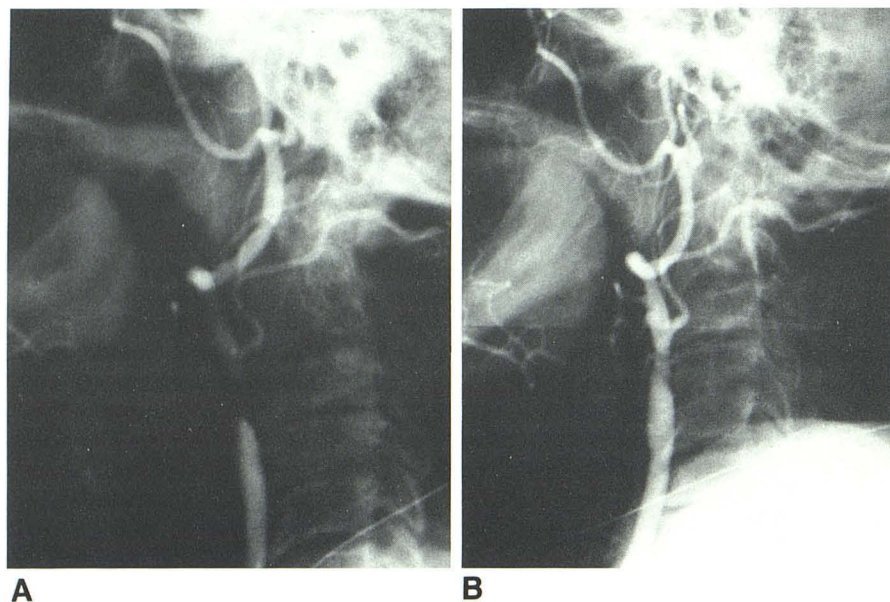


Fig. 12.—Case 12. External carotid artery. **A**, Marked stenosis at proximal external carotid artery with total occlusion of internal carotid artery. **B**, Postangioplasty angiogram. Full dilatation of proximal external carotid artery.

external carotid artery. PTA of the right external carotid artery was performed to improve the cerebral circulation before cystoscopy with cystourethrotomy. The right external carotid artery was dilated from 2.5 mm to 6 mm by a 6 mm \times 3 cm balloon catheter.

Discussion

PTA of the brachiocephalic arteries has been performed more frequently in the last 5 years. However, it has been limited to the subclavian, innominate, vertebral, and external carotid arteries [3–9, 13–16]. Balloon angioplasty of the carotid artery was first reported in 1980 by Kerber et al. [7], who dilated the proximal common carotid artery during distal carotid endarterectomy. After that, a few isolated cases hav-

ing retrograde intraoperative balloon angioplasty of the common carotid artery through an arteriotomy were reported [10, 11]. In 1983, Wiggli and Gratzl [12] described successful dilatation in a case with stenosis of the distal common carotid artery. Tievsky et al. [17] described PTA of postsurgical stenosis in the distal common carotid artery in one case.

Surgical endarterectomy of the proximal common carotid artery carries a high risk and is a rather difficult procedure. Cervical carotid artery bypass is preferred to endarterectomy. Surgical complications may be as high as 23% and include chylothorax, lymph fistula, wound infection, as well as phrenic nerve palsy from extrathoracic surgery [18, 19]. Common carotid artery stenosis is quite different from that of the carotid bifurcation but similar to that at the origin of the brachioce-

phalic arteries. It is usually a smooth luminal stenosis without ulceration [20, 21]. PTA may be performed to correct common carotid stenosis in a similar manner to those cases with stenosis at the origin of the branchiocephalic arteries (figs. 1–4). Surgical treatment of Takayasu arteritis has limited success because of the nature of the disease and the high incidence of graft occlusion [12]. PTA may be a better alternative, as was seen in case 3. In case 4, since the internal carotid artery was totally occluded, angioplasty of the common carotid artery improved collaterals to the internal carotid and basilar arteries and carried the same risk as angioplasty of the external carotid artery.

Arteriosclerotic stenosis at the carotid bifurcation is treated by endarterectomy with excellent results. The operative risk has been reported as 1%–8% mortality and 1%–4% morbidity in the hands of an experienced surgeon [20–36]. PTA of the carotid bifurcation for atherosclerosis may be somewhat controversial at the present time because of the fear of dislodging an ulcerative plaque. It should be restricted to high-surgical-risk patients or those patients with nonatherosclerotic stenosis such as a web or arteritis, as was seen in case 5.

PTA of the internal carotid artery was first reported in 1980 by Mullan et al. [30] in a case of weblike stenosis. Surgical correction of weblike stenosis was considered dangerous because of the distinct possibility of total occlusion of the carotid artery.

Carotid artery stenosis may coexist with coronary artery disease. Mortality in patients with symptomatic coronary artery disease undergoing carotid endarterectomy can be as high as 14%, and cerebral injury may occur during cardiac surgery in patients with carotid artery disease. The incidence of stroke may be as high as 17%. Simultaneous carotid endarterectomy and cardiac surgery has been recommended to reduce complications [22, 23, 26, 29]. From our experience and review of the literature, PTA of a smooth stenotic internal carotid artery may be performed with reasonable safety before cardiac bypass operations or other surgical interventions, as was seen in cases 7 and 8 [31]. In case 6, PTA of the right internal carotid artery preserved the cerebral circulation despite occlusion of the left carotid artery after endarterectomy.

Medial fibroplasia or fibromuscular dysplasia usually occurs in the upper cervical artery and is often not amenable to endarterectomy. In 1981, Hasso et al. [4] first reported the successful dilatation of fibromuscular dysplasia of the internal carotid artery. Since that time, several reports have confirmed the success of PTA in this disease involving the internal carotid artery [20, 21, 30–33]. The "string of beads" appearance of fibromuscular dysplasia may generate turbulence, and mural thrombus may form between the stenotic rings. We recommend treatment with anticoagulants for a period of time before PTA if there are symptoms of transient ischemic attacks to avoid the possibility of dislodging loose thrombus. PTA should not be performed in a very tortuous dysplastic artery because of the difficulty in passing the guide wire and the risk of arterial dissection [32–34].

PTA of the internal carotid artery may also be performed to aid operation in cases where the stenosis is too high and difficult to reach. In case 9, the vertical part of the internal carotid just proximal to the cavernous part was narrowed. It

was difficult to pass a detachable balloon through the stenotic segment to occlude the large cavernous aneurysm of the internal carotid artery. PTA allowed us to pass the balloon and successfully occlude the aneurysm.

Surgical intervention has been the traditional method for treating the totally occluded artery. Angioplastic treatment to reopen the total occluded carotid artery has not been reported before. In case 10, the right internal carotid artery was reopened after successful dilatation of the proximal external carotid artery. PTA of totally occluded carotid artery must be reserved for a straight segment, and extreme caution must be used to avoid perforation of the artery. Reverse blood flow may steal carotid circulation from intracranial branches, yet it plays a good protective role to prevent antegrade dislodging emboli.

Cerebrovascular occlusive symptoms often result from stenosis or occlusion of the internal carotid artery, but the external carotid artery may play an extremely important role in providing collaterals to the internal carotid or vertebrobasilar circulation [6, 26, 27]. External carotid arterial stenosis may aggravate the ischemic symptoms in those patients with occlusion of the internal carotid or vertebral arteries. In case 4, PTA of the distal common carotid artery improved the collaterals of the external carotid artery circulation to the internal carotid and basilar arteries. Stenosis of the external carotid artery had increased the ischemic symptoms because of decreasing collaterals. PTA of the external carotid artery improves blood flow through collaterals to the internal carotid artery circulation, as was seen in case 11.

Although short-segment stenosis is the ideal situation for PTA (cases 1 and 2), we have not found any significant difference or difficulty in dilating a longer segment as in cases 3 and 7. Long-segment stenosis may be dilated with a longer balloon or in two stages with shorter balloons. The external carotid artery or the upper internal carotid artery has a greater tendency to develop spasm because of the nature of these arteries. Caution must be taken to avoid spasm during PTA. Spasm distal to the dilated area may be caused by damage to the wall of the artery with the long, stiff tip of the balloon catheter in a tortuous carotid artery. We believe that short-tip balloon catheters may avoid this complication. It is also recommended to avoid overdilatation of the artery. Vasodilators may be given by arterial injection to relieve spasm, but anticoagulant or streptokinase infusion is needed as well to prevent thrombus formation. Vasodilators may be ineffective. We had a patient who developed severe spasm of the iliac artery after angioplasty. The spasm was not relieved despite the use of several vasodilators. General anesthesia eventually relieved the spasm. We believe that general anesthesia may help as a last resort.

Although PTA has not been considered a definitive procedure, we have followed eight patients with DSA. None had evidence of restenosis from 4 months to almost 4 years after PTA. All patients were followed with clinical examinations and were well for 3 months to 4 years. This may be attributed, in part, to the effect of glucocorticoids, which are given to all patients.

PTA of the carotid artery may be a somewhat controversial procedure without experience of a larger series and longer

follow-up to compare with surgical results. However, we have been asked to perform angioplasty in patients who may face higher risks with surgical endarterectomy, particularly those with multiple areas of occlusion and cardiac or pulmonary problems (cases 7 and 8). Until now, no patient has suffered neurologic complications.

We believe that PTA may be considered an alternative procedure for improving carotid artery blood flow independently or as an adjunct to surgical management. Transluminal angioplasty may be performed in arteriosclerotic stenosis, fibromuscular dysplasia, and Takayasu arteritis at different levels of the carotid artery. It is essential to work closely with neurologists, neurosurgeons, and vascular surgeons to select the appropriate cases to avoid complications. Injections of heparinized arterial blood during dilatation is believed to reduce the risk of cerebral ischemia. EEG monitoring is critical in performing angioplastic dilatation of the carotid artery. We abandoned the procedure in three potentially high-risk patients because of EEG changes while we passed the balloon catheter through the stenotic segment.

Although we need further experience to evaluate the safety of carotid artery angioplasty, we believe it may be applied with reasonable safety in carefully selected cases. Shorter-tip balloon catheters must be used to avoid injury to the lumen of the carotid artery.

REFERENCES

- Dotter CT, Judkins MP. Transluminal treatment of arteriosclerotic obstruction: description of a new technique and preliminary report of its application. *Circulation* 1964;30:654-670
- Gruntzig A, Hopff H. Perkutane rekanalisation chronischer arterieller verschlüsse mit einem neuen dilatations-catheter. *Dtsch Med Wochenschr* 1974;99:2502-2505
- Motarjeme A, Keifer JW, Zuska AJ. Percutaneous transluminal angioplasty of the vertebral arteries. *Radiology* 1981;139:715-717
- Hasso AN, Bird CR, Zinke DE, Thompson JR. Fibromuscular dysplasia of the internal carotid artery. Percutaneous transluminal angioplasty. *AJNR* 1981;2:175-180
- Motarjeme A, Keifer JW, Zuska AJ. Percutaneous transluminal angioplasty of the brachiocephalic arteries. *AJNR* 1982;3:169-174
- Vitek JJ. Percutaneous transluminal angioplasty of the external carotid artery. *AJNR* 1983;4:796-799
- Kerber CS, Cromwell LD, Lehden OL. Catheter dilatation of proximal carotid stenosis during distal bifurcation endarterectomy. *AJNR* 1980;1:348-349
- Fogarty TJ, Kinney TB. A new approach to transluminal angioplasty. *Appl Radiol* 1984;13:25-37
- Stridbeck H, Jonsson N, Lindstedt E, Ekelund L. Experimental fibrous renal artery stenosis dilated by balloon catheter. *Acta Radiol [Diagn]* 1983;23:177-183
- Pritz MB, Smolin MF. Treatment of tandem lesions of the extracranial carotid artery. *Neurosurgery* 1984;15:233-236
- Hodgins GW, Dutton JW. Subclavian and carotid angioplasties for Takayasu's arteritis. *J Can Assoc Radiol* 1982;33:305-307
- Wiggli U, Gratzl O. Transluminal angioplasty of stenotic carotid arteries: case report and protocol. *AJNR* 1983;4:793-795
- Castaneda-Zuniga WR, Formanek A, Tadavarthy M, et al. The mechanism of balloon angioplasty. *Radiology* 1980;135:565-571
- Block PC, Myler RK, Stertz S, Falloon JT. Morphology after transluminal angioplasty in human beings. *N Engl J Med* 1981;305:382-385
- Clouse ME, Tomashefski JF Jr, Reinhold RE, Costello P. Mechanical effect of balloon angioplasty: case report with history. *AJR* 1981;137:869-871
- Castaneda-Zuniga WR, Sibley R, Amplatz K. The pathologic basis of angioplasty. *Angiology* 1984;35:195-205
- Tievsky AL, Dray EM, Mardiat JG. Transluminal angioplasty in postsurgical stenosis of the extracranial carotid artery. *AJNR* 1980;1:348-349
- DeBakey ME, Crawford ES, Cooley DA, Morris GC Jr, Garrett E, Fields WS. Cerebral arterial insufficiency. One to 11 years result following arterial reconstructive operation. *Am J Surg* 1965;161:921-945
- Diethrich EB, Garrett HE, Ameriso J, Crawford ES, El-Bayer M, DeBakey ME. Occlusive disease of the common carotid and subclavian arteries treated by carotid subclavian bypass. *Am J Surg* 1967;114:800-808
- Imparato AM, Riles TS, Ecorstein F. The carotid bifurcation plaque: pathologic finding associated with cerebral ischemia. *Stroke* 1979;10:238-245
- Fleming JRF, Deck JHN, Gottlieb AI. In: Smith RR, ed. *Pathology of atherosclerotic plaques in stroke and extracranial vessels*. New York: Raven 1984:23-37
- Emery RW, Cohn LH, Whittemore AD, Manmick JA, Couch NP, Collins JJ Jr. Coexistent carotid and coronary artery disease surgical management. *Arch Surg* 1983;118:2035-2038
- West H, Burton R, Roon AJ, Malone JM, Goldstone J, Moore WS. Comparative risk of operation and expectant management for carotid artery disease. *Stroke* 1979;10:117-121
- Stoney RJ, String ST. Recurrent carotid stenosis. *Surgery* 1976;80:705-710
- Hertzer NR, Martinez BD, Beven EG. Recurrent stenosis after carotid endarterectomy surgery. *Gynecol Obstet* 1979;149:360-364
- Blaisdell WF, Clauss RH, Galbraith JG, Imparato AM, Wylie EJ. Joint study of extracranial arterial occlusion cooperative study. *JAMA* 1969;209:1889-1895
- Brown OW, Kerstein MD. The surgical management of transient ischemic attacks. *Angiology* 1984;35:12-21
- Riles TS, Imparato AM, Mintzer R, Baumann EG. Comparison of results of bilateral and unilateral carotid endarterectomy five years after surgery. *Surgery* 1982;91:258-262
- Loftus CM, Quest DO. Current status of carotid endarterectomy for atheromatous disease. *Neurosurgery* 1983;12:718-723
- Mullan S, Duda EE, Patro NAS. Some examples of balloon technology in neurosurgery. *J Neurosurg* 1980;52:321-329
- Bockenheimer SAM, Mathias K. Percutaneous transluminal angioplasty in arteriosclerotic internal carotid artery stenosis. *AJNR* 1983;4:791-792
- Belan A, Vesela M, Vanek I, Weiss K, Peregrin JH. Percutaneous transluminal angioplasty of fibromuscular dysplasia of the internal carotid artery. *Cardiovasc Intervent Radiol* 1982;5:79-81
- Smith DC, Smith LL, Hasso AN. Fibromuscular dysplasia of the internal carotid artery treated by operative transluminal balloon angioplasty. *Radiology* 1985;155:645-648
- Morris GC, Lechter A, DeBakey ME. Surgical treatment of fibromuscular disease of the carotid arteries. *Arch Surg* 1968;96:636-643
- Crawford ES, DeBakey ME, Morris GC Jr, Howell JF. Surgical treatment of occlusion of the innominate, common carotid and subclavian arteries. *Surgery* 1969;65:17-31
- Beebe HG, Start K, Johnson ML, Jolly PC, Hill LD. Choices of operation for subclavian-vertebral arterial disease. *Am J Surg* 1980;139:616-623