



## Discover Generics

Cost-Effective CT & MRI Contrast Agents



FRESENIUS  
KABI

WATCH VIDEO

# AJNR

### **MR imaging of prolactin-secreting microadenomas.**

K W Pojunas, D L Daniels, A L Williams and V M Haughton

*AJNR Am J Neuroradiol* 1986, 7 (2) 209-213

<http://www.ajnr.org/content/7/2/209>

This information is current as  
of June 22, 2025.

# MR Imaging of Prolactin-Secreting Microadenomas

Kathleen W. Pojuna<sup>1</sup>  
David L. Daniels  
Alan L. Williams  
Victor M. Haughton

Eight proven and three presumed prolactin-secreting microadenomas were studied with magnetic resonance (MR) imaging. All 11 cases had CT evidence of a tumor. Technical factors for MR included use of 1.3–1.5 T MR systems, 3 mm slice thickness, short repetition time (TR) (T1-weighted) and long TR (T2-weighted) spin-echo pulse sequences. Six microadenomas were demonstrated with MR. Four tumors had a long T1 and long T2, one had a long T1 and short T2, and one bromocriptine-treated tumor had a short T1 and short T2. MR failed to delineate the focal mass within the pituitary gland in the other five patients. The cause of the MR failures was not determined; however, tumor size did not appear to be a factor. MR signals arising from microadenomas are variable and possibly related to the activity of the prolactin-secreting cells. Correlation of findings from MR imaging, spectroscopy, and electron microscopy may lead to an understanding of the variable MR appearance of microadenomas.

The magnetic resonance (MR) characteristics of prolactin-secreting microadenomas have not been described because the high-resolution techniques necessary to detect these small tumors have been developed only recently. We studied normal volunteers and patients with laboratory and CT evidence of a tumor to determine the MR appearance of a microadenoma.

## Subjects and Methods

Eleven women aged 22–37 years with secondary amenorrhea, galactorrhea, hyperprolactinemia, and a proven microadenoma were studied with MR. Cases were proven either by surgical verification of a microadenoma (four cases) or by hyperprolactinemia greater than 100 ng/ml together with CT evidence of a microadenoma and failure to identify any other etiology of hyperprolactinemia (four cases). CT evidence of a microadenoma was defined by the presence of a discrete low-density area smaller than 1 cm within the pituitary gland [1, 2]. In three cases a presumptive diagnosis of microadenoma was made because, although CT showed evidence of a microadenoma, serum prolactin was only moderately elevated to 55–70 ng/ml. Two patients taking bromocriptine at the time of their MR studies had normal serum prolactin levels. For comparison, 10 asymptomatic volunteers were examined with MR.

The patients and volunteers were studied on one of two MR imaging systems. Seven patients and seven volunteers underwent MR imaging on a prototype General Electric superconducting magnet operating at 1.3, 1.4, or 1.5 T. Four patients and three volunteers were studied with the GE Signa MR system that uses a 1.5 T superconducting magnet.

The MR technique included a sagittal localizer scan followed by contiguous 3 mm coronal scans from the tuberculum to the dorsum sellae; one or two signal acquisitions; 128 × 256 or 256 × 256 matrix; and 2-D multislice or single-slice data acquisition. Images in axial and sagittal planes were obtained in some cases. Each slice location was imaged with both a short repetition time (TR) (300–800 msec) with a 14–25 msec echo delay (TE) and a long TR (2000 or 2500 msec) with 25, 50, 75, and 100 msec TEs. No gaps were present between sections obtained with the short TR sequence. A gap of 0.6–1.5 mm occurred between slices obtained with the long pulsing sequence.

Received July 12, 1985; accepted after revision October 6, 1985.

Presented at the annual meeting of the American Society of Neuroradiology, New Orleans, February 1985.

<sup>1</sup> All authors: Department of Radiology, Medical College of Wisconsin, Froedtert Memorial Lutheran Hospital, 9200 W. Wisconsin Ave., Milwaukee, WI 53226. Address reprint requests to K. W. Pojuna.

**AJNR 7:209–213, March/April 1986**

0195–6108/86/0702-0209

© American Society of Neuroradiology



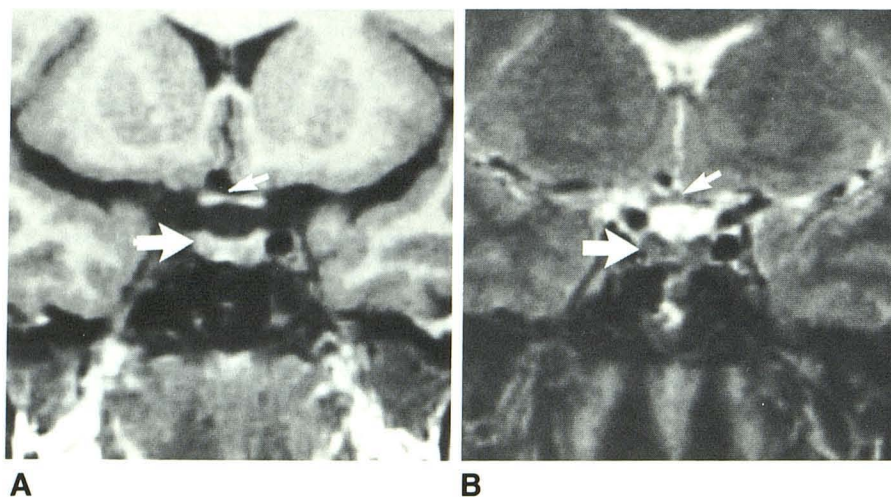


Fig. 1.—Coronal MR images of pituitary gland in normal volunteer. **A**, Short TR image (400 msec TR, 14 msec TE). Pituitary gland (*large arrow*) and optic chiasm (*small arrow*) have homogeneous signal intensity intermediate between that of fat (white) and CSF (black). **B**, Long TR image (2000 msec TR, 100 msec TE). Pituitary gland (*large arrow*) has uniform signal. Optic chiasm (*small arrow*) is more difficult to distinguish.

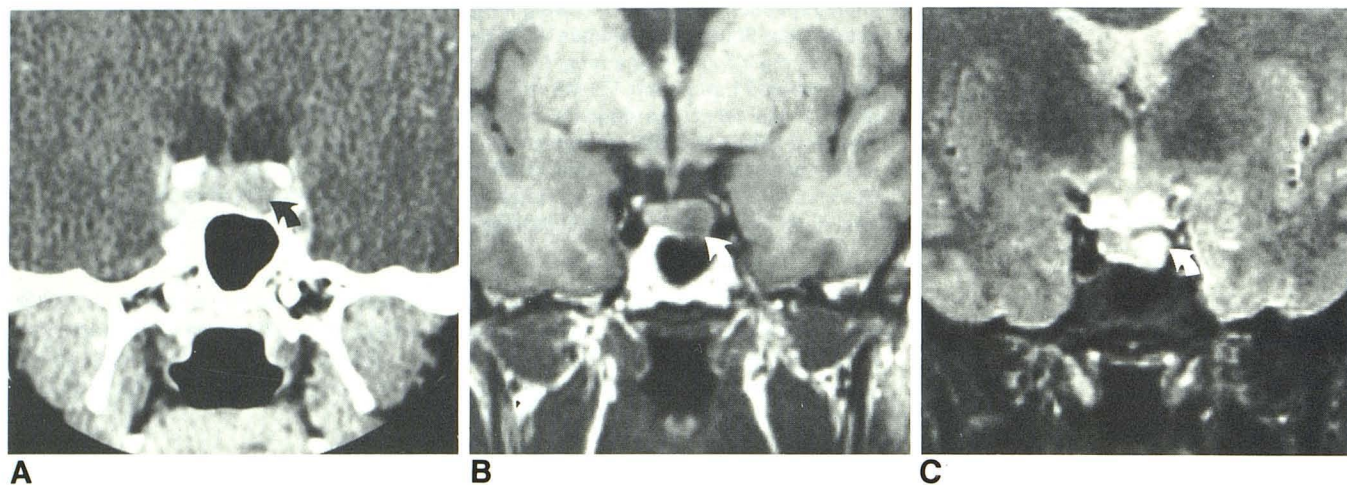


Fig. 2.—Most common MR appearance of microadenoma. **A**, CT scan. Microadenoma (*arrow*) is well defined low-density mass. **B**, Short TR image (400 msec TR, 14 msec TE). Microadenoma (*arrow*) is focal mass having low-

intensity signal. **C**, Long TR image (2000 msec TR, 75 msec TE). Microadenoma (*arrow*) has signal intensity higher than that of normal pituitary tissue. Microadenoma was subsequently verified surgically.

## Results

The normal pituitary gland has a homogeneous signal of intermediate intensity, a midline infundibulum, and a straight or slightly concave superior border. The anterior and posterior lobes of the pituitary gland cannot be distinguished on the basis of MR signal. Morphology of the pituitary fossa was demonstrated best on images obtained with the short TR spin-echo pulse sequence. As TR and TE were increased, contrast between the contents of the pituitary fossa and cerebrospinal fluid (CSF) decreased, making identification of the pituitary gland and structures within the suprasellar cistern more difficult (fig. 1).

Five of the proven microadenomas were demonstrated by MR. Four of these were characterized by prolonged T1 and T2 relaxation times. The tumors appeared as sharply defined

regions of low-intensity signal on short TR images and as areas of high-intensity signal on long TR images (fig. 2). The region of abnormal signal intensity on MR corresponded in size and location to the low-attenuation area present on the CT scans. Included in this group of four was a patient who had undergone surgical biopsy of a prolactinoma 6 years prior to MR and who was taking bromocriptine. The bromocriptine-treated residual microadenoma appeared no different from the three untreated tumors. The fifth surgically proven microadenoma demonstrated by MR had relatively long T1 and short T2 relaxation times (fig. 3). This patient had been treated with bromocriptine but discontinued the medication 3 months before MR. Serum prolactin level at the time of the MR examination was 78 ng/ml.

In three proven cases and two presumptive cases, MR revealed no focal abnormality within the pituitary gland. The



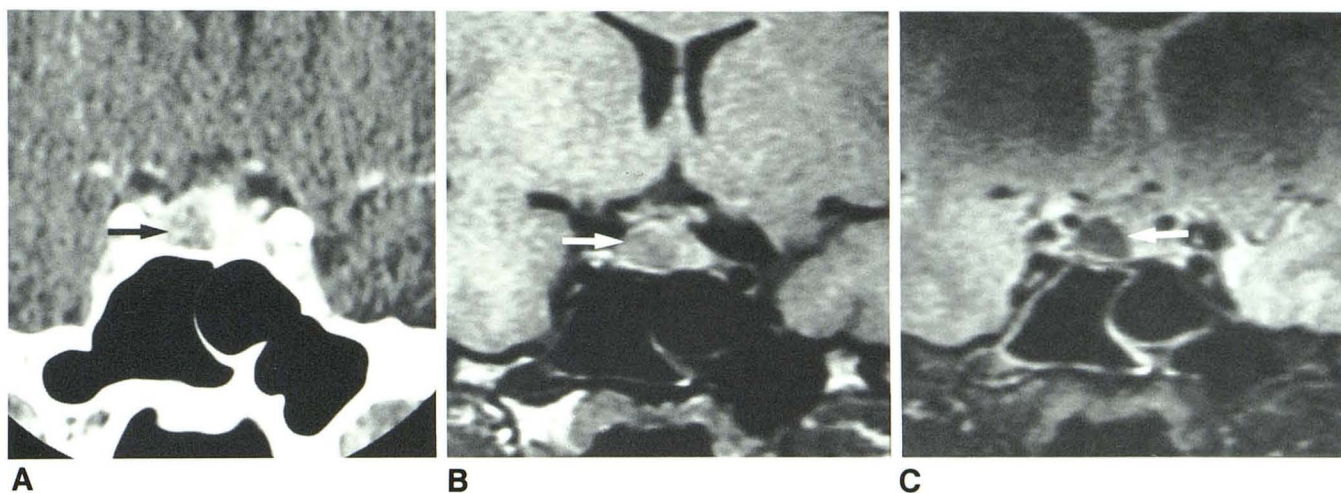


Fig. 3.—Subsequently proven microadenoma having long T1 and short T2. A, CT scan shows tumor (arrow). B, Short TR sequence (800 msec TR, 25

msec TE). Microadenoma (arrow) has typical weak signal. C, Long TR image (2500 msec TR, 75 msec TE). Again, tumor (arrow) has low-intensity signal.

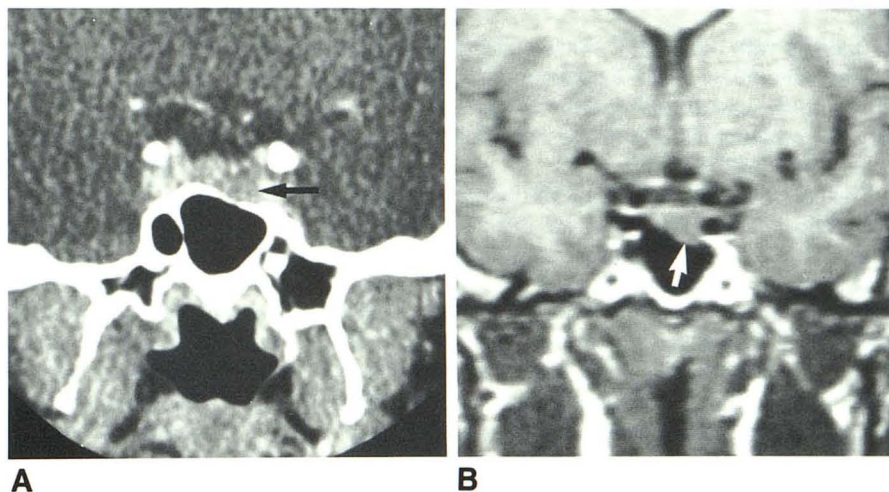


Fig. 4.—Verified microadenoma more effectively shown by CT than MR. A, CT scan reveals focal low-density mass (arrow) associated with thinning and sloping of sellar floor. B, Short TR image shows sloping of the sellar floor (arrow), but pituitary gland has normal homogeneous signal intensity.

pituitary gland had normal homogeneous signal intensity on both T1- and T2-weighted pulse sequences. In two proven cases, the sellar floor was noted to slope inferiorly on MR at the site of the microadenoma as demonstrated on CT and at surgery (fig. 4). Three pituitary glands had convex upper margins on CT and MR. One gland measured 10 mm in height but the other four had maximum heights of less than 8 mm. Microadenoma size, as shown by CT, did not differ significantly between tumors in which MR was positive and those in which it was negative.

One presumed microadenoma had unique MR characteristics. The patient was taking bromocriptine at the time of CT and MR studies and had a serum prolactin level of less than 5 ng/ml. The tumor appeared as a focal area of intense signal on short TR images and relatively weak signal on long TR images (fig. 5). The short T1 and short T2 contrasted with

the more common MR pattern of relatively prolonged T1 and T2 relaxation times.

### Discussion

Experience with high-resolution MR imaging of pituitary microadenomas is very limited. A single report describes an abnormality with a short T1 on a sagittal spin-echo image that was thought to represent a microadenoma [3]. The study was performed with a 10 mm slice thickness, and therefore partial-volume averaging made interpretation of inhomogeneous signal intensities within the pituitary gland difficult.

Patients and volunteers in our series were examined with high-resolution MR techniques. However, our sample size was small and results biased because only those patients with abnormal CT scans were imaged with MR. The number



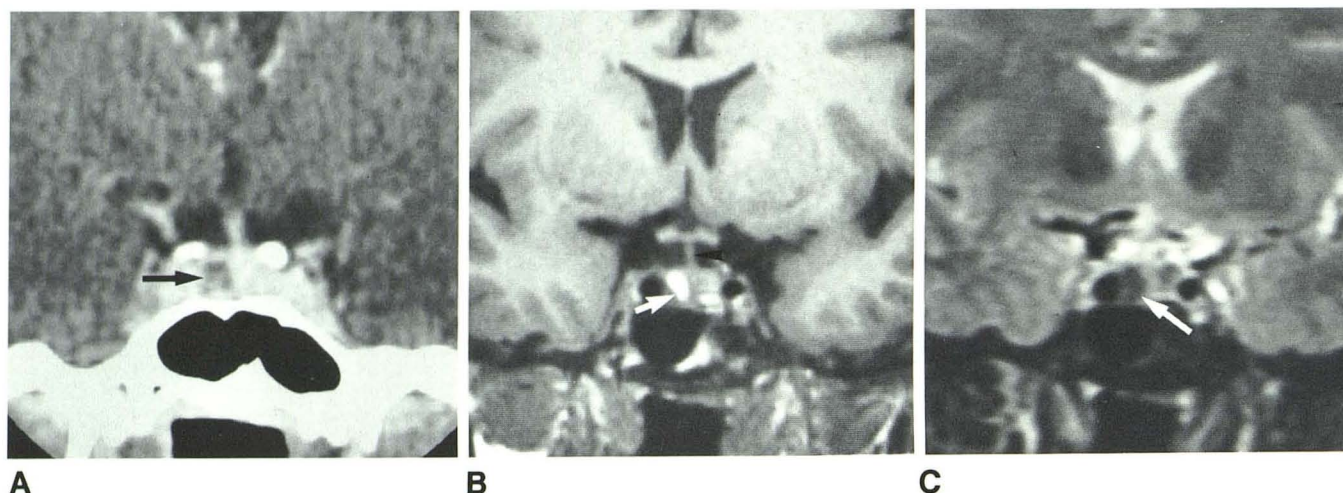


Fig. 5.—Bromocriptine-treated microadenoma having short T1 and short T2 relaxation times. **A**, Microadenoma (arrow) appears as typical low-density mass. **B**, Short TR image (400 msec TR, 14 msec TE). Tumor (arrow) has high

signal intensity. Infundibulum (arrowhead) is displaced from midline by tumor. **C**, Long TR image (2000 msec TR, 75 msec TE). Tumor (arrow) has weak signal.

of patients with normal CT studies and abnormal MR examinations cannot be determined from our study. The objective of our study was to describe the MR characteristics of pituitary microadenomas and not to compare the specificity and sensitivity of MR with CT.

The normal pituitary gland has a uniform signal intensity on spin-echo images, regardless of the pulse TR selected. A short TR pulse sequence most effectively displays the anatomy of the pituitary fossa. Images with long TR and TE were no more sensitive than the short TR images. Furthermore, it was difficult to distinguish the pituitary gland from CSF on long TR/TE images. A short TR pulse sequence may be more able to screen the pituitary fossa and a long TR/TE sequence to confirm and characterize any abnormalities.

The contents of the pituitary fossa were easiest to evaluate in the coronal plane. This may be in part because of experience in direct coronal CT scanning of the sella. Partial-volume averaging of parasellar vascular and CSF structures, which may simulate a microadenoma on axial or sagittal images, is minimized in the coronal plane. The chemical shift artifact, which may be misinterpreted as a microadenoma, is also minimized in the coronal plane [4].

MR demonstrated a focal region of abnormal signal within the pituitary gland in six of 11 patients with microadenomas. A microadenoma most often appeared as a sharply marginated mass having longer T1 and T2 relaxation times than normal pituitary tissue. Four proven microadenomas had these MR findings.

Two tumors had different MR characteristics. One patient, taking bromocriptine, had a tumor with a short T1 and short T2. The other tumor, in a patient who had discontinued bromocriptine 3 months before MR, had a long T1 and short T2. It is not possible to determine why these two tumors had unique MR findings. However, bromocriptine therapy is one possible factor affecting the appearance of these two mi-

croadenomas. Bromocriptine does not usually cause necrosis or infarction of pituitary tissue but inhibits protein synthesis in prolactin-secreting cells. Histologic changes in bromocriptine-treated tumors include decreased cell volume and loss of rough endoplasmic reticulum [5]. Perhaps changes in prolactinoma cell ultrastructure result in altered MR signals. The MR signal may be related to the prolactin-producing cell's activity. Therefore bromocriptine may play a role in altering tumor signal intensity.

MR failed to demonstrate a focal region of abnormal signal in three proven and two presumed microadenomas. Tumor size, as shown on CT, was not the significant factor in the failure to demonstrate the tumors. Comparable pulse sequences were used in all cases. Since the inversion-recovery pulse sequence was not used, its utility when the spin-echo technique proves ineffective is not known.

More experience with MR of prolactin-secreting microadenomas is necessary before any consistent pattern of MR findings can be identified and understood. A prospective study with MR before and after the institution of bromocriptine therapy would determine whether bromocriptine does alter tumor appearance. Correlation of MR with the results of electron microscopy and MR spectroscopy of tumor specimens may lead to an understanding of the variable MR appearance of microadenomas. Currently, all that may be concluded is that microadenomas usually have a prolonged T1 and T2, but sometimes have a short T1 and/or short T2, or a signal intensity that is no different than normal pituitary tissue.

MR, if positive, may have utility as a means of following patients with microadenomas. The obvious advantages of MR over CT include lack of ionizing radiation and intravenous contrast material. Furthermore, many patients find the neck hyperextension necessary for direct coronal CT imaging quite uncomfortable. MR techniques that can reliably demonstrate

microadenomas must be identified before MR can be used as a screening examination in patients with hyperprolactinemia.

#### REFERENCES

1. Syvertsen A, Haughton VM, Williams AL, et al. The computed tomographic appearance of the normal pituitary gland and pituitary microadenomas. *Radiology* **1979**;133:385-391
2. Hemminghytt S, Kalkhoff RK, Daniels DL, et al. Computed tomographic study of hormone-secreting microadenomas. *Radiology* **1983**;146:65-69
3. Bilaniuk LT, Zimmerman RA, Wehrli FW, et al. Magnetic resonance imaging of pituitary lesions using 1.0 to 1.5 T field strength. *Radiology* **1984**;153:415-418
4. Mark L, Pech P, Daniels DL, et al. The pituitary fossa: a correlative anatomic and MR study. *Radiology* **1984**;153:453-457
5. Rengachary SS, Tomita T, Jefferies BF, et al. Structural changes in human pituitary tumor after bromocriptine therapy. *Neurosurgery* **1982**;10:251-252