



## Discover Generics

Cost-Effective CT & MRI Contrast Agents



FRESENIUS  
KABI

WATCH VIDEO

# AJNR

### CT of pituitary microadenomas.

J F Bonneville, F Cattin and J L Dietemann

*AJNR Am J Neuroradiol* 1985, 6 (4) 650

<http://www.ajnr.org/content/6/4/650.citation>

This information is current as  
of June 3, 2025.

# Correspondence

## CT of Pituitary Microadenomas

In reading the well documented article by Davis et al. [1] in the November/December 1984 issue of *AJNR*, we found the title of the article to be perhaps a bit provoking and the authors' conclusion rather severe for high-resolution computed tomography (CT) of pituitary microadenomas. Two points should be emphasized:

1. The authors are correct in stating that "gland height greater than 8 mm and an abnormal diaphragma sellae configuration are neither sensitive nor specific findings of microadenoma" [1]. This is why we are convinced that demonstration of the pituitary "tuft" sign by dynamic CT is essential for microadenoma diagnosis [2].

2. Some false-positive images, such as figure 1A in the article by Davis et al. [1], must be considered with caution. We have demonstrated [3] that partial-volume averaging can create a low-density image simulating an intrasellar hypodense lesion beneath a pseudo-bulging of the diaphragma sellae at the tuberculum sellae level, even in thin coronal sections (fig. 1)—the "tuberculum" sign. We believe this confusing image should be considered in the presence of any hypodense image within the sella.

J. F. Bonneville

F. Cattin

J. L. Dietemann

University Hospital  
25030 Besançon, France

## REFERENCES

1. Davis PC, Hoffman JC Jr, Tindall GT, Braun IF. Prolactin-secreting pituitary adenomas: inaccuracy of high-resolution CT imaging. *AJNR* 1984;5:721-726, *AJR* 1985;144:151-156
2. Bonneville JF, Cattin F, Moussa-Bacha K, Portha C. Dynamic computed tomography of the pituitary gland: the "tuft sign." *Radiology* 1983;149:145-148
3. Bonneville JF, Cattin F, Dietemann JL. *Computed tomography of the pituitary gland*. Berlin: Springer-Verlag, 1985 (in press)

## Reply

Certain errors appeared in the initial abstract of our article, which were corrected in an erratum in the January/February 1985 issue of *AJNR* (p. 38) and in the abstract as it appeared in the January 1985 issue of *AJR*. The corrected abstract is less severe than the original version. It is important, however, to recognize the limitations as well as the strengths of CT in diagnosis of microadenoma. Our findings do not negate the utility of CT for exclusion of other lesions and determination of adenoma size. With the availability of surgical proof, however, CT is clearly less accurate than earlier studies might have suggested.

Dynamic CT for demonstration of the pituitary "tuft" sign may be useful for microadenoma diagnosis; however, large series with surgical confirmation would be required to establish its accuracy. Our attempts to use this tool have been largely unsuccessful. In our experience, patients tend to swallow, move, or vomit when the contrast bolus is administered, resulting in a low success rate in performing these studies.

We certainly agree that volume averaging may result in a false-positive image either far anterior or posterior in the sella. In the patient with a convex diaphragma sellae and elevated prolactin, however, it remains difficult to discount a well defined focal lesion of the size of those depicted.

Patricia C. Davis

James C. Hoffman, Jr.

George T. Tindall

Ira F. Braun

Emory University Hospital

Atlanta, GA 30322

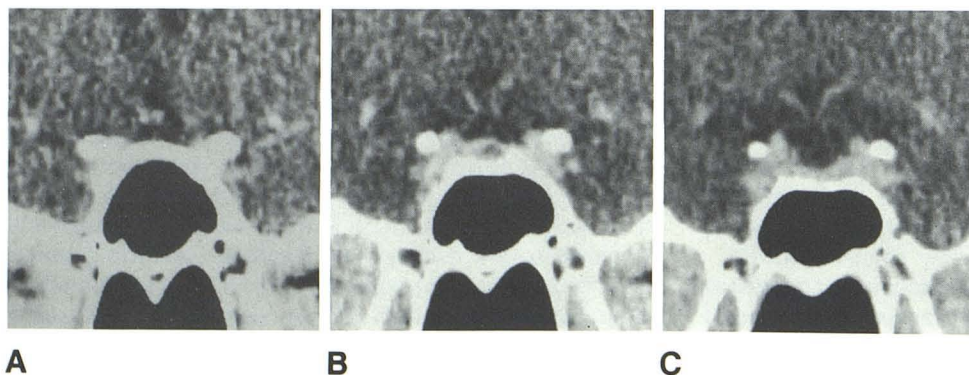


Fig. 1.—"Tuberculum" sign: A-C, 1.5-mm-thick, consecutive coronal CT scans with contrast enhancement. In B, partial-volume averaging at level of tuberculum sellae and anterior wall of sella simulates low-density intrasellar lesion beneath pseudo-bulging of diaphragma sellae.