



Discover Generics

Cost-Effective CT & MRI Contrast Agents



WATCH VIDEO

AJNR

New calibrated-leak microcatheters for cyanoacrylate embolization and chemotherapy.

C W Kerber and C B Heilman

AJNR Am J Neuroradiol 1985, 6 (3) 434-436

<http://www.ajnr.org/content/6/3/434.citation>

This information is current as
of June 6, 2025.

New Calibrated-Leak Microcatheters for Cyanoacrylate Embolization and Chemotherapy

Charles W. Kerber¹ and Carl B. Heilman²

A soft microcatheter developed 8 years ago has given radiologists the ability to explore and treat hypervascular lesions of the brain and spinal cord [1, 2] and to infuse chemotherapeutic agents beyond the ophthalmic artery. The microcatheter had a single lumen and ended in a balloon with a calibrated leak. If the leak size was appropriate, then the first part of the injection would expand the balloon; more pressure on the syringe would cause fluid to leak from its tip.

This system became known as the calibrated-leak microcatheter and allowed superselective angiography, and then delivery of liquid embolic agents or chemotherapeutic agents close to vascular intracranial [3] and abdominal anomalies [4]. By 1983, we had used more than 200 of these catheters in the central nervous system of more than 60 patients without rupturing any blood vessel [5, 6], but reports by others showed such rupture to be possible [7–9], and FDA permission to manufacture the device was withdrawn.

That withdrawal furnished the impetus to improve the original prototypical design and to incorporate ideas gained from others' experience. This report describes the new calibrated-leak catheters, discusses the rationale for the changes, and reaffirms techniques that will enhance patients' safety.

Materials and Methods

All modifications of the original catheter retain the essential feature of the prototype: the single-lumen Silastic catheter and the calibrated-leak balloon at its tip. The catheter is still introduced by injection and flow guidance through a polyethylene carrier catheter placed as near the anomaly as is safe [10, 11].

We now make the balloon of latex rather than silicone and vary the leakage rate to give different responses. The original silicone balloon changed characteristics when placed in contact with contrast agent. During prolonged cases, the silicone tip would swell slightly, partially shutting off the calibrated leak. Then, an attempted rapid delivery of adhesive without fluoroscopic analysis of balloon size was more likely to overinflate the balloon and rupture the vessel. Latex is not affected by contrast agent, and does not change leakage rates when in contact with contrast agents. In addition, it has a greater elastic coefficient, that is, the balloon will get bigger and still collapse to its preinflation size. Thus, a latex balloon of the same size can be

expanded more than twice as large as a silicone balloon, giving the operator greater flexibility when catheterizing large feeders.

Balloons are made with rapid, regular, or slow leakage rates by manufacturing balloons with different sizes of leakage holes (fig. 1). More rapid leak rates allow delivery of adhesive or chemotherapeutic agents without much balloon inflation and are used in small high-flow vessels. Slow-leak-rate balloons cause maximal balloon inflation during delivery and can thus slow blood flow during delivery into large vessels. No matter which is used, the primary safety factor is the direct real-time fluoroscopic visualization of the balloon and runoff from it during the infusion (fig. 2).

We developed a knotless ligature, a variation of the common fisherman's knot, to attach the balloon to the catheter. This is accomplished by stretching the ligature and tucking it under itself. Tying this fine latex thread poses quality-control problems for the manufacturer, but is, we believe, superior to adhesive bonding of balloon to catheter.

Usage of the system is fully described in the manufacturer's package insert (Pacific Medical Industries, San Diego, CA 92122).

Results

Catheters were first tested in a circulatory model of bent plastic tubes and flowing fluid [12] to refine the system. When the final configuration was achieved, the delivery of cyanoacrylate through the catheter was studied using direct vision and was also recorded on videotape. We attempted on multiple occasions to trap the balloon in the polymerizing mass of cyanoacrylate and then to detach the balloon from the catheter, but we were unsuccessful in trapping the balloon, probably because we were unable to duplicate exactly the conditions found in pulsatile human vessels containing circulating blood.

We then began a cautious exploration of human intracranial vessels. The first two patients, who had four catheters placed in their intracranial circulation, had no treatment, as final catheter placement was not considered appropriate. We then treated six consecutive patients on 14 different occasions, with satisfactory control of the infusion of embolic material. One patient had a slightly worsened neurologic deficit, which improved but did not return completely to normal. His arteriovenous malformation was in and around the motor strip. He

Received August 4, 1983; accepted after revision September 6, 1984.

¹ Alvarado X-Ray Medical Group, Inc., San Diego, CA 92120. Address reprint requests to C. W. Kerber.

² University of Pennsylvania School of Medicine, Philadelphia, PA 19104.

Fig. 1.—Microcatheter and balloon. **A**, Latex balloon is attached to black microcatheter with knotless ligature. Multiple wraps of ligature help prevent inadvertent detachment of balloon during intracranial manipulation. **B**, Pushing on plunger of syringe attached to proximal end of catheter causes balloon to inflate only slightly, but fluid can leak to maximal rate of 0.8–1 ml/sec. **C**, Pushing more vigorously causes balloon to expand. Fluid continues to leak from its tip.

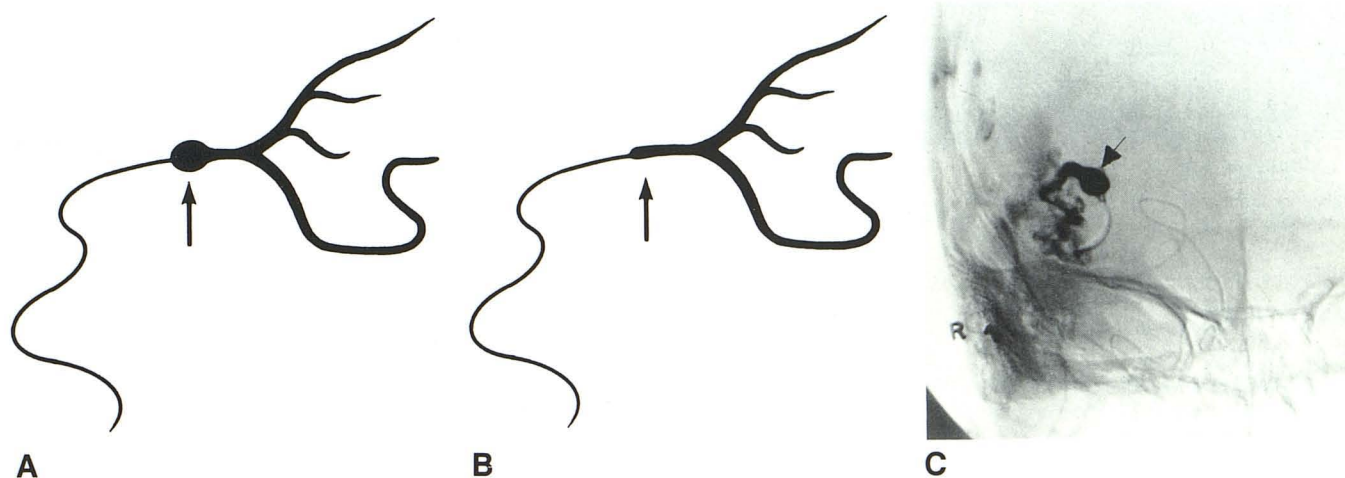
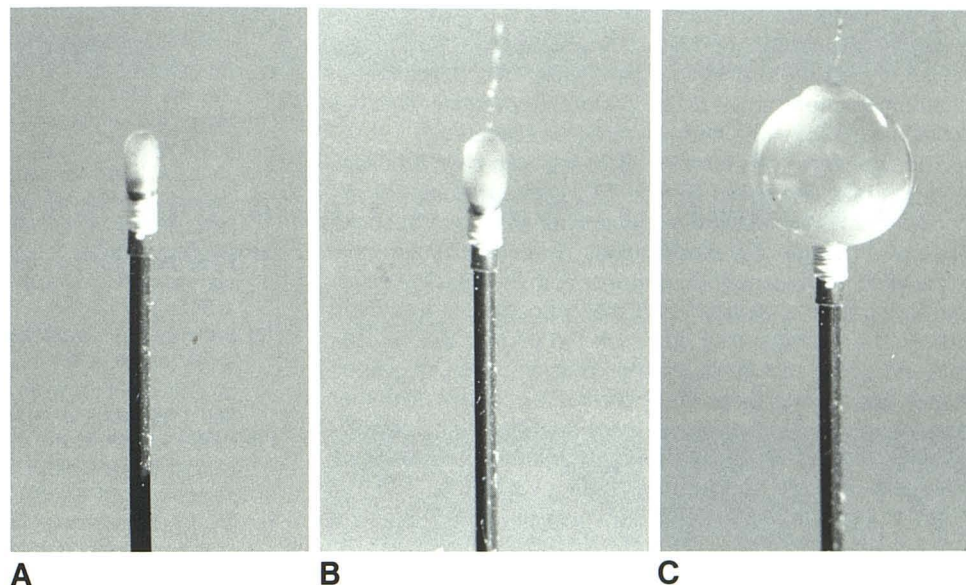


Fig. 2.—Vessel will not rupture unless balloon is inflated to significantly larger diameter than that of vessel. Using fluoroscope, watch balloon inflate, and stop inflation when its size barely exceeds vessel's size. **A**, Balloon (arrow) is overinflated. Note normal size of vessel distal to balloon. Although one can often inflate balloons to double diameter of parent vessel, not all arteries will tolerate such stretching. **B**, Here balloon expands artery only slightly, yet still

obstructs vessel. That degree of inflation can be controlled by fluoroscopic inspection. **C**, Frontal, subtraction view of superselective middle cerebral artery injection. This balloon (arrow) was overinflated accidentally. Shortly after these films were exposed, patient had subarachnoid hemorrhage. Fortunately, recovery was complete. (Film courtesy of colleague.)

is still functional and at work. One patient with thalamic and optic radiation lesion developed a partial homonymous field deficit.

No complications were caused by the new catheter, and it was our subjective impression that the treatments were carried out with a greater feeling of ease and control when we compared this device to the old system, which used a silicone catheter and a silicone balloon.

Discussion

Intracranial embolic techniques are developing surely but with measured gait. From the first methacrylate spheres in

1960 [13] to endovascular intracranial balloons [14], 14 years passed. Zanetti and Sherman's [15] human experience was detailed only in 1972. Our own intracranial treatments were not reported until 1975 [1]. Since then, fewer than 150 patients appear to have been treated by cyanoacrylate infusion (personal communications, various authors). Progress is slow because neuroradiologists have shown restraint and good judgment in choosing their first patients, and few disasters have thus occurred. The critical nature of the end organ has made us all appropriately cautious. The patient's safety depends on many factors, but the one most in need of improvement is our basic tool, the exploring microcatheter and its attendant delivery system. The system must be simple,

so that the radiologist can think about the patient and not about technique. It must be flexible enough to pass through tortuous arteries, and it must be reliable. The deposition of chemotherapeutic agent or, even more, of cyanoacrylate is a moment of truth—one that can rarely be repeated.

The equipment has steadily improved, has been modified, and has been simplified [7, 16, 17]. Complications will still occur, and further design improvements must be expected. For now, though, the modifications described above have allowed an improvement in control of both the baseline selective intracranial angiogram and the deposition of treatment agent. The operator may now pick the correct balloon leak rate and size to match his patient's problem. The use of latex rather than silicone keeps the delivery rate constant no matter how long the procedure, giving more confidence and security to the operator. The result is greater flexibility, more choices, and ultimately, greater patient safety.

REFERENCES

1. Kerber CW. Intracranial cyanoacrylate: a new catheter therapy for arteriovenous malformation. *Invest Radiol* 1975;10:536-538
2. Kerber CW. Balloon catheter with a calibrated leak. *Radiology* 1976;120:547-550
3. Kerber CW, Bank WO, Cromwell LD. Calibrated leak balloon microcatheter: a device for arterial exploration and occlusive therapy. *AJR* 1979;132:207-212
4. Kerber CW, Freeney PC, Cromwell LD, Margolis MT. Cyanoacrylate occlusion of a renal arteriovenous fistula. *AJR* 1977;128:663-665
5. Kerber CW, Bank WO, Cromwell LD. Complication of intracranial cyanoacrylate embolization. Presented at the annual meeting of the Society of Interventional Radiology, Val d'Isere, France, January 1982
6. Bank WO, Kerber CW, Cromwell LD. Treatment of intracerebral arteriovenous malformations with isobutyl-2-cyanoacrylate: initial clinical experience. *Radiology* 1981;139:609-616
7. Debrun GM, Vinuela FV, Fox AJ, Kan S. Two different calibrated leak balloons. *AJNR* 1982;3:407-414
8. Prager RJ, Debrun G, Wolpert SM. Intracranial hemorrhage as a complication of therapeutic embolization (abstr). *AJNR* 1980;1:357
9. Berenstein A. Transvascular fracture and repair of a cerebral artery (abstr). *AJNR* 1980;1:358
10. Schneider JM. Intravenous catheterization: traditional difficulties and a revolutionary new technique. *Hosp Care* 1971;2:3-8
11. Dotter CT, Rosch J, Lakin PC, et al. Injectable flow-guided coaxial catheters for selective angiography and controlled vascular occlusion. *Radiology* 1972;104:421-423
12. Kerber CW, Flaherty LW. A teaching and research simulator for therapeutic embolization. *AJNR* 1980;1:167-169
13. Luessenhop AJ, Spence WT. Artificial embolization of cerebral arteries. *JAMA* 1960;172:1153-1155
14. Serbinenko FA. Balloon catheterization and occlusion of major cerebral vessels. *J Neuroradiol* 1974;41:125-145
15. Zanetti PH, Sherman FE. Experimental evaluation of a tissue adhesive as an agent for the treatment of aneurysms and arteriovenous anomalies. *J Neuroradiol* 1972;36:72-79
16. Pevsner P, Doppman JL. Therapeutic embolization with a microballoon catheter. *AJNR* 1981;1:171-181
17. Pevsner P. Microballoon catheter for superselective angiography and therapeutic occlusion. *AJR* 1977;128:225-230