



## Discover Generics

Cost-Effective CT & MRI Contrast Agents



WATCH VIDEO

# AJNR

## Results of percutaneous transluminal angioplasty.

J J Vitek

*AJNR Am J Neuroradiol* 1985, 6 (2) 299-300

<http://www.ajnr.org/content/6/2/299.1.citation>

This information is current as  
of June 14, 2025.

## Therapeutic Embolization for Vascular Headache

Headache relief after embolic treatment of intracranial arteriovenous malformations (AVMs) has been a gratifying and significant result of that treatment [1]. On several occasions, patients whose primary presenting complaint was headache have felt so much better after occlusion of the dural and scalp supply that they were reluctant to proceed with subsequent more definitive treatment of the central AVM. Thus, we wondered if it would be possible to treat patients with vascular headache by occluding the blood supply to the external carotid circulation using particulate embolization.

Because of the potential for disastrous complications, criteria for patient selection were rigid: Patients had to be free of major psychiatric illness and desperate for treatment. Conventional therapies (excluding narcotics) had to have failed. Three vascular headache patients satisfied our criteria and were treated with particulate embolization of the extracranial branches on the side of their headache. Using direct fluoroscopic monitoring [2, 3], a mixture of particles of polyvinyl alcohol and Gelfoam [4] was infused. Proximal occlusion was reinforced with Gianturco coils in each patient. All three patients had dramatic relief of pain. One has remained nearly symptom-free, having had only one headache during the year since embolization. A follow-up arteriogram in this patient showed trivial recanalization through the axes of the proximal occluding coils. The second patient has developed headache on the opposite side but none on the treated side.

We recognize the important (and usually primary) emotional component of headache and handle this aspect with physician support and direction, including psychotherapy. Perhaps of more importance are our limited but fundamental observations of vascular behavior during embolization. Our preliminary analyses indicate that proximal arterial dilatation in the face of distal spasm (fig. 1) is the physiologic

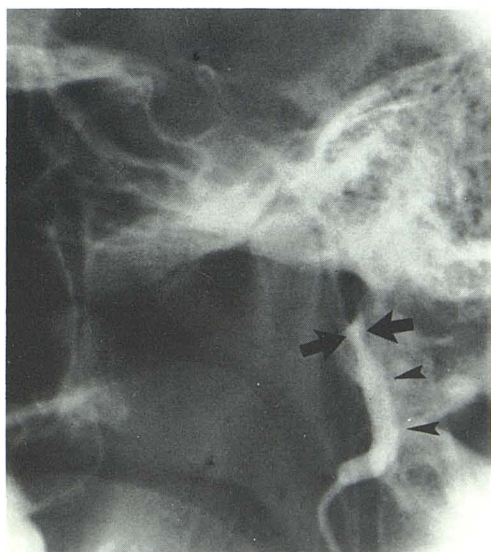


Fig. 1.—Direct catheterization of and injection of metrizamide into this vessel caused remarkable spasm. Arrows show arterial cutoff point; no flow readily passed beyond this point, but gentle pressure of embolization with meticulous fluoroscopic monitoring in subtracted fluoroscopic mode showed passage of particles under only slightly increased pressure. Arrowheads indicate dilated proximal internal maxillary artery. As this happened, patient reported onset of a severe migraine. As we decreased tension by aspirating gently on syringe attached to catheter, vessel collapsed somewhat and pain abated.

counterpart of a water hammer and is the direct cause of migraine pain.

Joseph A. Horton  
University of Pittsburgh School of Medicine  
Pittsburgh, PA 15261  
Charles W. Kerber  
University of California, San Diego Medical Center  
San Diego, CA 92103

## REFERENCES

1. Bank WO, Kerber CW, Cromwell LD. Treatment of intracerebral arteriovenous malformations with isobutyl-2-cyanoacrylate. *Radiology* 1981;139:609-616
2. Kerber CW. Catheter therapy: fluoroscopic monitoring of deliberate embolic occlusion. *Radiology* 1977;125:538-540
3. Kerber CW. Flow-controlled therapeutic embolization: a physiologic and safe technique. *AJNR* 1980;1:77-81, *AJR* 1980;134:557-561
4. Horton JA, Marano GD, Kerber CW, Jenkins JJ, Davis S. Polyvinyl alcohol foam-Gelfoam for therapeutic embolization: a synergistic mixture. *AJNR* 1983;4:143-147

## Results of Percutaneous Transluminal Angioplasty

I read with great interest the two case reports on percutaneous transluminal angioplasty (PTA) of the internal carotid arteries in the September/October 1984 issue of *AJNR*. In each case, the results of PTA were not really satisfactory. In the case reported by O'Leary and Clouse [1], the stenotic area in the most proximal part of the cavernous segment of the carotid artery looks almost the same after PTA (their figs. 1E and 1F) as before (figs. 1A and 1B). In the Discussion, the authors point out the partial restenosis seen on the 30-minute follow-up film and find it "disturbing and difficult to explain."

In the article by Dublin et al. [2], dealing with PTA of the neck portion of the internal carotid artery in fibromuscular dysplasia (FMD), the postangioplasty angiogram (fig. 1B) shows virtually no change, and the figure legend states that there was "little change in areas of FMD" after angioplasty. In the Case Report section, the authors confirm that "few postdilatation angiographic changes were noted." However, they noted change in the blood pressure after PTA.

In my opinion, the angioplasty balloons used by both groups were not large enough for the vessels that were to be dilated. As Castaneda-Zuniga et al. [3] pointed out, in order to perform transluminal angioplasty successfully, the lesion within the intima and media has to be disrupted. This can be achieved only by using a balloon of the appropriate size in relation to the caliber of the artery. The petrous and cavernous segments of the internal carotid artery cannot be successfully dilated with balloons of 3.5 mm (inflatable) diameter, and a balloon of 4 mm (inflatable) diameter is insufficient for the neck segment of the internal carotid artery. For successful angioplasty, the diameter of the balloon must be slightly larger than the normal diameter of the vessel. In performing angioplasties on the origin of the external carotid artery in our institution, we use balloons of 6 mm (inflatable) diameter; for the subclavian arteries, the balloons are a minimum of 8 mm (inflatable) diameter.

It is well known that the immediate postangioplasty controlled arteriogram need not reflect the final result of the procedure. On the other hand, the appearance of successful dilatation on the immediate



postprocedure controlled studies is directly related to the appearance of successful dilatation of the stenotic segment on the long-term follow-up arteriograms and correlates with the clinical success. Unfortunately, for ethical reasons, long-term follow-up studies are not always possible.

Jiri J. Vitek  
University of Alabama in Birmingham  
Birmingham, AL 35294

#### REFERENCES

1. O'Leary DH, Clouse ME. Percutaneous transluminal angioplasty of the cavernous carotid artery for recurrent ischemia. *AJNR* 1984;5:644-645
2. Dublin AB, Baltaxe HA, Cobb CA III. Percutaneous transluminal carotid angioplasty and detachable balloon embolization in fibromuscular dysplasia. *AJNR* 1984;5:646-648
3. Castaneda-Zuniga WR, Formanek A, Tadavarthy M, et al. The mechanism of balloon angioplasty. *Radiology* 1980;135:565-571

#### Reply

Dr. Vitek suggests that the results of PTA for treatment of fibromuscular dysplasia, as reported by myself and others, are "not really satisfactory." He criticizes the lack of postdilatation change in the size and configuration of the vessel as compared to the predilatation angiogram. On the other hand, as he states in his last paragraph,

"the immediate postangioplasty controlled arteriogram need not reflect the final result of the procedure." I would agree with this statement. The fact that our procedure alleviated the pressure gradient speaks for itself. Several authors have noted that angiographic results after angioplasty may not reflect pressure-gradient changes nor blood-flow changes. Blood flow, as measured by video dilution technique, has been studied extensively [1, 2]. These articles point out that whereas vessel configuration and postangioplasty angiographic results usually correlate with changes in pressure gradient and/or flow, this is not necessarily true in the individual case. Thus, apparent angiographic successes may not be pressure-gradient or blood-flow successes. On the other hand, little change in the appearance of a stenosis may reflect improved blood flow and obliteration of a pressure gradient.

The long-term effects of PTA on fibromuscular dysplasia of the carotid artery remain to be investigated, and we await the accumulation of a larger data set.

Arthur B. Dublin  
University of California, Davis  
Sacramento, CA 95817

#### REFERENCES

1. Lantz BMT, Link DP, Lewis EL, Foerster JM, Lee G. Renal artery blood flow assessed by video dilution technique before and after percutaneous transluminal angioplasty. *Acta Radiol [Diagn] (Stockh)* 1981;22:49-57
2. Lantz BMT, Dublin AB, McGahan JP, Link DP. Carotid blood flow in man determined by video dilution technique: II. Vascular abnormalities. *AJNR* 1982;3:295-303