



Providing Choice & Value

Generic CT and MRI Contrast Agents



**FRESENIUS
KABI**

CONTACT REP

AJNR

Saccular aneurysm of the proximal left common carotid artery.

J E Knake, T O Gabrielsen and R M Zwolak

AJNR Am J Neuroradiol 1985, 6 (2) 296-297

<http://www.ajnr.org/content/6/2/296.citation>

This information is current as
of July 19, 2025.

Saccular Aneurysm of the Proximal Left Common Carotid Artery

James E. Knake,¹ Trygve O. Gabrielsen,¹ and Robert M. Zwolak²

Aneurysms of any part of the extracranial carotid artery are uncommon lesions [1–6], and those involving just the common carotid segment may appropriately be considered rare. Although fusiform enlargement of the mediastinal segment of the left common carotid artery can occur in atherosclerotic disease and in association with syphilitic and other forms of aortitis, a saccular form of aneurysm in this location has been recorded only in a few instances after blunt chest trauma [7–9], and all have been designated as pseudoaneurysms. We report an apparently unique case of saccular aneurysm of the left common carotid artery root in a patient without history of trauma or sepsis.

Case Report

A 60-year-old man experienced occasional "dizziness" and worsening memory. Arch aortography and cerebral angiography at another hospital revealed a 1 × 2 cm saccular aneurysm of the most proximal part of the left common carotid artery (fig. 1A). The patient was referred to the University of Michigan Hospitals, where he appeared to be a healthy man in no obvious distress. His blood pressure, peripheral pulses, and cardiac rhythm were normal. His medical history included hospitalization only for uncomplicated lumbar laminectomy. Specifically, there was no history of chest trauma or other significant bodily trauma, nor of sepsis or other major illness. He took no medications and had no allergies.

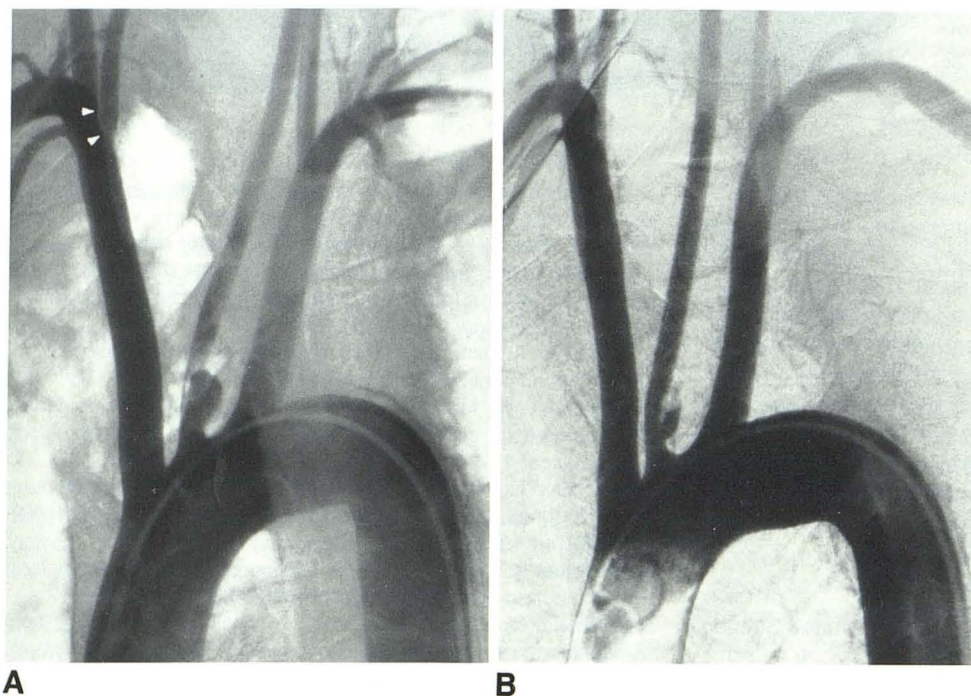


Fig. 1.—A, Initial arch aortogram in standard right posterior oblique projection. The 1 × 2 cm saccular aneurysm appears to arise directly from base of left common carotid artery, and its bulk compromises lumen of parent vessel. Only evidence of atherosclerotic disease is shallow defect in right subclavian artery just beyond right vertebral artery origin (arrowheads). B, 7 weeks later. Volume of patent lumen of aneurysm has been reduced by intraluminal thrombosis. Aneurysm clearly arises from left common carotid artery itself and not from aortic junction. On this occasion, aneurysm could not be detected on aortography in usual right posterior obliquity, and considerably steeper degree of obliquity was required.

Received December 21, 1983; accepted January 25, 1984.

¹ Department of Radiology, Box 13, Division of Neuroradiology, University of Michigan Hospitals, Ann Arbor, MI 48109. Address reprint requests to J. E. Knake.

² Department of Surgery, University of Michigan Hospitals, Ann Arbor, MI 48109.

Repeat arch aortography after 7 weeks demonstrated a decrease in size of the patent lumen of the aneurysm, indicating that some intraluminal thrombosis had occurred (fig. 1B). No thrombus visibly protruded into the parent vessel. Five days later, surgery was done to interpose a Dacron graft between the supraclavicular segment of the left common carotid artery and the left subclavian artery, and the stump of the proximal left common carotid artery was oversewn. The patient was discharged on the third postoperative day.

Discussion

Although about 950 aneurysms of the extracranial carotid artery have been reported in the medical literature since 1687, groups of 20 or more cases have been presented only four times [3–6]. The incidence of these lesions is, therefore, inaccurately determined, but estimates have been that they represent 0.4%–4.0% of all peripheral arterial aneurysms [3, 6]. In 1949, Kirby et al. [10] reported that at least 90% of all common carotid aneurysms were syphilitic in origin. Atherosclerosis is now the most commonly quoted etiology, and most such aneurysms are fusiform and involve the common carotid artery bifurcation region [1, 11]. Saccular carotid aneurysms most often involve the midsegment of the cervical internal carotid artery, and trauma has been reported to be the most common cause of such aneurysms [12]. The few saccular aneurysms reported to arise from the common carotid artery have been classified as secondary to atherosclerosis [13], infection [14], tumor erosion [13], trauma including angiographic needle puncture [15, 16], or an unspecified etiology [11, 14]; none of these involved the mediastinal segment.

Nonfusiform aneurysm involving the mediastinal segment of the common carotid artery has been recorded only in the form of dissection, with pseudoaneurysm formation in young individuals who had just sustained major blunt chest trauma [7–9]. Thus, the aneurysm described and illustrated in our case report appears to be unique. Of interest, the aneurysm showed internal thrombotic change in the 7 week interval between angiographic examinations, indicating an actively evolving process rather than a long-standing indolent lesion. That peculiarity only adds to the difficulty of classifying this aneurysm accurately. In the absence of any elicitable history of antecedent cause, the best recourse is to attribute it, like most cerebral aneurysms, to a developmental defect in the vascular tunic.

The relation of the aneurysm to this patient's symptoms of memory impairment and spells of "dizziness" is certainly conjectural. However, the propensity for carotid aneurysms of all sorts to act as sources of thromboemboli has been emphasized [1, 17], and this alone justifies surgery to exclude possible embolization to the cerebral circulation.

The possibility of discovering such a lesion exists only when arch aortography is included in the angiographic evaluation of cerebral ischemia. Although the likelihood of spontaneous hemorrhage from such an aneurysm is indeterminable, the

aneurysm could quite possibly have been entered and even perforated if selective left carotid catheterization had been attempted without prior arch aortography, a practice advocated by some authors [18].

ACKNOWLEDGMENT

We thank Sandra Ressler for manuscript preparation.

REFERENCES

1. Mokri B, Piepgras DG, Sundt TM, Pearson BW. Extracranial carotid artery aneurysms. *Mayo Clin Proc* 1982;57:310–321
2. Schechter DC. Cervical carotid aneurysms. Part I. *NY State J Med* 1979;79:892–901
3. McCollum CH, Wheeler WG, Noon GP, DeBaake ME. Aneurysms of the extracranial carotid artery. Twenty-one years' experience. *Am J Surg* 1979;137:196–200
4. Pratschke E, Schafer K, Reimer J, Stiegler H, Stelter WJ, Becker HM. Extracranial aneurysms of the carotid artery. *Thorac Cardiovasc Surg* 1980;28:354–358
5. Rhodes EL, Stanley JC, Hoffman GL, Cronenwett JL, Fry WJ. Aneurysms of the extracranial carotid arteries. *Arch Surg* 1976;111:339–343
6. Welling RE, Taha A, Goel T, et al. Extracranial carotid artery aneurysms. *Surgery* 1983;93:319–323
7. Koury WC, Davidson KC. Multiple chronic traumatic pseudoaneurysms of the aorta and great vessels. *Radiology* 1975;116:23–24
8. Pinkerton JA, MacGee EE, Romine KG. Traumatic aneurysm of the intrathoracic left carotid artery with cerebral embolization. *J Trauma* 1977;17:975–977
9. Colley DP, Clark RA. Acute traumatic pseudoaneurysm of the proximal left common carotid artery: a case report. *Radiology* 1980;134:431–432
10. Kirby CK, Johnson J, Donald JG. Aneurysm of the common carotid artery. *Ann Surg* 1949;130:913–920
11. Kaupp HA, Haid SP, Jurayj MN, Bergan JJ, Trippel OH. Aneurysms of the extracranial carotid artery. *Surgery* 1972;72:946–952
12. Teal JS, Bergeron T, Rumbaugh CL, Segall HD. Aneurysms of the cervical portion of the internal carotid artery associated with nonpenetrating neck trauma. *Radiology* 1972;105:353–358
13. Lane RJ, Weisman RA. Carotid artery aneurysms: an otolaryngologic perspective. *Laryngoscope* 1980;90:897–911
14. Houser OW, Baker HL. Fibromuscular dysplasia and other uncommon diseases of the cervical carotid artery: angiographic aspects. *AJR* 1968;104:201–212
15. Thompson JE, Austin DJ. Surgical management of cervical carotid aneurysms. *Arch Surg* 1957;74:80–88
16. Vitek JJ. Microaneurysms of the carotid artery after "nontraumatic" percutaneous puncture. *Radiology* 1973;106:101–104
17. Duncan AW, Rumbaugh CL, Caplan L. Cerebral embolic disease: a complication of carotid aneurysms. *Radiology* 1979;133:379–384
18. Goldstein SJ, Fried AM, Young B, Tibbs PA. Limited usefulness of aortic arch angiography in the evaluation of carotid occlusive disease. *AJNR* 1981;2:559–564, *AJR* 1982;138:103–108