



Discover Generics

Cost-Effective CT & MRI Contrast Agents



WATCH VIDEO

AJNR

Computed tomographic demonstration of choanal atresia.

R Tadmor, M Ravid, D Millet and G Leventon

AJNR Am J Neuroradiol 1984, 5 (6) 743-745

<http://www.ajnr.org/content/5/6/743>

This information is current as
of June 9, 2025.

Computed Tomographic Demonstration of Choanal Atresia

R. Tadmor¹
M. Ravid¹
D. Millet²
G. Leventon²

During a 3-year period, nine girls and two boys (age range, 2 days–13 years) with congenital choanal atresia were evaluated by computed tomography (CT). Other associated congenital anomalies, primarily craniofacial anomalies, were present in six of the 11 patients. In six patients the atresia was bilateral and consisted of both bony and membranous components. Of the five patients with unilateral atresia, the lesions were on the right in three and on the left in two. CT demonstrated the atresia, choanal stenosis, septal deviation, and thickening of the vomer and palatine bone. The ease of CT examination and the high accuracy of the results make it the preferred imaging method for evaluating choanal atresia.

Choanal atresia is a rare congenital anomaly characterized by narrowing of the posterior nasal cavity due to an obstruction at its end by an atretic plate. This plate may be bony, membranous, or both. The atresia may involve one or both nasal cavities, and other congenital anomalies may be associated with it [1–10].

If bilateral choanal atresia is present at birth, it requires immediate diagnosis and intervention to permit respiration. Unilateral choanal atresia is usually diagnosed at a later stage. The clinical diagnosis of choanal atresia is made easily when a catheter cannot be passed through the nose. However, for confirmation and further evaluation, various radiologic and other techniques have been described [1–10]. Traditionally, the conventional radiologic evaluation of this anomaly has consisted of skull radiography, tomography, and instillation of radioopaque media into the nose during fluoroscopy and radiography. The contribution of computed tomography (CT) also has been mentioned [11–13]. We report our experience in using CT studies as the sole radiologic method for evaluating congenital choanal atresia.

Materials and Methods

During a 3-year period 11 children (nine girls and two boys) with congenital choanal atresia were evaluated by CT. Their ages ranged from 2 days to 13 years. Three of the 11 patients had had corrective surgery at an early age, but since reocclusion occurred they were referred for radiologic evaluation before further treatment. Skull films were obtained in all 11 patients; instillation of contrast medium into the nasal cavities before radiography was performed in only one patient. CT scanning in all patients was performed with the Elscint-Exel scanner. Sequential axial sections of the entire nasal region were obtained using 5-mm slice thickness with 2-mm overlap. CT in the coronal plane was performed in three patients. Before the CT studies, a vasoconstricting decongestant such as ephedrine nose drops (0.5% or 1%, depending on the child's age) was administered. Particular attention was paid to suctioning out the excessive secretions in order to obtain a more accurate delineation of the anatomy and pathology.

Results

The earliest diagnosis was made in a 2-day-old infant with bilateral choanal

Received October 31, 1983; accepted after revision April 29, 1984.

Presented at the annual meeting of the American Society of Head & Neck Radiology, Boston, May 1983.

¹ Division of Neuroradiology, Chaim Sheba Medical Center, Sackler School of Medicine, Tel-Aviv University, Tel-Hashomer 52621, Israel. Address reprint requests to R. Tadmor.

² Department of Otolaryngology, Chaim Sheba Medical Center, Sackler School of Medicine, Tel-Aviv University, Tel-Hashomer 52621, Israel.

AJNR 5:743–745, November/December 1984

0195–6108/84/0506–0743

© American Roentgen Ray Society

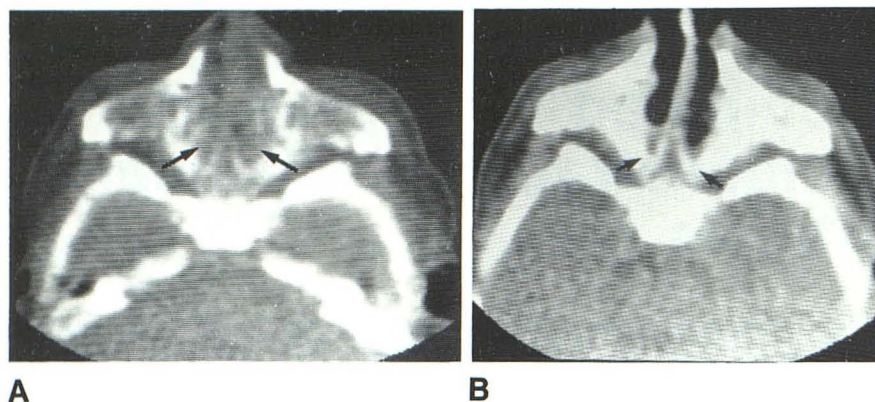


Fig. 1.—Bilateral choanal atresia in 2-day-old infant. **A**, Before suctioning. Nasal cavity is filled bilaterally with secretions (arrows). **B**, After suctioning. Bony atresia and soft-tissue component clearly shown on both sides (arrows). Note sinistral deviation of septum.

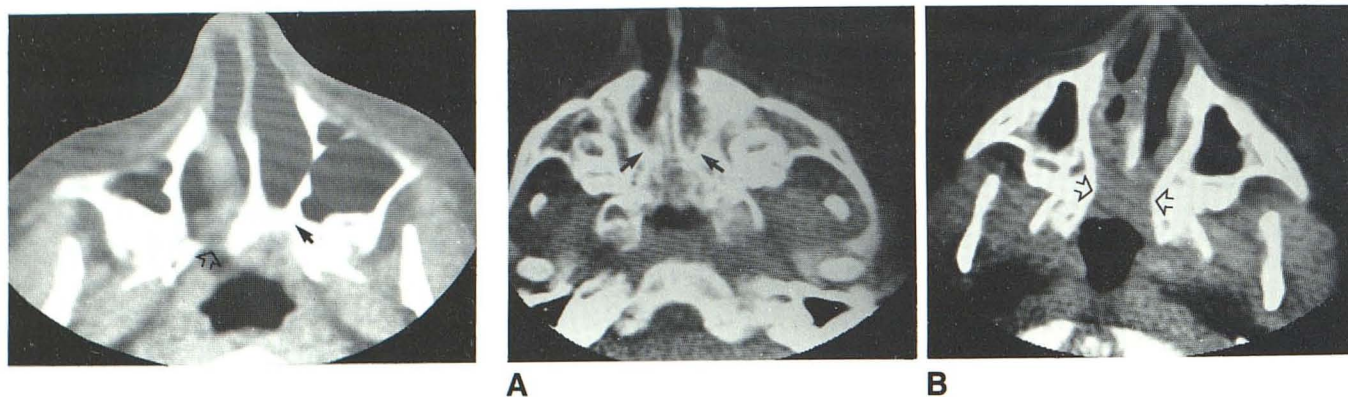


Fig. 2.—Bilateral choanal atresia in 13-year-old girl with reocclusion despite two previous operations to correct it. Stenosis of left posterior nasal cavity with thick bony plate (solid arrow); posterior narrowing and thin bony septation (open arrow) on right. Note asymmetry of face, with smaller maxillary bone on right.

Fig. 3.—Bilateral choanal atresia in 5-year-old girl with reocclusion despite corrective surgery. **A**, Thick bony atretic plates bilaterally (arrows). **B**, Adjacent CT section. Narrowing of posterior nasal cavities; thick mucosa and membranous component (open arrows).

atresia, in whom cyanosis was noted during breast feeding (fig. 1). The oldest patient was a 13-year-old girl with partial right and complete left atresia, in whom reocclusion occurred despite two previous operations to correct it (fig. 2). There were six patients with bilateral choanal atresia (figs. 3 and 4) and five with unilateral atresia, three involving the right side (fig. 5) and two the left. In all the cases of bilateral atresia, the obstruction consisted of both bony and membranous tissue (figs. 3 and 4). The septum deviated to the left in three patients and to the right in two. Other associated congenital anomalies were present in six of the 11 patients: Four had craniofacial anomalies, one had a facial hemangioma, and one had cardiac anomalies and a tracheoesophageal fistula.

Discussion

Congenital choanal atresia is an uncommon developmental defect characterized by lack of communication between the nasal cavity and the nasopharynx. This occurs embryologically around the seventh week of gestation, when either the bucconasal membrane fails to perforate or the buccopharyn-

geal membrane persists. Overgrowth of the bone at the medial vertical and horizontal palatine plate has been postulated to explain the bony component of the atresia [1–10]. Some authors suggest occurrence of congenital adhesions at the stenotic posterior choanal region as the most likely explanation for the condition [1, 2].

Choanal atresia has been estimated to occur in one of every 5000–8000 births [3, 7, 8]. There is a slight female preponderance [3–10]; however, in two reports, the female:male ratio was found to be equal [1, 2]. In our series there were nine girls and two boys. The condition is not considered to be hereditary, although there are some reports of more than one sibling of the same family being affected [3, 4].

The anomaly may be bilateral or unilateral. Clinical diagnosis of bilateral atresia is usually made when a newborn infant has respiratory distress that is relieved by crying and aggravated by nursing. The establishment of mouth breathing then becomes an emergency, while surgical correction can be planned [1–10]. Unilateral choanal atresia becomes clinically manifest at a later stage with complaints of unilateral nasal obstruction, thick mucoid nasal secretions, impaired sense of

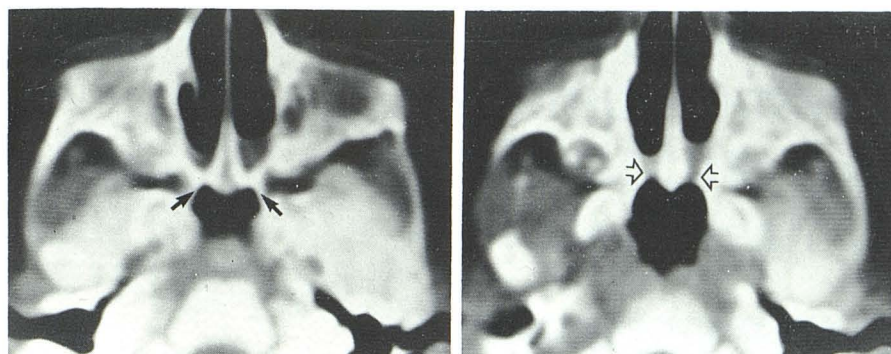

Fig. 4.—Bilateral choanal atresia in 4-month-old infant. **A**, After suctioning. Thick bony atretic component bilaterally (arrows). **B**, 5 mm lower. Membranous component (open arrows).

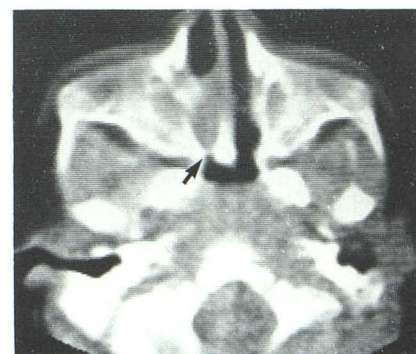

Fig. 5.—Unilateral choanal atresia in 4-month-old infant. Thin bony plate with thick membranous component on right (arrow).

smell, and repeated infections. Right-sided choanal atresia has been reported as more common than left-sided or bilateral atresia in some series [4, 7–10], whereas others claim that the incidence of unilateral and bilateral atresia is equal [1, 2] or that bilateral atresia is more frequent [5, 6]. In our series of 11 patients, six cases were bilateral; of the five unilateral cases, three were on the right.

CT in the axial plane was extremely valuable in demonstrating choanal atresia. The configuration of the nasal cavity is displayed in its entire length and it is possible to visualize stenosis and septal deviation and to differentiate between the bony and membranous components. By altering window width and center, complete and incomplete atresia can be shown as well as variations in the thickness of the bony atretic plate. CT in the coronal plane, performed in three patients in our series, failed to contribute any valuable information. There has been one report of CT in the sagittal plane to evaluate choanal atresia [13].

Septal deviation and stenosis are reported as concomitant findings in this condition [2, 3, 6, 7]. These details were well demonstrated by CT in our series. Variations in bone thickness and soft tissues also are extremely well displayed (figs. 2–5). The atresia has been reported as bony in 68%–90% of cases [3, 7, 9] and as membranous in the rest. In our series, the atresia was bony and membranous in all but one case, in which it was purely membranous. Differentiation between thickened mucosa and pure membranous occlusion may be a problem. We believe that any soft tissues visualized posteriorly on the axial CT scans after adequate suctioning and instillation of vasoconstricting nose drops should correspond to the membranous components of the atresia.

Other congenital anomalies such as craniofacial cleft palate, Treacher Collins syndrome, and cardiovascular and abdominal malformations have been reported in 20%–50% of cases of choanal atresia [4, 10]. In the series of Evans and Mclachlan [1], 28 (43%) of 65 patients had associated anomalies. Carpenter and Neel [8] reported other congenital anomalies in 6

(17%) of 36 patients. In our series, six (55%) of 11 patients had other congenital anomalies: Four had craniofacial anomalies, one had a facial hemangioma, and one had a ventricular septal defect and a tracheoesophageal fistula.

Various approaches have been advocated for surgical repair of choanal atresia: transnasal, transpalatal, transantral, or transseptal, all involving microsurgical techniques [1–9]. Currently, transnasal resection using the CO₂ laser seems very promising, even in cases of reocclusion [9].

REFERENCES

1. Evans JNG, Mclachlan RF. Choanal atresia. *J Laryngol Otol* 1971;85:903–929
2. Craig DH, Simpson NM. Posterior choanal atresia. *J Laryngol Otol* 1959;75:603–606
3. Maniglia AJ, Goodwin WJ. Congenital choanal atresia. *Otolaryngol Clin North Am* 1981;14:167–173
4. Grahne B, Kaltiokallio K. Congenital choanal atresia and its heredity. *Acta Otolaryngol (Stockh)* 1966;62:193–200
5. Singleton GT, Hardcastle B, Gainesville F. Congenital choanal atresia. *Arch Otolaryngol* 1968;87:620–625
6. Caldarelli DD, Friedberg SA. Transnasal microsurgical correction of choanal atresia. *Laryngoscope* 1977;87:2023–2030
7. Hall WJ, Watanabe T, Kenen PD, Baylin G. Transseptal repair of unilateral choanal atresia. *Arch Otolaryngol* 1982;108:659–661
8. Carpenter RJ, Neel HB. Correction of congenital choanal atresia in children and adults. *Laryngoscope* 1977;87:1304–1311
9. Healy GB, McGill T, Jako GJ, Strong MS, Vaughan CW. Management of choanal atresia with the carbon dioxide laser. *Ann Otol Rhinol Laryngol* 1978;87:658–662
10. Williams HJ. Posterior choanal atresia. *AJR* 1971;112:1–11
11. Fitz CR, Noyek AM. Contemporary radiology in congenital craniofacial disorders. *Otolaryngol Clin North Am* 1981;14:65–81
12. Osborne AG, McIlff EB. Computed tomography of the nose. *Head Neck Surg* 1982;4:182–199
13. Shirkhoda A, Biggers WP. Choanal atresia. *Radiology* 1982;142:93–94