



**Providing Choice & Value**  
Generic CT and MRI Contrast Agents

**FRESENIUS  
KABI**

**CONTACT REP**

**AJNR**

**Selecting the optimal plane for CT examination of the base of the skull.**

M S Huckman and E J Russell

*AJNR Am J Neuroradiol* 1984, 5 (3) 333-334

<http://www.ajnr.org/content/5/3/333.citation>

This information is current as  
of July 20, 2025.

# Selecting the Optimal Plane for CT Examination of the Base of the Skull

Michael S. Huckman<sup>1</sup> and Eric J. Russell<sup>1</sup>

We examined 50 computed tomographic (CT) scans that included sections through the base of the skull at a wide variety of angles. Each of these examinations had an accompanying localizing radiograph so that the angle at which the scan had been obtained could be ascertained. The scans were randomly arranged and rated as to how well 11 structures in the skull base were visualized: (1) foramen magnum, (2) foramen ovale, (3) cribriform plate, (4) vidian canal, (5) carotid-jugular septum, (6) lateral margin of the clivus, (7) hypoglossal canal, (8) pterygomaxillary space, (9) occipital condyle, (10) jugular tubercle, and sphenoccipital synchondrosis (when present).

## Results

It was noted that those scans on which the cribriform plate was best seen also demonstrated good visualization of the pterygomaxillary space on other sections obtained at the same angle. The angle of scan that produced the best visualization of the foramen magnum and its surrounding struc-

tures was also the best angle for visualizing the basal structures of the middle fossa.

Excellent visualization of the middle fossa structures and of the foramen magnum and its surrounding structures was provided by the scan plane closely approximating a line parallel to a line drawn from the posterior margin of the foramen magnum tangent to the floor of the sphenoid sinus (fig. 1). Likewise, it was determined that the cribriform plate and pterygomaxillary space were best demonstrated if the plane of the section was parallel to the planum sphenoidale (fig. 2).

## Discussion

Authors who have described techniques of examination of the skull base by CT have based their selection of angles on external landmarks [1-4]. We selected two planes that are easily identified on the lateral localizing radiograph for optimally examining most of the structures in the skull base.

In addition to selecting the proper angle, it is necessary to

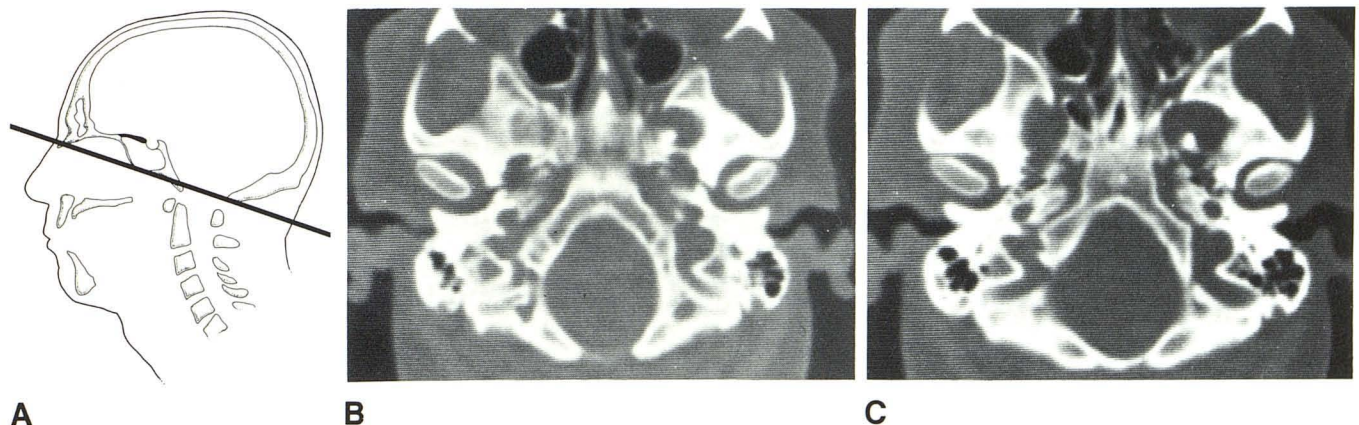


Fig. 1.—**A**, Reference plane for best visualization of basal structures of posterior and middle fossa. Planes should be parallel to line drawn from posterior edge of foramen magnum tangent to floor of sphenoid sinus. **B**, CT scan obtained using plane parallel to that in **A** reveals excellent visualization of

foramen magnum and hypoglossal, carotid, and jugular canals. **C**, Higher section shows excellent detail of lateral margin of clivus and architecture of floor of middle fossa.

Received July 7, 1983; accepted after revision September 30, 1983.

Presented in part at the annual meeting of the American Society of Neuroradiology, San Francisco, June 1983.

<sup>1</sup> Department of Diagnostic Radiology, Rush-Presbyterian-St. Luke's Medical Center, Chicago, IL 60612. Address reprint requests to M. S. Huckman.

AJNR 5:333-334, May/June 1984 0195-6108/84/0503-0333 \$00.00 © American Roentgen Ray Society

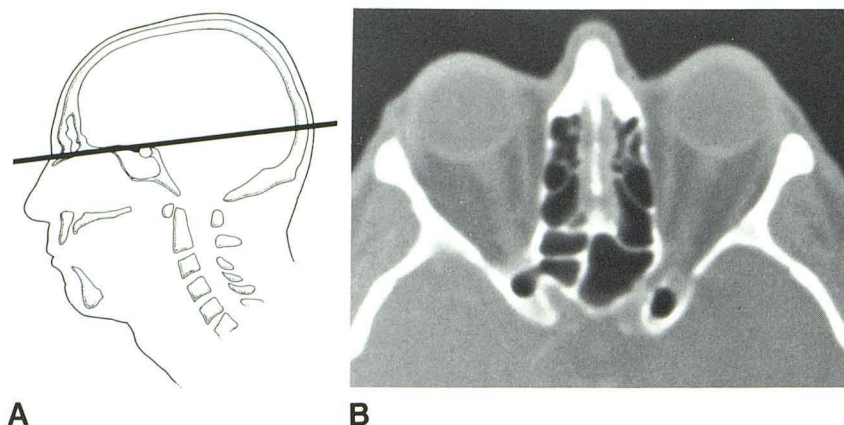


Fig. 2.—A, Optimal angle of plane for visualization of cribriform plate and pterygomaxillary space. B, CT scan obtained using this reference line demonstrates visualization of soft tissue just above cribriform plate with ethmoid air cells lying just lateral to cribriform area.

view scans with wide window widths and high-resolution bone-detail programs when available. While thin sections (1.5–2 mm) are often desirable, they may result in visualization of one side of a foramen in a particular section and the opposite side in a different section. For this reason thicker sections (4 mm) with small (1–2 mm) section overlap may be necessary. While small variations away from the optimal angle will not greatly degrade the image, wide swings will cause such artifacts as shortening of the middle fossa.

Direct coronal examination may be more advantageous for examining the skull base. However, such examinations are often degraded by artifacts from fillings in the teeth, and some patients are unable to sufficiently extend the neck to allow scanning in the direct coronal projection. Accordingly, for this reason the planes outlined above are recommended as alternatives when foreign-body artifact and limited neck extension prevent direct coronal examination of the base of the skull.

For optimizing the examination of the base of the skull by CT, the angle of scan should be determined on the lateral

localizing film. For visualization of the foramen magnum; carotid, jugular, and hypoglossal canals; jugular tubercle; occipital condyle; lateral margins of the clivus; and foramina of the middle fossa, the plane should be parallel to a line drawn from the posterior margin of the foramen magnum tangent to the floor of the sphenoid sinus. For examination of the cribriform plate and pterygomaxillary space, the optimal plane should be parallel to the planum sphenoidale.

#### REFERENCES

1. Nakagawa H, Wolf BS. Delineation of lesions of the base of the skull by computed tomography. *Radiology* **1977**;124:75–80
2. Hammerschlag SB, Wolpert S, Carter BL. Computed tomography of the skull base. *J Comput Assist Tomogr* **1977**;1:75–80
3. Bradac GB, Schramm J, Grumme T, Simon RS. CT of the base of the skull. *Neuroradiology* **1978**;17:1–5
4. Becker H, Grau H, Hacker H, Ploder K. The base of the skull: a comparison of computed and conventional tomography. *J Comput Assist Tomogr* **1978**;2:113–118