



## Discover Generics

Cost-Effective CT & MRI Contrast Agents

 FRESENIUS  
KABI

[WATCH VIDEO](#)

# AJNR

## Computed Tomography of the Sacral Plexus and Sciatic Nerve in the Greater Sciatic Foramen

Charles F. Lanzieri and Sadek K. Hilal

*AJNR Am J Neuroradiol* 1984, 5 (3) 315-318

<http://www.ajnr.org/content/5/3/315>

This information is current as  
of June 25, 2025.

# Computed Tomography of the Sacral Plexus and Sciatic Nerve in the Greater Sciatic Foramen

Charles F. Lanzieri<sup>1</sup>  
Sadek K. Hilal<sup>2</sup>

The sacral plexus forms the sciatic nerve, which leaves the pelvis through the greater sciatic foramen. The anatomic boundaries of the greater sciatic foramen and the relation of the sacral plexus and sciatic nerve to the structures within are identified and described on axial computed tomography (CT). The piriform muscle, which passes through the center of the greater sciatic foramen, is a recognizable landmark that is extremely helpful in locating the sacral plexus and sciatic nerve on CT. The pelvic CT images of 25 patients studied for unrelated reasons and two patients studied for complaints related to the greater sciatic foramen were reviewed. CT was very useful in demonstrating the anatomy of this region and for the investigation of sciatic pain due to lesions outside the neural canal.

Neurologic symptoms referable to the sacral nerve roots may be due to intradural, extradural, or sacral processes. Diseases affecting the soft tissues in the parasacral spaces, in particular the greater sciatic foramen, may result in similar neurologic symptoms without causing myelographic or plain-film changes. The anatomy of this region can be reliably evaluated by axial computed tomography (CT).

The CT anatomy of the pelvis, sacrum, and adjacent soft tissues has been described in both normal and pathologic states [1-3]. Also, the role of CT in the evaluation of patients with complaints referable to the sacral nerves has been pointed out [4, 5]. But the detailed CT anatomy of the parasacral spaces as they relate to the sacral plexus and sciatic nerve has not been described fully. That is the subject of this report. The clinical relevance of these details in patients with complaints referable to the sacral plexus or sciatic nerve is also developed.

## Materials and Methods

We reviewed pelvic CT images of 25 patients studied for various reasons unrelated to the structures in the greater sciatic foramen. All the studies were performed in the axial plane on the Pfizer 0450 CT scanner. The slice thickness varied from 4 to 8 mm. Two patients with pain and/or neurologic or electromyographic findings referable to the sacral plexus or sciatic nerve known to have neurofibromatosis were also studied. All of the patients received intravenous contrast material. Plain films of the pelvis were unremarkable in all cases.

## Anatomy

The greater sciatic foramen is an oval space in the posterolateral aspect of the pelvis bordered by the ilium superiorly, the ischium anteriorly, the sacrum posteriorly, and the sacrospinous ligament inferiorly (fig. 1). The posterior border of the innominate bone below the sacroiliac articulation and above the ischial tuberosity curves sharply anteriorly and follows a long sweeping curve inferiorly, interrupted by the ischial spine just before its inferior termination [1, 6]. Two indentations are thus formed: the greater sciatic notch, which begins at the junction of the sacrum with the ilium and ends at the ischial spine; and the lesser sciatic notch, which is much smaller and is just below the ischial spine. The greater sciatic

This article appears in the May/June 1984 issue of *AJNR* and the July 1984 issue of *AJR*.

Received August 3, 1983; accepted after revision October 7, 1983.

<sup>1</sup> Department of Radiology, School of Medicine of the City University of New York, and Mount Sinai Medical Center, 1 Gustave L. Levy Pl., New York, NY 10029. Address reprint requests to C. F. Lanzieri.

<sup>2</sup> Department of Radiology, Columbia-Presbyterian Medical Center, New York, NY 10032.

*AJNR* 5:315-318, May/June 1984  
0195-6108/84/0503-0315 \$00.00  
© American Roentgen Ray Society



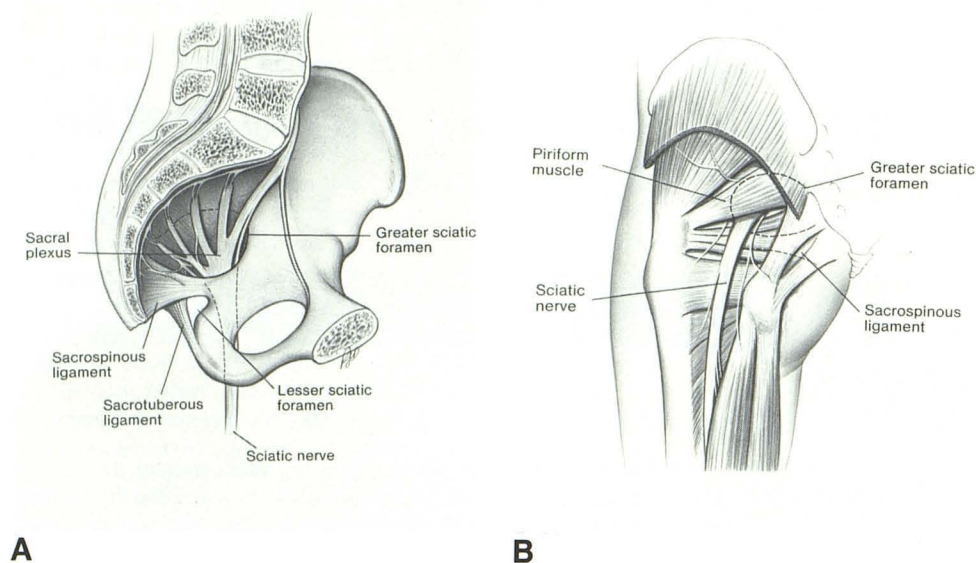


Fig. 1.—Normal anatomy. Medial (A) and posterior (B) views of pelvis with borders of greater sciatic foramen indicated by broken lines. Sciatic nerve exits pelvis by passing through anterior inferior quadrant of greater sciatic foramen.

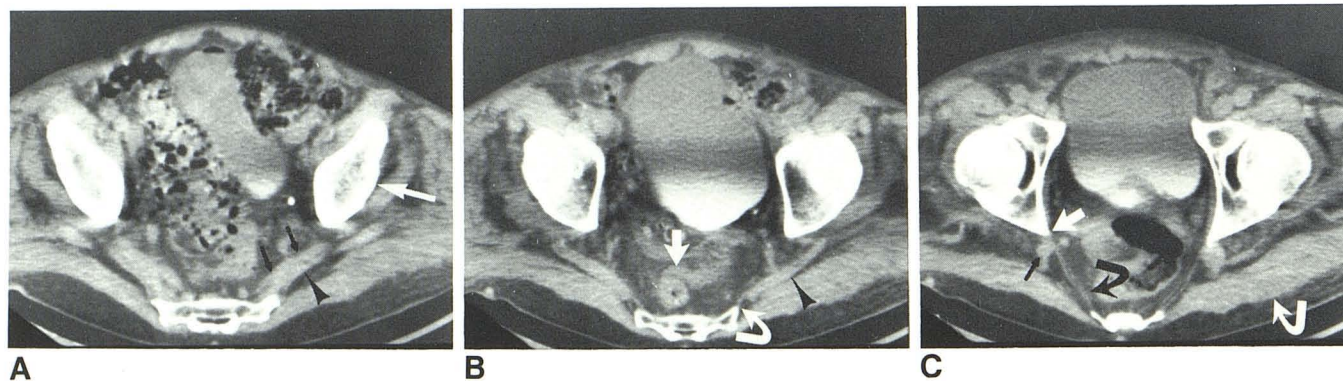


Fig. 2.—Normal greater sciatic foramen, axial images. A, Upper part of greater sciatic foramen shows medial part of the piriform muscle (arrowhead), sacral plexus (black arrows), and ilium (white arrow). B, Lower contiguous cut shows piriform muscle passing through greater sciatic foramen (arrowhead), from its origin on inferior lateral angle of sacrum (curved arrow). Presacral

space contains air-filled rectum (straight arrow). C, Next lower contiguous cut is through lower part of greater sciatic foramen and demonstrates sacrospinous ligament (curved black arrow) and sciatic nerve (straight black arrow). Anterior insertion of sacrospinous ligament on ischial spine can be seen (straight white arrow). Gluteal group of muscles is indicated (curved white arrow).

notch forms the superior and anterior borders of the greater sciatic foramen, whose other borders are the sacrum posteriorly and the sacrospinous ligament inferiorly. The latter is a broad, flat ligament that has a wide origin from the inferolateral aspect of the sacrum and a wide insertion on the ischial spine. The ligament also forms the upper border of the lesser sciatic foramen, whose other boundaries are the lesser sciatic notch and the sacrotuberous ligament. This ligament has an origin similar to the sacrospinous ligament but inserts on the ischial tuberosity.

The greater sciatic foramen transmits several important structures. The piriform muscle originates on the ventral surface of the sacrum and passes through the center of the foramen in a medial to lateral direction to insert on the greater trochanter. The sacral plexus is a triangular structure that rests on the anterior surface of the belly of the piriform muscle. It receives contributions from the ventral sacral nerves exiting the anterior foramina of the sacrum and from the lumbosacral trunk descending from the lumbar plexus. From its

inferiorly directed apex the sciatic nerve traverses the foramen, crossing the anterior third of the foramen on the anterior surface of the piriform perpendicular to that muscle's long axis, and passing just posterior to the sacrospinous ligament at its insertion on the ischial spine. The gluteal artery and vein and superior gluteal nerve also exit the pelvis via the greater sciatic foramen. They pass through the upper part just above the piriform. The internal pudendal nerve and vessels and nerves to the internal obturator muscle and quadratus muscle of the thigh pass through the foramen just anterior to the piriform.

#### CT Observations

The piriform muscle was demonstrated in all cases and served as a useful landmark in identifying the other structures in the greater sciatic foramen. The entire extent of the greater



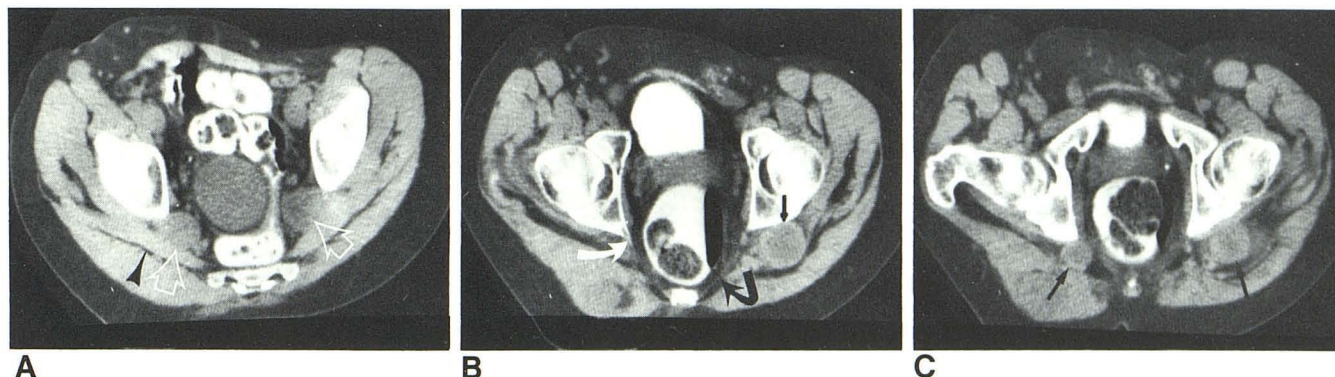


Fig. 3.—Neurofibromatosis. **A**, Large neurofibromata are seen bilaterally involving sacral plexus (open arrows). These are on anterior surface of piriform muscles (arrowhead). **B**, Lower cut shows sacrospinous ligament (curved black

arrow) and its anterior insertion on ischial spine (white arrow). Large neurofibroma is seen involving upper sciatic nerve (straight black arrow). **C**, Lower level. Bilateral sciatic nerve neurofibromata (arrows).

sciatic foramen including its inferior boundary, the sacrospinous ligament, was imaged in 20 normals. The region of the sacral plexus and sciatic nerve and/or the nerve itself could be seen in all cases in which the piriform muscle and sacrospinous ligament were visualized. The greater sciatic foramen is identified on axial images of the pelvis just inferior to the sacroiliac articulation. The posterior border is formed by the lateral margin of the sacrum; the anterior border by that part of the ilium and ischium above the ischial spine. The course of the sacral plexus and sciatic nerve within the greater sciatic foramen is easily understood by dividing the greater sciatic foramen into a superior part containing the piriform muscle (figs. 2A and 2B) and an inferior part containing the sacrospinous ligament (fig. 2C).

The piriform muscle is the largest structure that passes through the greater sciatic foramen and serves as an easily identifiable and useful landmark for the superior greater sciatic foramen. The medial one-third of the piriform muscle is usually seen on a single axial section (fig. 2A). The lateral part of the muscle can be seen passing through the greater sciatic foramen to insert on the greater trochanter of the femur on the next lower contiguous cut (fig. 2B).

Distinct fascial planes separate the piriform muscle from the gluteal group of muscles posteriorly and from the retroperitoneal structures anteriorly (figs. 2A and 2B). Identification of these fascial planes is important when searching for parasacral and retroperitoneal pathology. The sacral plexus lies in the fascial plane anterior to the piriform muscle. Individual components of the sacral plexus cannot be identified in the normal subject; however, an oval density adjacent to the anterior surface of the piriform was seen in 11 of the 20 patients in whom the entire greater sciatic foramen was demonstrated (fig. 2A). This structure is presumed to represent the sacral plexus. Measurement of the longest diameter of the structure in a plane perpendicular to the axis of the piriform muscle in 11 patients varied from 0.7 to 1.3 cm. Inability to differentiate the sacral plexus from the piriform muscle was usually because the fat plane between these two structures was not prominent. The fascial plane anterior to the piriform muscle communicates with the presacral space and thus with the opposite side. Unlike the anterior fascial

plane, the fascial plane posterior to the piriform does not cross the midline and ends medially at the lateral border of the sacrum.

Axial sections through the inferior part of the greater sciatic foramen include the sacrospinous ligament but not the piriform muscle. This structure appears as a thin line running in an oblique direction from the anterior lateral border of the sacrum to the ischial spine and is a reliable landmark for the inferior part of the greater sciatic foramen (fig. 2C). It is much more gracile and linear than the piriform and forms the lower margin of the greater sciatic foramen rather than passing through it. The two structures are, therefore, easily distinguished in most cases. At this level the sciatic nerve could be identified as a roughly circular structure lateral to the anterior insertion of the sacrospinous ligament and posterior to the ischial spine in 16 (80%) of the 20 patients in whom the entire greater sciatic foramen was demonstrated (fig. 2C). In leaving the pelvis the sciatic nerve passes ventrad to the belly of the piriform and directly behind the sacrospinous ligament. In doing so it traverses the slitlike opening between these two structures. Measurement of the diameter of the sciatic nerve was made as close to the insertion of the sacrospinous ligament on the ischial spine as possible in these 16 patients. The largest diameter of the sciatic nerve at this level was 0.9–1.2 cm. In four patients, the sciatic nerve could not be identified definitely despite adequate cuts through the greater sciatic foramen. This was because of superimposition of adjacent contiguous soft-tissue structures, for example, blood vessels or lymph nodes.

Like the piriform, the sacrospinous ligament is surrounded anteriorly and posteriorly by prominent fascial planes. The space anterior to the ligament is the same space that contains the sacral plexus more superiorly. The space posterior to the ligament containing the sciatic nerve is limited medially by the sacrum. Recognition of the integrity of the fascial planes in the region of the greater sciatic foramen is important. Obliteration of these planes may be caused by inflammation, neoplasm, or hematoma.

Patients with extensive neurofibromatosis may have symptomatic involvement of the sacral plexus or sciatic nerve. Examples of each of these serve to emphasize the anatomic



relations already described. Tumors of the sacral plexus will be identified within the fascial plane anterior to the piriform muscle in the superior part of the greater sciatic foramen (fig. 3A). Tumors of the sciatic nerve will be located in the fascial plane posterior to the sacrospinous ligament in the inferior part of the greater sciatic foramen (figs. 3B and 3C).

### Discussion

The relation of the sacral plexus and sciatic nerve to each other and to surrounding structures can be understood easily by dividing the greater sciatic foramen into a superior part containing the piriform muscle and the sacral plexus, and an inferior part containing the sacrospinous ligament and upper sciatic nerve. The piriform muscle and the sacrospinous ligament are reliable landmarks for identifying the superior and inferior parts of the greater sciatic foramen. The sciatic nerve can be reliably identified and measured when the entire greater sciatic foramen is demonstrated in high-resolution axial CT images. Sufficient fat within the greater sciatic foramen does not appear to hinder identification and measurement of the sciatic nerve; however, in some cases it is not possible to differentiate the sciatic nerve from adjacent blood vessels or lymph nodes. Definite identification and measurement of the sacral plexus is somewhat less reliable, largely because of difficulty in differentiating the sacral plexus from the piriform muscle.

Lesions of the sacrum are known to produce complaints

referred to the sacral nerves and sacral plexus. These processes have specific radiographic and CT manifestations [3–5]. Lesions of the sacral plexus or sciatic nerve may not affect the sacrum, and particular attention must be paid to the fascial planes and soft tissues surrounding the sacral plexus and sciatic nerve. Unsuspected abnormalities of the soft tissues surrounding the sacrum will not be evident on plain films or myelography. Lesions of the sacral plexus and sciatic nerve as they traverse the greater sciatic foramen are easily evaluated with CT. Further study of pathologic processes within the greater sciatic foramen is required to determine to what extent regional lymph-node enlargement and other pathologic entities may involve the sacral plexus and sciatic nerve.

### REFERENCES

1. Lee JKT, Sagel SS, eds. *Computed body tomography*. New York: Raven, **1983**
2. Whelan MA, Gold RP. Computed tomography of the sacrum: 1. Normal anatomy. *AJNR* **1982**;3:547–554, *AJR* **1982**;139:1183–1190
3. Whelan MA, Hilal SK, Gold RP, Luken MG, Michelson WJ. Computed tomography of the sacrum: 2. Pathology. *AJNR* **1982**;3:555–559, *AJR* **1982**;139:1191–1195
4. Federle MP, Moss AA, Margolin FR. Role of computed tomography in patients with sciatica. *J Comput Assist Tomogr* **1980**;4:335–341
5. Chiapetta P. CT evaluation of sacral tumors with neural involvement. *J Neurosurg Sci* **1981**;25:89–94
6. Spalteholz W. *Atlas of anatomy*. Philadelphia: Davis, **1961**