

Generic Contrast Agents

Our portfolio is growing to serve you better. Now you have a *choice*.



[VIEW CATALOG](#)

AJNR

This information is current as of May 30, 2025.

Subacute Stent Deformities as an Underlying Reason for Vessel Stenosis after Flow Diversion with the p64 Stent: Review and Discussion of Biologic Mechanisms and Consequences

G. Vladev, A. Sirakov, S. Matanov, K. Sirakova, K. Ninov and S. Sirakov

AJNR Am J Neuroradiol 2025, 46 (4) 712-719

doi: <https://doi.org/10.3174/ajnr.A8564>

<http://www.ajnr.org/content/46/4/712>

Subacute Stent Deformities as an Underlying Reason for Vessel Stenosis after Flow Diversion with the p64 Stent: Review and Discussion of Biologic Mechanisms and Consequences

G. Vladev,  A. Sirakov,  S. Matanov,  K. Sirakova,  K. Ninov, and  S. Sirakov



ABSTRACT

BACKGROUND AND PURPOSE: Flow-diverter stents are a potent and efficient tool in the instrumentarium of neurointerventional radiologists for the treatment of intracranial aneurysms. With their implementation, some adverse effects and complications such as hemorrhagic and ischemic ones, have been seen as a potential downfall of the method. In-stent stenosis is one such complication, which until now has not received enormous attention due to its seemingly benign characteristic. In our study we propose a different point of view on this matter and aim to establish a potential mechanism for its development: a subacute postprocedural stent deformation, due to segmental vessel constriction as a reaction to the implant.

MATERIALS AND METHODS: We enrolled 48 patients between the ages of 31 and 71 (8 men) with aneurysms on the distal portions of the ICA, all of whom were treated with the p64 flow-diverter stent, to assess the incidence of this phenomenon, as well as establish a correlation between it and subsequent clinical symptoms. A protocol for short-term follow-up, consisting only of a high-dose fluoroscopy image of the implant (conducted on the 14th postprocedural day) was implemented to assess the state of the implant before endothelialization was to be expected.

RESULTS: Stent deformities were seen in 58% of cases. One patient with an observed stent deformity presented with several episodes of acute contralateral 1-sided weakness of the limbs. Seventy-one percent of those patients presented with a mild/moderate unilateral headache postprocedurally. A correlation between the deformity and a subsequent narrowing of the parent vessel diameter was established on follow-ups. Notable in-stent stenosis was reported in 35% of all cases.

CONCLUSIONS: Cases with subacute stent deformities are presented in a nonnegligible percent of flow-diversion therapies with the p64 stent. A statistically significant association between the observed deformation and subsequent in-stent stenosis was observed on follow-up.

ABBREVIATIONS: ASA = acetylsalicylic acid; DAPT = dual antiplatelet therapy; EC = endothelial cell; eNOS = endothelial nitrous oxide synthase; FD = flow-diverter; ISS = in-stent stenosis; NO = nitrous oxide; VSMC = vascular smooth-muscle cells; WSS = wall shear stress; WSSG = wall shear stress gradient


Since the early 2010s, flow diversion emerged as a novel mainstream and intriguing way to treat cerebral aneurysms.¹ It gave the endovascular field a way to treat complex, large-neck aneurysms, that had been previously deemed untreatable by the conventional coil embolization or assisted coiling techniques.² The initial concept of flow-diverter (FD) stent function was that they would promote thrombus formation in the aneurysmal sac,³ through induced turbulent flow in the aneurysm, with gradual obliteration through time. This was achieved by decreasing the

porosity of the devices, as opposed to their previously introduced high-porosity counterpart stents, used for assisted coiling.⁴ To achieve these results, a stent would have to exhibit lower than 70% porosity, or in other words 30% metal coverage across the aneurysm neck, to have a meaningful impact on the intra-aneurysmal flow.⁵ Later studies showed another vital mechanism that was coined as biologic reconstruction of the vessel wall through way of stent strut endothelialization due to cell neoproliferation.⁶ After FD implantation, both thrombus formation and integration of the stent in the vessel wall would lead to curing of the vascular pathology by sealing the aneurysm.⁷ The inherent thrombogenicity of the metal of the device yields a need for a dual antiplatelet therapy (DAPT) regimen being implemented until endothelial coverage is achieved, as to avoid acute thromboembolic complications intraprocedurally and in the early postoperative period.⁸ DAPT usually consists of a P2Y₁₂ inhibitor and an inhibitor of thromboxane A₂ production, with both having antithrombotic

Received June 12, 2024; accepted after revision September 29.

From the Radiology Department (G.V., A.S., S.M., S.S.), and Neurosurgery Department (K.N.), UH St Ivan Rilski, Sofia, Bulgaria; and Radiology Department (K.S., G.V., A.S., S.S.), Medical University of Sofia, Bulgaria.

Please address correspondence to Stanimir Sirakov, MD, PhD, UH St. Ivan Rilski, Radiology, Bul. Akad. Ivan Geshov 15, Sofia, 1431, Bulgaria; e-mail: ssirakov@bsuniv.org

 Indicates open access to non-subscribers at www.ajnr.org

<http://dx.doi.org/10.3174/ajnr.A8564>

SUMMARY

PREVIOUS LITERATURE: Prior studies, revolved around in-stent stenosis after flow-diversion have depicted the phenomenon as mostly asymptomatic and have labeled several factors, which could be used to predict its occurrence.

KEY FINDINGS: This study evaluated patients treated with flow-diverter stents for cerebral aneurysms and found that specific post-procedural subacute changes in the stent structure are strongly associated with the formation of in-stent stenosis.

KNOWLEDGE ADVANCEMENT: The study adds to the body of literature on ISS and gives insight on a potential pathological mechanism, which may be responsible for its development.

functions through different pathways.⁹ Complete endothelialization of the stent in animal models is shown to happen at around 28 days,¹⁰ but DAPT is usually continued until the first control DSA is performed to avoid potential complications. The first follow-up is performed at the 6-month mark, because it is assumed that partial or complete obliteration of the aneurysm cannot be adequately observed before that and a follow-up would be redundant in a shorter time-span.¹¹ DAPT is discontinued at the discretion of the treating physician before scheduling a second control DSA at a later date. Newer generation FD stents using coating materials intend to avoid the need for DAPT and avoid the risk of hemorrhagic complications,¹² however, more data are needed to assess their safety and efficacy properly.

In-Stent Stenosis

The most common complications linked with FD stent usage are ischemic events intra- or postprocedurally. DAPT remedies the acute thromboembolic complications by way of negating thrombus formation at the site of the stent implantation. Another phenomenon that could cause ischemia or remain asymptomatic is the in-stent stenosis (ISS) that could occur at the site of stent (whether it is an FD or a non-FD) implantation.¹³ The term is used to describe the segmental narrowing of the vessel lumen in which the FD was placed, on the performed control DSAs or MR imaging. On large follow-up studies, ISS was shown to have an incidence between 10% and 50% of cases, with a small number being symptomatic.¹⁴⁻¹⁶ It is most commonly observed at mid-term follow-ups and has a uneventful clinical course,¹⁷ because on later follow-up angiograms it could potentially resolve itself.¹⁸ The underlying pathologic mechanisms are still not clear. Vessel factors that contribute to the formation of ISS are thrombus formation along the struts of the stent, endothelial cell (EC) hyperplasia, and smooth muscle cell proliferation.^{19,20} There is a lack of a unified quantifiable way to determine the presence of ISS and so the true incidence can be considered unknown.

The Possible Interaction Between the Stent and the Artery

The innate characteristics of FD stents would inadvertently cause biomechanical changes in the vessel in which they are placed. The arterial wall is not an inanimate object or simply an elastic tube that would ignore the outside forces being applied to it.²¹ The wall has highly reactive components that play a key role in maintaining homeostasis in physiologic conditions and even more so when concerning the autoregulatory mechanism of the cerebral circulation.²² Both pressure-dependent stretch from intraluminal

pressure and shear stress from the flow of blood mediate different cellular pathways that have a role in keeping the wall vessel structure in a steady state under normal conditions. Changes in stretch or shear forces impact cellular mechanisms with vessel remodeling taking place to adapt to the new conditions.

The endothelial layer acts as a first-line responder to the changes of intravascular blood-flow. Higher levels of wall shear stress (WSS) induce several alterations in the cells themselves. First, ECs have the capability for morphologic changes under the effects of laminar flow, because they orient themselves longitudinally parallel to it.²³ The cell membrane, intracellular components, and the extracellular matrix themselves act as mechanotransducer entities, which react to changes in stress. It has been shown that integrins, other cellular matrix proteins like vinculin, talin, and actin, stretch-activated ion channels, and tyrosine-phosphorylated proteins act in the signal transduction cascade.²⁴⁻²⁸ Furthermore, higher pressure-induced strain causes a higher sensitivity of ECs to shear stress.²⁹ An important factor of vasodilation is the production of nitrous oxide (NO) by the endothelial nitrous oxide synthase (eNOS).³⁰ eNOS has different activation pathways, both calcium dependent or independent. Its role is not solely isolated to the regulation of muscle tone. NO plays an important role in different pathways associated with the occurrence of thrombosis, cell proliferation, and cellular adhesion molecules expression.³¹ The effects of NO production dysfunction are well studied and proved as a crucial characteristic of endothelial dysfunction.³² The prostaglandin I₂ also acts as a potent vasodilator when released from the cell after stress-induced activation.³³

Vascular smooth-muscle cells (VSMCs) react specifically to stretch-induced stress, as opposed to endothelial cells that react to both stretch and shear stress. Stretching of the muscle layer activates biochemical changes in the cells aimed toward hypertrophy and proliferation. G protein-coupled receptors, receptor tyrosine kinases, lectinlike oxidized low-density lipoprotein receptor-1, and other receptors are all linked to stress activation of VSMCs.³⁴ Calcium ions influx is needed for the activation of myosin light-chain kinase.³⁵ The mechanical stress induced in VSMCs also activates mitogen-activated protein kinases through signal transduction.³⁶ These specific pathways, as well as growth factor derived from ECs contribute to the vessel remodeling in response to mechanical stress.³⁷

FD stents have several effects, apart from aneurysm occlusion, on the vessel wall after their implantation. First, the mechanical properties of the stent lead to an induced circumferential stress on the vessel.³⁸ The effect is often exaggerated by the fact that

Table 1: Demographic characteristics

Characteristics	n=48
Age (years)	31–71 (mean = 51.4 SD = 11,938)
Female	40 (83%)
Stent deformities in N of observed patients	28 (58%)
Distal half stent deformities	26 (54%)
Proximal half stent deformities	2 (4%)
Proximal marker changes	18 (38%)
Patients exhibiting clinically Notable symptoms	1 (2%)
Aneurysms on the ophthalmic segment	34 (71%)
Aneurysms on the terminal segment	14 (29%)
Smoking	18 (38%)
Hypertension	22 (46%)

clinicians aim at stent oversizing, to achieve better wall apposition. In addition to that, stent placement is also linked with significant changes in WSS, which creates a large wall shear stress gradient (WSSG) within the areas, covered by the struts of the stent.³⁹ Another feature that is impacted is the innate elastic recoil of the vessel. Along with intimal proliferation and wall remodeling, it is a driving factor in vessel healing after stent implantation.⁴⁰ These intraluminal devices are a cause of EC damage and initiation of inflammatory cascades that take place in the segment they are placed in.⁴¹ All of these factors lead to acute vessel wall dysfunction and ultimately can potentially lead to ISS.

Subacute Stent Deformity

A perhaps less explored side of ISS is the postdeployment subacute stent deformities that occur in the stent structure, due to impeded local autoregulation and vessel reaction. As was already established, the natural homeostasis of the stented segment of the vessel is violated, and so vasodilator and vasoconstrictor factors find themselves at an imbalance, because the former have been impeded. A study from 2019 conducted by Schob et al⁴² showed the implication of this mechanism and its potential role in ISS. Before our literature review on the matter, we noted that some of our patients presented with ISS that was associated with postdeployment stent deformities, seen at the midterm control angiogram, without actual intimal hyperplasia being observed. We hypothesize that before the actual structural changes in the wall take place, the vessel reacts to the implant with constriction, as opposed to the mechanical strain being applied to it. In our cases, we show the most common type of deformity, which is a distal narrowing of the stent, as it is being “squeezed” by the carotid artery in an effort to control the pressure that is exerted by the implant.

MATERIALS AND METHODS

Data Collection and Study Design

The Strengthening of the Reporting of Observational Studies in Epidemiology guidelines were followed to collect and report data.⁴³

We devised a follow-up protocol after treatment to observe the true incidence of subacute stent deformities, based on a time period when we would not expect endothelial stent coverage to have already taken place. A simple fluoroscopy image of the stent, without the invasive nature of a complete DSA, would yield satisfactory results in assessing the deformities. The first single-shot image was done intraprocedurally to assess the complete apposition of the stent. The second single-shot image would be

conducted on the 14th postprocedural day. A total of 48 patients (Table 1) underwent this follow-up protocol in our clinic from the period of March 2023 to May 2023 (Fig 1). All patients (40 women and 8 men) between the ages of 31 and 71 (mean = 51.4, standard deviation = 11,938), were enrolled, with a total of 48 aneurysms being treated. We selected a homogeneous group of patients who underwent stent placement of ophthalmic and/or posterior communicating artery aneurysms,

which required a stent to be placed along the distal portion of the ICA and in some cases the MCA.

All procedures were done under general anesthesia and our vascular access was the right femoral artery in all cases. All patients received DAPT for 5 days before the procedure, consisting of 10 mg prasugrel and 100 mg acetylsalicylic acid (ASA) daily. A 6F sheath was introduced into the femoral artery, and then a guiding catheter was placed in the proximal part of the carotid artery, on which the aneurysm was situated. In all cases the p64 FD stent (phenox) was used. The choice of the device size was done by measuring the diameter of the vessel segment in which the proximal landing zone would be and oversizing it by 0.5 mm. The goal was to achieve optimal stent apposition, with adequate aneurysm neck coverage, to fully obliterate the aneurysm with time. No technical complications, linked to the device, such as migration of deformation during the deployment, in any case was noted. No immediate postprocedural complications were observed. Patients were discharged from the hospital within 4 days from the procedure. They were scheduled for a fluoroscopy image on the 14th postprocedural day and a control DSA at 6 months.

All patients underwent a clinical examination by a member of the department team and a neurologist at each follow-up (14th day and at the 6-month mark). Any and all newly found clinical symptoms were taken into account and registered. Symptoms were divided into minor (a concomitant unilateral headache, which was not pre-existing before the procedure) and major or severe (eg, contralateral motor deficit or aphasia).

Evaluation of the images to determine whether a stent deformity was present was done by 2 members of our team separately, with mutual agreement being needed to classify them. Cases of disagreement were resolved by third-party adjudication. Measurements of the vasculature and implants pre- and postprocedurally were done by a single physician.

Stent deformities were divided into minor (discrete changes in the radiopaque structure of the stent with <50% loss of the initial implant diameter) and major (pronounced narrowing with >50% loss of the original implant diameter). The measurements were made at each performed short- and mid-term follow-up.

We labeled ISS as any filling defect of the vessel located between the stent and the observable contrasted parent artery lumen, measured on the unsubtracted angiographies. ISS at the 6-month follow-up was classified into 3 categories based on the angiographic appearance and measurements: mild (<25%), moderate (25%–50%), and severe (>50%).

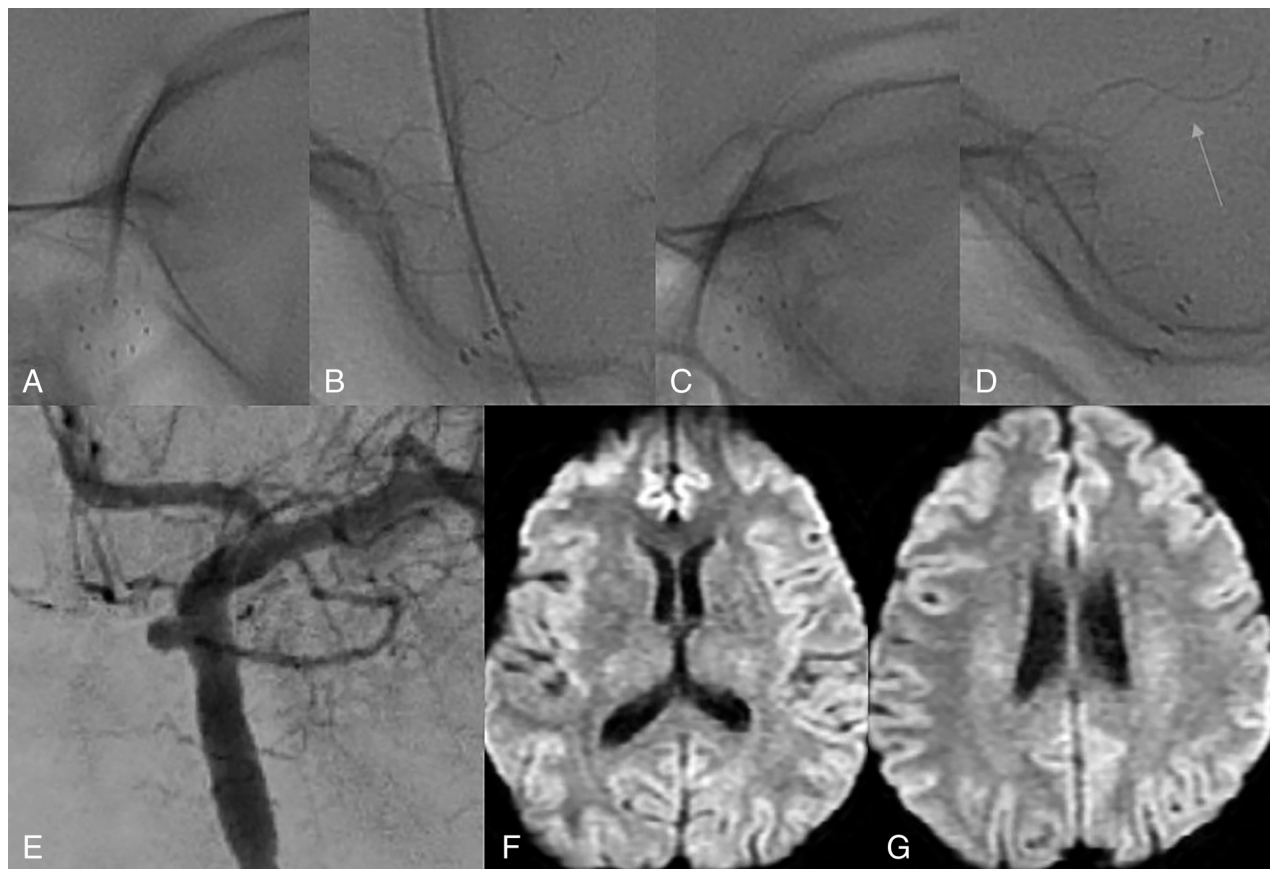

FIG 1. A and B, antero-posterior (AP) and lateral projections of a single-shot image of the stent on discharge. No deformity was observed. C and D, Single-shot images of the stent 14 days after the procedure, after the onset of symptoms. A noticeable narrowing and elongation of the distal part of the stent can be seen (orange arrow). This observation is concurrent with our observation of the carotid artery's reaction to the implant. Because this case is the one in which our patient exhibited acute symptoms from the occurrence, we believe it is extremely illustrative for our point to come across. E, AP projection of the intraprocedural DSA performed prior to the implantation of the FD stent. A saccular aneurysm of the ophthalmic segment of the left ICA was the target of treatment. F and G, DWI MRI sequence, which was performed after the initial onset of right-sided weakness with which the patient presented. No acute ischemic changes in the brain parenchyma can be seen, which led us to believe that the changes in the cerebral blood flow were transient in nature.

The collected data were analyzed by using SPSS (Statistical Package for the Social Sciences) Version 29.0. The statistical methods applied to the study were: descriptive statistics, Fisher exact test, and Spearman rank correlation. Kolmogorov-Smirnov and Shapiro-Wilk tests were used to test the normal distribution of the data. The level of accepted significance was noted as $\alpha = 0.05$, defined as $P < .05$.

RESULTS

Of all the patients ($n = 48$), 47 underwent follow-up through DSA at the 6-month mark. One patient underwent an MRI and a subsequent adjunctive single-shot image of the implant as a 6-month follow-up.

Stent deformities on the 14-day follow-ups were observed in 58% ($n = 28$) of the cases. In 71% ($n = 20$) of cases of said stent deformities, patients described a novel unilateral headache on the side of the brain circulation in which the FD was implanted.

At the 14-day follow-up, in 93% ($n = 26$) of the cases of stent deformities, the distal half of the stent was involved and in only 7% ($n = 2$) were they present in the proximal half.

Due to the radiopaque nature of the proximal 8 markers of the p64 stent, we were also able to observe changes in them. In

64% ($n = 18$) of all the patient cases with subacute stent deformities, compacting of the proximal radiopaque markers was also seen at the 14-day mark.

ISS at the site of the implant was noted in 75% ($n = 36$) of all cases at the 6-month follow-up. In 53% ($n = 19$) of patients it was mild ($<25\%$ reduction of diameter), in 17% ($n = 6$) it was moderate (25%–50% reduction of diameter), and in 30% ($n = 11$) it was severe ($>50\%$ reduction of diameter). ISS, which can be labeled as notable (moderate + severe), was noted in 35% of all cases.

In the group of patients without an observable stent deformation ($n = 20$), 40% ($n = 8$) had ISS at the 6-month follow-up. In 87% ($n = 7$) of those cases it was mild and in only 13% ($n = 1$) was it moderate (Table 2).

In the group of patients with a stent deformity being present, 100% ($n = 28$) had angiographic ISS on follow-up. Of them, 43% ($n = 12$) had a mild stenosis, 18% ($n = 5$) had a moderate stenosis, and 39% ($n = 11$) had a severe stenosis.

At the 6-month follow-ups, no additional changes of the structure of any stent were observed on the conducted fluoroscopic images.

Fisher exact test was performed based on the presence of subacute stent stenosis and the presence of a unilateral headache in

Table 2: Characteristics of patients with and without stent deformities with regards to the incidence of ISS and the de novo exhibition of a unilateral headache postprocedurally

	ISS Incidence	ISS Severity (6-Month Follow-Up)			Novel Unilateral Headache at the 14-Day Follow-Up
		Mild	Moderate	Severe	
Patients with stent deformities at the 14-day follow-up (n=28)	n=28 (100%)	n=12/28 (43%)	n=5/28 (18%)	n=11/28 (39%)	n=20/28 (71%)
Patients without stent deformities at the 14-day follow-up (n=20)	n=8 (40%)	n=7/8 (87%)	n=1/8 (13%)	n=0 (0%)	n=2/20 (10%)

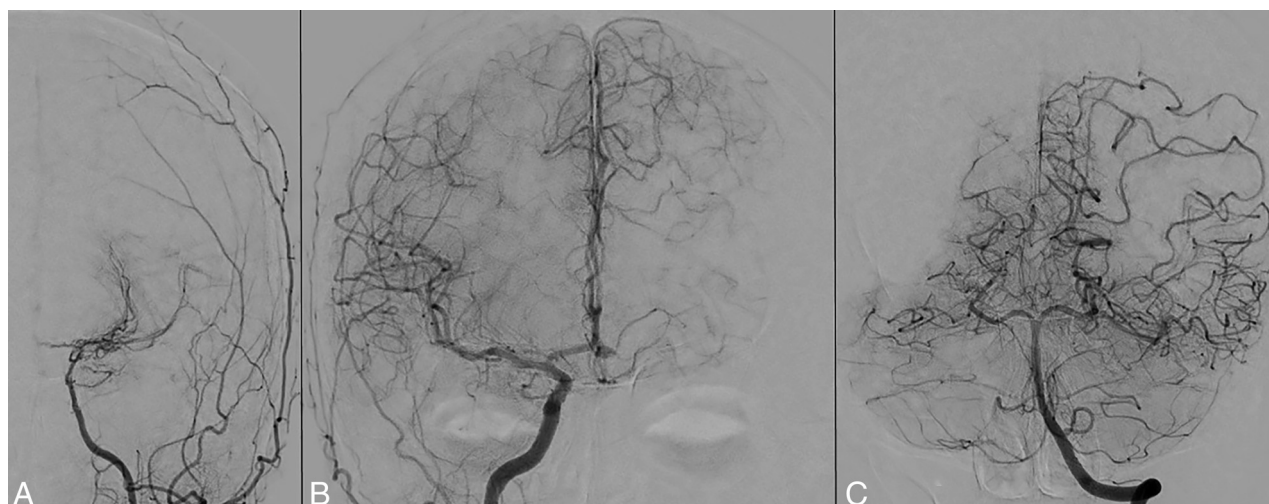

FIG 2. Six-month DSA control performed on the patient (anteroposterior projections). A severe narrowing of the distal left ICA in the segment of the placed FD and reduced blood flow in the left middle and anterior cerebral arteries can be seen (A). These findings correlate with the symptoms observed in the patient in the first month postprocedure. A compensatory development of leptomeningeal collaterals, collaterals from the posterior circulation and the right ICA, is the probable cause for the lack of vascular incidents during that time (B and C).

the patients enrolled in the study. A statistically significant ($P < .05$) association was observed between the seen stent deformity and a postprocedural novel unilateral headache on the side of the placed stent in the brain circulation. This symptom spontaneously resolved in all patients at the 6-month follow-up.

Spearman rank correlation was used to assess the relationship between the severity of the stent deformity and the observable ISS at the 6-month follow-up. There was a strong positive correlation between the 2 variables, $r = 0.768$, $P < .001$.

No significant correlation between pre-existing hypertension or smoking was associated with the occurrence of stent changes during the early fluoroscopic follow-up on the 14th day.

One of the included patients was a 44-year-old woman, who presented with right-sided headaches with increasing intensity for several months before treatment, and had a saccular aneurysm on the left ICA. The patient was admitted to the hospital and a FD stent was placed along the C5, C6, and C7 segments of the left ICA (Fig 1A, -B). Adequate wall apposition was achieved, with no peri- or postprocedural complications. Fourteen days after the procedure, she presented with headaches on the ipsilateral side of the placed stent and transitory contralateral weakness of the arm and leg. A control MRI showed no acute ischemic changes on the left side of her brain (Fig 1F, -G). We performed the second single-shot image of the stent, which showed a pronounced narrowing and elongation of the distal portion of the stent (Fig 1C, -D). Nonspecific neuroprotective medication was prescribed and the symptoms subsided within 1 month.

At the 6-month control DSA (Fig 2), the distal FD deformation, observed on the single-shot images, correlated with a visible segmental vessel stenosis and reduction of blood flow into the left anterior cerebral and MCAs. The DAPT was continued at our discretion until the next scheduled follow-up after another 6 months to avoid thromboembolic complications.

Another patient, who had a more pronounced deformity (Fig 3) underwent an MRI of the brain in the sixth month, due to refusal for admission into the hospital for DSA.

The patient's single-shot images pointed at a distal deformity of the stent, with it being more pronounced on the second control. Her results again correlated well with vessel stenosis of the distal ICA segment, in which the stent was positioned. Silent TOF sequence imaging as a method of choice for post-flow diversion follow-up was adequate in assessing the posttreatment anatomy and changes in the vasculature. We performed a single-shot of the implant after that, to assess the implant and find out the extent of the stent deformation. The patient also presented with postprocedural headaches, which we attributed to vessel stenosis, with no contralateral neurologic impairment being observed after a physical examination. The only complaint that was reported was the presence of visual symptoms (small visual field defects) on the side of the treated aneurysm, as the ostium of the ophthalmic artery was covered by the implant. The prasugrel intake was discontinued, and ASA was prescribed once daily for 1 year until the next follow-up.

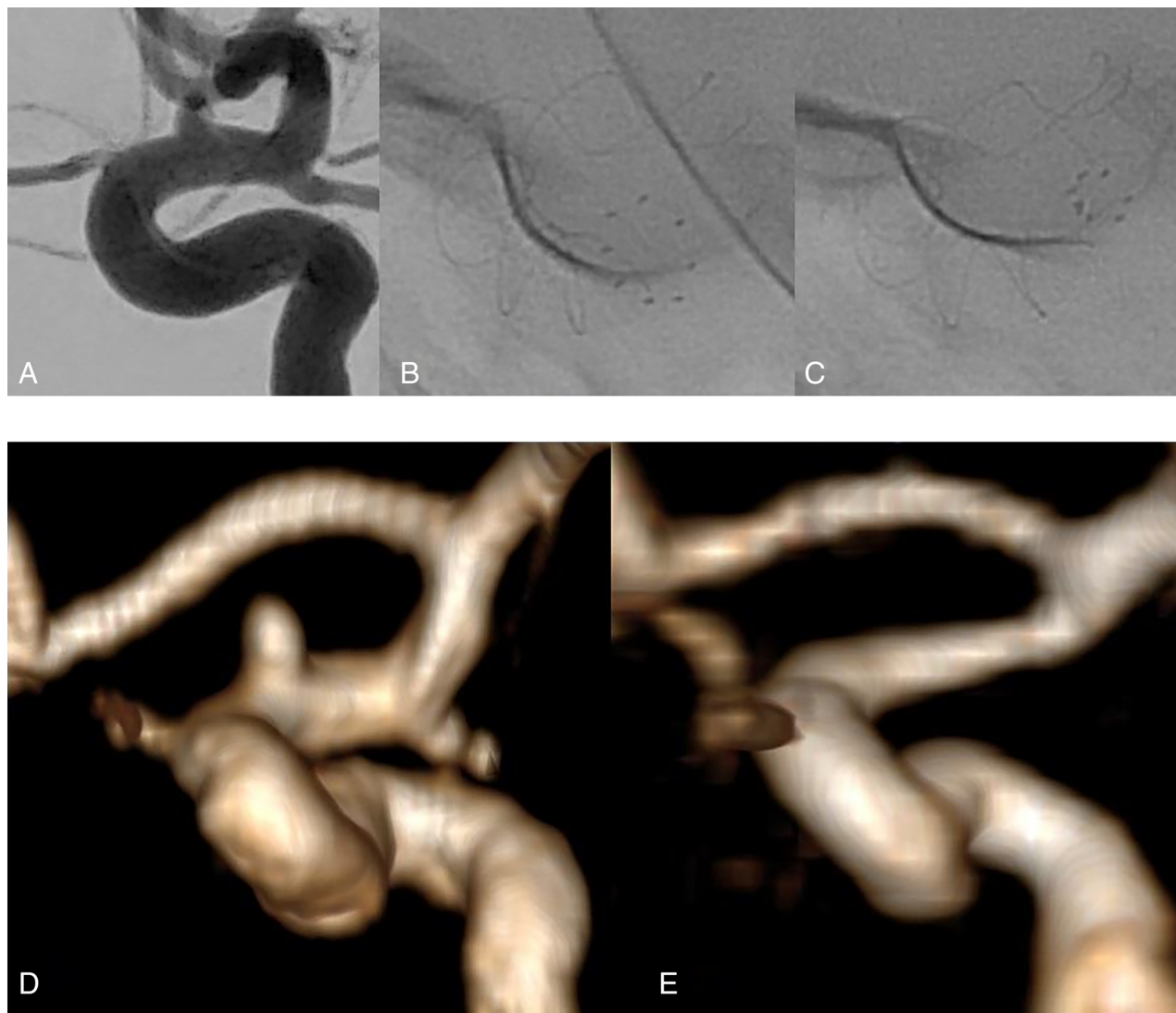

FIG 3. A, Intraprocedural DSA of the aneurysm on the left ICA. B and C, Fluoroscopy images of the stent, which illustrate the progressive narrowing and stenosis of the distal part of the implant. We can see a notable deformity on the 14-day single-shot (C), compared with the procedural image of the implant (B). The images of the deformity correlate well with the conducted follow-up MRI. We highlight a noticeable reduction of diameter of the distal ICA on follow-up (E), when compared with the pretreatment 3D-TOF reconstruction of the artery (D).

DISCUSSION

“To ask the right question is already half the solution of a problem.”-

Carl Jung

The event of ISS presents itself in a non-negligible percent of cases after flow diversion.^{15,44} Its true occurrence is most likely underreported due to the lack of unified criteria on which radiologists base its presence in their own pool of patients. As a still underdeveloped area of interest due to its mostly benign nature,⁴⁵ ISS continues to puzzle our community as to what exactly can be pointed at as a culprit for its development. Most probably, both factors innate to the device, as well as the organism and their synergistic interaction can give a head start to the biochemical and morphologic “dance,” ultimately leading up to the images we observe on follow-up. Several important questions arise, as regarding to the phenomenon. The most obvious is “Why does it happen?” Next is: “Which patients are at most risk for ISS?” and of course, “Is there a way to avoid or counteract it?” The answers to

these questions seem to be complex. In our observations and analysis, ISS is not a single entity, and most published papers simply refer to the presence of vessel stenosis in the area of the FD stent. Formulating a correct hypothesis, regarding what exactly ISS is and whether its formation is linked with different separate pathologic and morphologic pathways opens up new windows of opportunities when it comes to its avoidance. In our paper, we present a single possible explanation that is linked with a subacute vessel reaction to the device, which it seems in some cases even has clinical implications. With the emergence of new flow-diverting devices with different properties (radial force, porosity, and oversizing recommendations),⁴⁶ quantitative differences in the occurrence of ISS could lead to an answer if an innate aspect of theirs is causing more harm than good and in turn formulate new safety guidelines and lower procedural risks.

Our short-term follow-up aimed at only evaluating the stent itself adheres to the fact that endothelialization is still not fully

completed at that point in time. Based on this, we can postulate that any and all deformities of the stent are purely based on the reaction of the vessel toward the implant and its constriction, due to the endothelial dysfunction and smooth muscle cells activation happening postprocedurally. So why is the distal part of the stent the one to suffer the consequences most often? Again, we hypothesize that at the distal end point, the stent tends to be a bit more oversized, as compared with the proximal end, due to the nature of progressive narrowing of arterial blood vessels the more distally they traverse. The exaggerated oversizing leads to a larger discrepancy between the nominal size of the FD and the actual diameter, when placed in vivo, which in turn increases the radial force of the implant, but decreases its rigidity, as the increase in porosity with oversizing leads to less metal coverage, and thus less resistance to outside forces per square unit.^{47,48} The increase of force leads to an increased reaction from the carotid artery (or the MCA if it is placed there), and the lower threshold for an externally applied force (the vessel constriction) to lead to a deformity of the implant, brings us to the observations we have made.

In our data analysis, we found that patients with more pronounced stent deformities presented with disproportionately higher degrees of ISS, compared with ones who did not have a deformity. This finding suggests that the vessels react in more than one way to the implant: vasoconstriction and intimal overgrowth seem to have both been responsible for the development of segmental vessel lumen reduction on follow-up.

An interesting point to be made is that not all patients exhibit this phenomenon. In our cohort, even though relatively small, we found no male patients with a subacute stent deformity, leading to the question of whether there is a large discrepancy of vessel reactivity in men and women that could explain these differences. Of course, due to the small sample size of male patients, this observation is subject to bias.

Once a clear pathologic mechanism is defined, it can lead to pointing out demographic characteristics that highlight a risk for ISS, and furthermore a conservative drug therapy to avoid it. The use of cerebral vasodilators presents one such option in the early postprocedural period, which could combat this aspect of the condition and extensive trials based on the pharmacodynamics and safety profile need to be conducted to empirically establish a protocol for prophylaxis. Such a protocol can further increase the safety profile of FDs, because as rare as they are, complications linked with the therapy can be dire.

Of all that has been said, it becomes clear that our experience and findings are just the tip of the iceberg. Once the first steps have been made to divide the problem into smaller compartments and we formulate the right questions, the therapeutic guidelines of flow diversion will further expand, with the ultimate goal of improving patient outcomes.

Limitations

A potential limitation of our study is the lack of a long-term follow-up, after the initial DSA at the 6-month mark. With the available data regarding ISS, it becomes clear that in some cases it can spontaneously resolve itself, given enough time. Another limiting factor is that the only device used in the study was the p64 FD stent. Studies that include other FD stents are needed to

further assess this phenomenon. Furthermore, the clinical evaluation of the observed postprocedural headaches lacks an adequately implemented grading scale, which could serve as a reference point from a temporal point of view.

CONCLUSIONS

Subacute stent deformities after flow diversion are not a rare occurrence. The de novo exhibition of symptoms can potentially be linked with the emergence of said deformities, which can become more symptomatic in severe cases. A dedicated prospective study with a focused design to evaluate the concrete connection between these symptoms and the observation of subacute stent deformations is needed to further clarify this phenomenon. In our study, patients with stent deformities presented with angiographic segmental vessel stenosis in all cases at the midterm follow-up (6 months). The overall incidence of moderate and severe ISS was 35%. Patients with stent deformities presented more often and with more pronounced ISS, than those without deformities. Our prospective observational study underlines the need for a unified classification of ISS with separation between the different entities that comprise the phenomenon of vessel stenosis, both intimal overgrowth and changes in the stent structure postprocedurally.

Disclosure forms provided by the authors are available with the full text and PDF of this article at www.ajnr.org.

REFERENCES

1. Lylyk P, Miranda C, Ceratto R, et al. **Curative endovascular reconstruction of cerebral aneurysms with the Pipeline embolization device: the Buenos Aires experience.** *Neurosurgery* 2009;64:632–43 [CrossRef Medline](#)
2. Pierot L. **Flow diverter stents in the treatment of intracranial aneurysms: where are we?** *J Neuroradiol* 2011;38:40–46 [CrossRef Medline](#)
3. Gester K, Luchtefeld I, Büsen M, et al. **In vitro evaluation of intracranial aneurysmal, flow-diverter-induced thrombus formation: a feasibility study.** *AJNR Am J Neuroradiol* 2016;37:490–96 [CrossRef Medline](#)
4. Sadasivan C, Cesar L, Seong J, et al. **An original flow diversion device for the treatment of intracranial aneurysms: evaluation in the rabbit elastase-induced model.** *Stroke* 2009;40:952–58 [CrossRef Medline](#)
5. Zhang Y, Wang Y, Kao E, et al. **Towards optimal flow diverter porosity for the treatment of intracranial aneurysm.** *J Biomech* 2019; 82:20–27 [CrossRef Medline](#)
6. Ravindran K, Salem MM, Alturki AY, et al. **Endothelialization following flow diversion for intracranial aneurysms: a systematic review.** *AJNR Am J Neuroradiol* 2019;40:295–301 [CrossRef Medline](#)
7. Fiorella D, Lylyk P, Szikora I, et al. **Curative cerebrovascular reconstruction with the Pipeline embolization device: the emergence of definitive endovascular therapy for intracranial aneurysms.** *J Neurointerv Surg* 2009;1:56–65 [CrossRef Medline](#)
8. Texakalidis P, Bekelis K, Atallah E, et al. **Flow diversion with the Pipeline embolization device for patients with intracranial aneurysms and antiplatelet therapy: a systematic literature review.** *Clin Neurol Neurosurg* 2017;161:78–87 [CrossRef Medline](#)
9. Galli M, Franchi F, Rollini F, et al. **Platelet P2Y₁₂ inhibiting therapy in adjunct to vascular dose of rivaroxaban or aspirin: a pharmacodynamic study of dual pathway inhibition vs. dual antiplatelet therapy.** *Eur Heart J Cardiovasc Pharmacother* 2022;8:728–37 [CrossRef Medline](#)
10. Van Belle E, Tio FO, Couffignal T, et al. **Stent endothelialization: time course, impact of local catheter delivery, feasibility of recombinant protein administration, and response to cytokine expedition.** *Circulation* 1997;95:438–48 [CrossRef Medline](#)

11. Berge J, Biondi A, Machi P, et al. **Flow-diverter Silk stent for the treatment of intracranial aneurysms: 1-year follow-up in a multicenter study.** *AJNR Am J Neuroradiol* 2012;33:1150–55 [CrossRef Medline](#)
12. Guzzardi G, Galbiati A, Stanca C, et al. **Flow diverter stents with hydrophilic polymer coating for the treatment of acutely ruptured aneurysms using single antiplatelet therapy: preliminary experience.** *Interv Neuroradiol* 2020;26:525–31 [CrossRef Medline](#)
13. Fiehler J, Ortega-Gutierrez S, Anagnostakou V, et al. **Evaluation of flow diverters for cerebral aneurysm therapy: recommendations for imaging analyses in clinical studies, endorsed by ESMINT, ESNR, OCIN, SILAN, SNIS, and WFITN.** *J Neurointerv Surg* Epub ahead of print June 2, 2024 [CrossRef](#)
14. Gui S, Chen X, Wei D, et al. **Long-term outcomes and dynamic changes of in-stent stenosis after Pipeline embolization device treatment of intracranial aneurysms.** *J NeuroInterventional Surg* 2023;15:1187–93
15. You W, Lv J, Li Z, et al. **The incidence and predictors of in-stent stenosis after Pipeline flow-diverter stenting for intracranial aneurysm treatment.** *Front Neurol* 2023;14:1140497 [CrossRef Medline](#)
16. John S, Bain MD, Hui FK, et al. **Long-term follow-up of in-stent stenosis after Pipeline flow diversion treatment of intracranial aneurysms.** *Neurosurgery* 2016;78:862–67 [CrossRef Medline](#)
17. Essbaiheen F, AlQahtani H, Almansoori TM, et al. **Transient in-stent stenosis at mid-term angiographic follow-up in patients treated with SILK flow diverter stents: incidence, clinical significance and long-term follow-up.** *J Neurointerv Surg* 2019;11:166–70 [CrossRef Medline](#)
18. Kim SJ, Kim YJ, Ko JH. **Long term outcome of in-stent stenosis after stent assisted coil embolization for cerebral aneurysm.** *J Korean Neurosurg Soc* 2019;62:536–44 [CrossRef Medline](#)
19. Schwartz RS, Chronos NA, Virmani R. **Preclinical restenosis models and drug-eluting stents.** *J Am Coll Cardiol* 2004;44:1373–85 [CrossRef](#)
20. Caroff J, Iacobucci M, Rouchaud A, et al. **The occurrence of neointimal hyperplasia after flow-diverter implantation is associated with cardiovascular risks factors and the stent design.** *J Neurointerv Surg* 2019;11:610–13 [CrossRef Medline](#)
21. Lehoux S, Tedgui A. **Signal transduction of mechanical stresses in the vascular wall.** *Hypertension* 1998;32:338–45 [CrossRef Medline](#)
22. Lu D, Kassab GS. **Role of shear stress and stretch in vascular mechanobiology.** *J R Soc Interface* 2011;8:1379–85 [CrossRef Medline](#)
23. Davies PF. **Flow-mediated endothelial mechanotransduction.** *Physiol Rev* 1995;75:519–60 [CrossRef Medline](#)
24. Haas TA, Plow EF. **Integrin-ligand interactions: a year in review.** *Curr Opin Cell Biol* 1994;6:656–62 [CrossRef Medline](#)
25. Lo SH, Weisberg E, Chen LB. **Tensin: a potential link between the cytoskeleton and signal transduction.** *BioEssays* 1994;16:817–23 [CrossRef Medline](#)
26. Kornberg L, Earp HS, Parsons JT, et al. **Cell adhesion or integrin clustering increases phosphorylation of a focal adhesion-associated tyrosine kinase.** *J Biol Chem* 1992;267:23439–42 [Medline](#)
27. Sokabe M, Nunogaki K, Naruse K, et al. **Mechanics of patch clamped and intact cell-membranes in relation to SA channel activation.** *Jpn J Physiol* 1993;43(Suppl 1):S197–204 [Medline](#)
28. Burridge K, Fath K, Kelly T, et al. **Focal adhesions: transmembrane junctions between the extracellular matrix and the cytoskeleton.** *Annu Rev Cell Biol* 1988;4:487–525 [CrossRef Medline](#)
29. Zhao S, Suciu A, Ziegler T, et al. **Synergistic effects of fluid shear stress and cyclic circumferential stretch on vascular endothelial cell morphology and cytoskeleton.** *Arterioscler Thromb Vasc Biol* 1995;15:1781–86 [CrossRef Medline](#)
30. Tousoulis D, Kampoli AM, Tentolouris N, et al. **The role of nitric oxide on endothelial function.** *Curr Vasc Pharmacol* 2012;10:4–18 [CrossRef Medline](#)
31. Zhao Y, Vanhoutte PM, Leung SWS. **Vascular nitric oxide: beyond eNOS.** *J Pharmacol Sci* 2015;129:83–94 [CrossRef Medline](#)
32. Schulz E, Gori T, Münzel T. **Oxidative stress and endothelial dysfunction in hypertension.** *Hypertens Res* 2011;34:665–73 [CrossRef Medline](#)
33. Sun D, Huang A, Smith CJ, et al. **Enhanced release of prostaglandins contributes to flow-induced arteriolar dilation in eNOS knockout mice.** *Circ Res* 1999;85:288–93 [CrossRef Medline](#)
34. Chen J, Zhou Y, Liu S, et al. **Biomechanical signal communication in vascular smooth muscle cells.** *J Cell Commun Signal* 2020;14:357–76 [CrossRef Medline](#)
35. Martinez-Quinones P, McCarthy CG, Watts SW, et al. **Hypertension induced morphological and physiological changes in cells of the arterial wall.** *Am J Hypertens* 2018;31:1067–78 [CrossRef Medline](#)
36. Seger R, Krebs EG. **The MAPK signaling cascade.** *FASEB J* 1995;9:726–35 [CrossRef](#)
37. Malek AM, Gibbons GH, Dzau VJ, et al. **Fluid shear stress differentially modulates expression of genes encoding basic fibroblast growth factor and platelet-derived growth factor B chain in vascular endothelium.** *J Clin Invest* 1993;92:2013–21 [CrossRef Medline](#)
38. Chen HY, Hermiller J, Sinha AK, et al. **Effects of stent sizing on endothelial and vessel wall stress: potential mechanisms for in-stent restenosis.** *J Appl Physiol* (1985) 2009;106:1686–91 [CrossRef Medline](#)
39. Wang J, Jin X, Huang Y, et al. **Endovascular stent-induced alterations in host artery mechanical environments and their roles in stent restenosis and late thrombosis.** *Regen Biomater* 2018;5:177–87 [CrossRef Medline](#)
40. Haga JH, Li YSJ, Chien S. **Molecular basis of the effects of mechanical stretch on vascular smooth muscle cells.** *J Biomech* 2007;40:947–60 [CrossRef Medline](#)
41. Welt FGP, Rogers C. **Inflammation and restenosis in the stent era.** *Arterioscler Thromb Vasc Biol* 2002;22:1769–76 [CrossRef Medline](#)
42. Schob S, Richter C, Scherlach C, et al. **Delayed stroke after aneurysm treatment with flow diverters in small cerebral vessels: a potentially critical complication caused by subacute vasospasm.** *J Clin Med* 2019;8:1649 [CrossRef](#)
43. Von Elm E, Altman DG, Egger M, et al; STROBE Initiative. **The Strengthening the Reporting of Observational Studies in Epidemiology (STROBE) Statement: guidelines for reporting observational studies.** *Int J Surg* 2014;12:1495–99 [CrossRef Medline](#)
44. Aguilar Pérez M, Bhogal P, Henkes E, et al. **In-stent stenosis after p64 flow diverter treatment.** *Clin Neuroradiol* 2018;28:563–68 [CrossRef Medline](#)
45. Chalouhi N, Polifka A, Daou B, et al. **In-pipeline stenosis: incidence, predictors, and clinical outcomes.** *Neurosurgery* 2015;77:875–79 [CrossRef Medline](#)
46. Alderazi YJ, Shastri D, Kass-Hout T, et al. **Flow diverters for intracranial aneurysms.** *Stroke Res Treat* 2014;2014:415653–12 [CrossRef Medline](#)
47. Makoyeva A, Bing F, Darsaut TE, et al. **The varying porosity of braided self-expanding stents and flow diverters: an experimental study.** *AJNR Am J Neuroradiol* 2013;34:596–602 [CrossRef Medline](#)
48. Shapiro M, Raz E, Becske T, et al. **Variable porosity of the Pipeline embolization device in straight and curved vessels: a guide for optimal deployment strategy.** *AJNR Am J Neuroradiol* 2014;35:727–33 [CrossRef Medline](#)