



**Providing Choice & Value**  
Generic CT and MRI Contrast Agents

**FRESENIUS  
KABI**

**CONTACT REP**

**AJNR**

## **T2-FLAIR Mismatch Sign in Pediatric Low-Grade Glioma**

M.W. Wagner, L. Nobre, K. Namdar, F. Khalvati, U. Tabori,  
C. Hawkins and B.B. Ertl-Wagner

*AJNR Am J Neuroradiol* 2023, 44 (7) 841-845

doi: <https://doi.org/10.3174/ajnr.A7916>

<http://www.ajnr.org/content/44/7/841>

This information is current as  
of July 21, 2025.

# T2-FLAIR Mismatch Sign in Pediatric Low-Grade Glioma

 M.W. Wagner,  L. Nobre,  K. Namdar,  F. Khalvati,  U. Tabori,  C. Hawkins, and  B.B. Ertl-Wagner



## ABSTRACT

**BACKGROUND AND PURPOSE:** No qualitative imaging feature currently predicts molecular alterations of pediatric low-grade gliomas with high sensitivity or specificity. The T2-FLAIR mismatch sign predicts *IDH*-mutated 1p19q noncodeleted adult gliomas with high specificity. We aimed to assess the significance of the T2-FLAIR mismatch sign in pediatric low-grade gliomas.

**MATERIALS AND METHODS:** Pretreatment MR images acquired between January 2001 and August 2018 in pediatric patients with pediatric low-grade gliomas were retrospectively identified. Inclusion criteria were the following: 1) 0–18 years of age, 2) availability of molecular information in histopathologically confirmed cases, and 3) availability of preoperative brain MR imaging with non-motion-degraded T2-weighted and FLAIR sequences. Spinal cord tumors were excluded.

**RESULTS:** Three hundred forty-nine patients were included (187 boys; mean age, 8.7 [SD, 4.8] years; range, 0.5–17.7 years). *KIAA1549*–*BRAF* proto-oncogene (*BRAF*) fusion and *BRAF* p.V600E mutation were the most common molecular markers ( $n = 148$ , 42%, and  $n = 73$ , 20.7%, respectively). The T2-FLAIR mismatch sign was present in 25 patients (7.2%). Of these, 9 were dysembryoplastic neuroepithelial tumors; 8, low-grade astrocytomas; 5, diffuse astrocytomas; 1, a pilocytic astrocytoma; 1, a glioneuronal tumor; and 1, an angiocentric glioma. None of the 25 T2-FLAIR mismatch pediatric low-grade gliomas were *BRAF* p.V600E–mutated. Fourteen of 25 pediatric low-grade gliomas with the T2-FLAIR mismatch sign had rare molecular alterations, while the molecular subtype was unknown for 11 tumors.

**CONCLUSIONS:** The T2-FLAIR mismatch sign was not observed in the common molecular alterations, *BRAF* p.V600E–mutated and *KIAA1549*–*BRAF* fused pediatric low-grade gliomas, while it was encountered in pediatric low-grade gliomas with rare pediatric molecular alterations.


**ABBREVIATIONS:** DNET = dysembryoplastic neuroepithelial tumor; pLGG = pediatric low-grade glioma; RAS/MAPK = RAS-mitogen-activated protein kinase; TKDD = tyrosine kinase domain duplication

**P**ediatric low-grade gliomas (pLGGs) are the most common pediatric brain tumors, accounting for approximately 40%

Received December 16, 2022; accepted after revision May 22, 2023.

From the Division of Neuroradiology (M.W.W., F.K., B.B.E.-W.), Department of Diagnostic Imaging, Department of Neurooncology (L.N., U.T.), and Department of Paediatric Laboratory Medicine (C.H.), Division of Pathology, The Hospital for Sick Children (SickKids), Toronto, Ontario, Canada; Neurosciences & Mental Health Research Program (M.W.W., F.K., B.B.E.-W.), SickKids Research Institute, Toronto, Ontario, Canada; Department of Medical Imaging (M.W.W., K.N., F.K., B.B.E.-W.), Institute of Medical Science (F.K.), Department of Computer Science (K.N., F.K.), and Department of Mechanical and Industrial Engineering (K.N., F.K.), University of Toronto, Toronto, Ontario, Canada; Department of Neuroradiology (M.W.W.), University Hospital Augsburg, Augsburg, Germany; and Vector Institute (F.K.), Toronto, Ontario, Canada. C. Hawkins was supported by the Canadian Cancer Society (grant No. 702296) and the Canadian Institute of Health Research (grant No. 159805).

Please address correspondence to Matthias W. Wagner, MD, Division of Neuroradiology, Department of Diagnostic Imaging, The Hospital for Sick Children (SickKids), Toronto, ON, Canada; e-mail: m.w.wagner@me.com

 Indicates open access to non-subscribers at [www.ajnr.org](http://www.ajnr.org)

 Indicates article with online supplemental data.

<http://dx.doi.org/10.3174/ajnr.A7916>

of all pediatric brain tumors.<sup>1,2</sup> They are a heterogeneous group of tumors classified by the World Health Organization as grade 1 or 2.<sup>3</sup> Molecular profiling studies have identified genetic events in pLGGs involving the RAS-mitogen-activated protein kinase (RAS/MAPK) pathway.<sup>4</sup> Most commonly, these are events involving B-Raf proto-oncogene (*BRAF*) or germline neurofibromatosis 1 (*NF1*) alterations.<sup>5,6</sup> Rarer alterations affect RAS/MAPK signaling, including fibroblast growth factor receptor (*FGFR*)1/2/3, *ROS1*, and non-RAS/MAPK alterations, such as *MYB*, *MYBL1*, *IDH1*, and others.<sup>1,4</sup> To date, no qualitative imaging features exist predicting any of the pLGG molecular alterations with high sensitivity or specificity.

In 2017, Patel et al<sup>7</sup> described the T2-FLAIR mismatch sign in a sample of 125 adult lower-grade gliomas to predict *IDH*-mutated 1p19q noncodeleted gliomas with high specificity. It is defined by hyperintense signal on T2-weighted sequences and hypointense signal on FLAIR sequences with a hyperintense peripheral rim. This imaging feature has since gained increasing attention in adult

neuroradiology due to the wide availability of T2-weighted and FLAIR sequences. Currently, there is only anecdotal evidence of the T2-FLAIR mismatch sign in the pediatric population. In 2019, Johnson et al.<sup>8</sup> reported 5 false-positive instances of T2-FLAIR mismatch, 4 of which occurred in children and 3 of which were neoplastic. These included a pilomyxoid astrocytoma, a H3K27M-mutant midline glioma, and a low-grade astrocytoma with an *MYB* rearrangement.<sup>8</sup> To our knowledge, no prior study has systematically investigated the occurrence of the T2-FLAIR mismatch sign in pLGG.

We therefore aimed to assess the occurrence of the T2-FLAIR mismatch sign in pLGG in a large pediatric institutional cohort.

## MATERIALS AND METHODS

### Patient Sample

This retrospective study was approved by the local institutional review board (The Hospital for Sick Children, Toronto). Because of the retrospective nature of the study, informed consent was waived by the local research ethics board. All patients were identified from the electronic health record database between January 2001 and August 2018. Patient inclusion criteria were the following: 1) 0–18 years of age, 2) the availability of molecular information in histopathologically confirmed pLGG as defined by Louis et al.,<sup>9</sup> and 3) the availability of preoperative brain MR imaging with non-motion-degraded T2-weighted and FLAIR sequences. Spinal cord tumors were not included in this study.

### Molecular Analysis

*BRAF* fusion status was determined using an nCounter Metabolic Pathways Panel (NanoString Technologies) or fluorescence in situ hybridization, while the *BRAF* p.V600E mutation was determined using immunohistochemistry or droplet digital polymerase chain reaction. Additional alterations were detected by RNA panel sequencing as previously described.<sup>4</sup> For most patients, molecular analysis was performed with formalin-fixed paraffin-embedded tissue that was obtained at the time of the tissue sampling.

### MR Imaging

All patients underwent MR imaging of the brain at 1.5T or 3T across various vendors (Signa, GE Healthcare; Achieva, Philips Healthcare; Magnetom Skyra, Siemens). The standardized sequence protocol at our institution included the following sequences: a sagittal 3D T1-weighted sequence with axial and coronal reformats, an axial DWI, an axial and/or coronal FLAIR sequence, an axial and/or coronal and/or sagittal T2-weighted sequence, an axial SWI or multiplanar gradient recalled acquisition, a gadolinium-based contrast agent-enhanced axial 3D T1-weighted sequence with coronal and sagittal reformats, and a gadolinium-based contrast agent-enhanced axial or coronal T1-weighted spin-echo sequence. All MR imaging data were extracted from the PACS, de-identified for further analyses, and transferred to an off-line workstation.

### Analysis of the Study Cohort and Statistical Analysis

Two pediatric neuroradiologists (M.W.W. with 4 years of experience after a pediatric neuroradiology fellowship and B.B.E.-W.

with >15 years of postfellowship experience) reviewed baseline brain MR images of all included patients, blinded to clinical and molecular data. Signal characteristics of brain tumors were reviewed, and the presence of the T2-FLAIR mismatch sign was noted on the basis of the description by Jain et al.<sup>10</sup> Additionally, images were reviewed for the presence of hemosiderin on SWI and multiplanar gradient recalled sequences. Decisions were reached in consensus.

Descriptive statistical analyses were performed using the Statistical Package for the Social Sciences software (SPSS), Version 18 (IBM). For baseline characteristics, continuous data were presented using mean (SD), and categorical data were presented using integers and percentages.

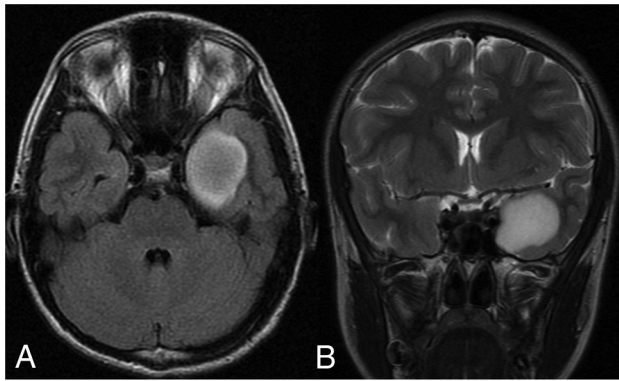
## RESULTS

### Patient Demographics, Histopathologic Diagnoses, and Molecular Markers

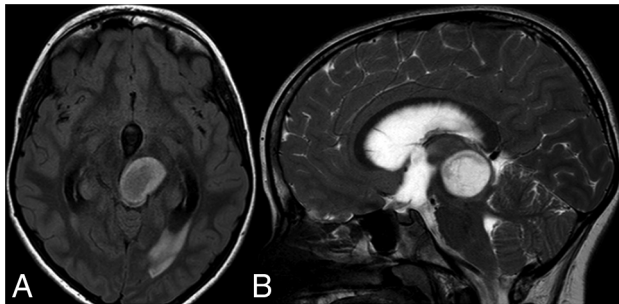
A total of 389 MR images of 389 patients were available for analysis. Of these, 40 MR images were excluded due to a nonavailable FLAIR sequence ( $n = 28$ ), posttherapeutic status ( $n = 5$ ), tumor extending into the cervical cord ( $n = 3$ ), nonavailable molecular information ( $n = 2$ ), a nonavailable T2-weighted sequence ( $n = 1$ ), and motion degradation of the FLAIR sequence ( $n = 1$ ). The inclusion criteria were fulfilled by 349 patients (187 boys, 53.6%). The mean age at the time of diagnosis was 8.7 (SD, 4.8) years (range, 0.5–17.7 years).

The sample consisted of biopsy-proved pilocytic astrocytomas ( $n = 151$ ), low-grade astrocytomas ( $n = 66$ ), gangliogliomas ( $n = 43$ ), dysembryoplastic neuroepithelial tumors (DNETs) ( $n = 24$ ), diffuse astrocytomas ( $n = 22$ ), pilomyxoid astrocytomas ( $n = 11$ ), pleomorphic xanthoastrocytomas ( $n = 7$ ), oligodendrogliomas ( $n = 7$ ), glioneuronal tumors ( $n = 5$ ), angiocentric gliomas ( $n = 5$ ), desmoplastic infantile gliomas ( $n = 2$ ), neurocytomas ( $n = 2$ ), mixed tumor components ( $n = 2$ ), gangliocytoma ( $n = 1$ ), and polymorphous low-grade glioneuronal tumor of the young ( $n = 1$ ). There were no *IDH*-mutant 1p/19q noncodeleted gliomas.

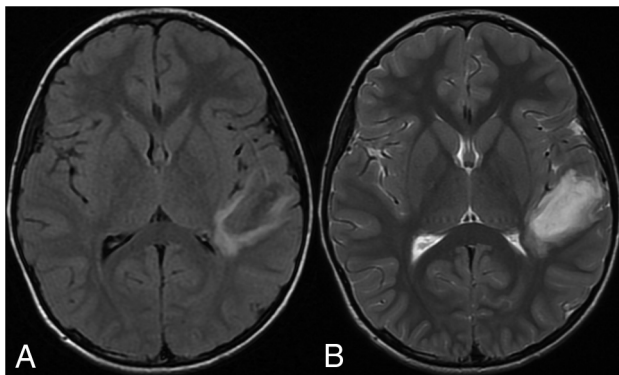
*KIAA1549-BRAF* fusion was the most common molecular marker ( $n = 148$ ). Less common alterations were *BRAF* p.V600E mutation ( $n = 73$ ), *FGFR1* tyrosine kinase domain duplication (TKDD) ( $n = 7$ ), *NF1* ( $n = 11$ ), *FGFR1-TACC1* fusion ( $n = 6$ ), alterations in *FGFR2* ( $n = 6$ ), *MYB* ( $n = 5$ ), *MYBL1* ( $n = 4$ ), *FGFR1-N546K* ( $n = 1$ ), mutation of *IDH1* ( $n = 3$ ), alteration of *MET* N375S ( $n = 2$ ), *QKI-RAF1* ( $n = 2$ ), *BRAF* V600ins ( $n = 2$ ), *FGFR1* deletion ( $n = 1$ ), *FGFR4* ( $n = 1$ ), *BRAF* D594N and *KRAS* Q61R ( $n = 1$ ), *BRAF-FAM131B* ( $n = 1$ ), *CLCN6-BRAF* ( $n = 1$ ), *FYCO-RAF1* ( $n = 1$ ), fusion of *GOPC-ROS1* ( $n = 1$ ), alterations in *KIT* V825I ( $n = 1$ ), *KRAS*-Q22K ( $n = 1$ ), *MAP2K1* ( $n = 1$ ), *MET* H1112Y ( $n = 1$ ), *MID1-NTRK2* ( $n = 1$ ), mutation of *MYB-QKI* ( $n = 1$ ), fusion of *PDGFB-LRP1* ( $n = 1$ ), and alteration of *PDGFRA-K385M* ( $n = 1$ ), *PIK3CA* Q60K ( $n = 1$ ), *RET* D892N ( $n = 1$ ), *SF3B1-NTRK2* ( $n = 1$ ), *TAX1BP1-BRAF* ( $n = 1$ ), *FGFR1-K654N*, T656P ( $n = 1$ ), and *FGFR1-K646E* ( $n = 1$ ). A total of 56 children with pLGG had incomplete test panels. Of those, 50 were negative for *KIAA1549-BRAF* fusion, while no test result was available for 6 tumors. Fifty-three were negative for the *BRAF* p.V600E mutation, while no test result was available for 3



**FIG 1.** A 13-year-old boy with a left temporal diffuse astrocytoma with an *MYBL1* alteration and T2-FLAIR mismatch sign. A, axial FLAIR and B, coronal T2.



**FIG 2.** A 10-year-old girl with a midline low-grade astrocytoma with *FGFR1-TACC* fusion and the T2-FLAIR mismatch sign. A, axial FLAIR and B, coronal T2.

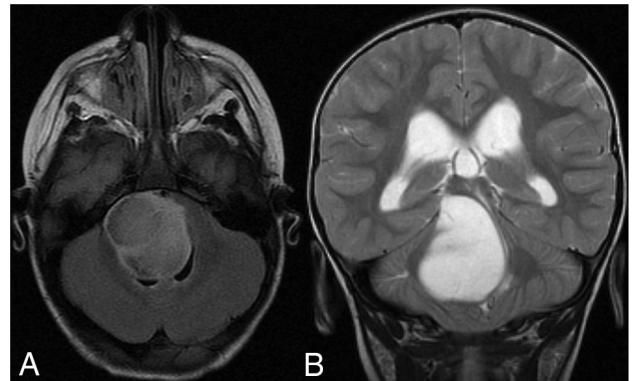


**FIG 3.** A 9-year-old boy with a left temporal DNET with an *FGFR4* alteration and the T2-FLAIR mismatch sign. A, axial FLAIR and B, sagittal T2.

tumors. Last, 52 were negative for both *FGFR1-N546K* alteration and mutation of *IDH1*, while no test result was available for 4 tumors, respectively.

#### Analysis of T2-FLAIR Mismatch Sign

The T2-FLAIR mismatch sign was observed in 25 of 349 patients with pLGG (7.2%). Seventeen patients were boys (68%). The mean age was 8.3 (SD, 4.8) years (range, 1–16 years). The T2-FLAIR mismatch sign was encountered in the frontal lobe ( $n = 10$ ), temporal lobe ( $n = 7$ ), parietal lobe ( $n = 3$ ), thalamus ( $n = 2$ ), brainstem ( $n = 2$ ), and intraventricularly ( $n = 1$ ). Of the 25 pLGGs with the T2-FLAIR mismatch sign, 9 were DNETs (36%),



**FIG 4.** A 2-year-old boy with a brainstem low-grade astrocytoma with *MYB-QKI* fusion and the T2-FLAIR mismatch sign. A, axial FLAIR and B, axial T2.

8 were low-grade astrocytomas (32%), 5 were diffuse astrocytomas (20%), 1 was a pilocytic astrocytoma (4%), 1 was a glioneuronal tumor (4%), and 1 was an angiocentric glioma (4%).

In relation to all patients reviewed, the T2-FLAIR mismatch sign was found in 9 of 24 DNETs (37.5%), 5 of 22 diffuse astrocytomas (22.7%), 1 of 5 glioneuronal tumors (20%), 1 of 5 angiocentric gliomas (20%), 8 of 66 low-grade astrocytomas (12.1%), and 1 of 151 pilocytic astrocytomas (0.7%).

In relation to all patients reviewed, the T2-FLAIR mismatch sign was found in 3 of 4 *MYBL1* pLGGs (75%, Fig 1), 2 of 7 *FGFR1-TKDD* pLGGs (28.6%), 2 of 6 *FGFR1-TACC1* pLGGs (33.3%, Fig 2), 1 of 5 *MYB* pLGGs (20%), 1 of 1 *FGFR4* pLGGs (100%, Fig 3), 1 of 1 *GOPC-ROS1* pLGGs (100%), 1 of 3 *IDH1* pLGGs (33.3%), 1 of 2 *MET N375S* pLGGs (50%), 1 of 1 *MYB-QKI* pLGG (100%, Fig 4), and 1 of 1 *PDGFB-LRP1* pLGG (100%). Among the 11 tumors with incomplete test panels, all were negative for the *BRAF* p.V600E mutation, *FGFR1-N546K* alteration, and a mutation of *IDH1*. Nine of 11 tumors were also negative for *KIAA1549-BRAF* fusion, while no test result was available for 2 tumors.

Notably, no pLGG with the T2-FLAIR mismatch sign was *BRAF* p.V600E-mutated, and at least 23 of 25 tumors with a T2-FLAIR mismatch sign were also negative for *KIAA1549-BRAF* fusion (Online Supplemental Data). The Online Supplemental Data show the distribution of the histopathologic diagnoses of the pLGGs with a T2-FLAIR mismatch sign according to their molecular markers.

No abnormal susceptibility was found in any of the 25 pLGGs with the T2-FLAIR mismatch sign.

#### DISCUSSION

Using a large institutional cohort, we aimed to assess the occurrence of the T2-FLAIR mismatch sign in pLGGs and its relation to histopathologic and molecular markers. We found the T2-FLAIR mismatch sign to be absent in *KIAA1549-BRAF*-fused and *BRAF* p.V600E-mutated pLGGs. The sign was more commonly noted in rare molecular markers including *MYBL1* pLGG, *FGFR1-TKDD* pLGG, *FGFR1-TACC1* pLGG, *MYB* pLGG, *FGFR4* pLGG, *GOPC-ROS1* pLGG, *IDH1* pLGG, *MET N375S* pLGG, *MYB-QKI* pLGG, and *PDGFB-LRP1* pLGG. Fifty-six tumors had incomplete test panels. However, the most common molecular alterations



(*KIAA1549-BRAF* fusion and *BRAF* p.V600E mutation) in addition to *FGFR1-N546K* alteration and mutation of *IDH1* were excluded in almost all tumors. Of these 56 tumors, 11 (19.6%) demonstrated the T2-FLAIR mismatch sign.

In their recent meta-analysis, Do et al<sup>11</sup> systematically reviewed the predictive accuracy of the T2-FLAIR mismatch sign in 1342 adults (age range, 19–82 years) with low-grade gliomas. The sign was found to have a pooled sensitivity of 40% and pooled specificity of 100% for *IDH*-mutant, 1p/19q noncodeleted low-grade gliomas. While the sign has been established in the adult neuroradiology literature, to our knowledge, its significance has never been assessed in a pediatric brain tumor cohort, likely due to greater diversity of histopathology, imaging morphology, and tumor location of pediatric gliomas compared with adult *IDH*-mutant, 1p/19q noncodeleted low-grade gliomas reported by Patel et al.<sup>7</sup>

The mismatch sign is less frequently encountered in the pediatric age group. However, there is anecdotal evidence of a false-positive T2-FLAIR mismatch sign in children. A prior report by Johnson et al<sup>8</sup> mentioned a false-positive T2-FLAIR mismatch sign in the following: 1) a pilomyxoid astrocytoma in a 2-year-old child, 2) a non-neoplastic lesion (heterotopic gray matter) in a 12-year-old child, 3) a H3K27M-mutant midline glioma in a 14-year-old adolescent, and 4) a low-grade astrocytoma harboring *MYB* rearrangement in an 18-year-old individual. In addition, Kalelioglu et al<sup>12</sup> reported the T2-FLAIR mismatch sign in 1 of 2 pediatric-type diffuse low-grade gliomas with a *MYB/MYBL1* alteration. In our cohort of 352 pLGGs, we found 25 tumors with a T2-FLAIR mismatch (7.1%). This finding raises the question of the significance of the sign in the pediatric population. Unlike Johnson et al, we did not find the sign in pilomyxoid astrocytomas, but we observed the T2-FLAIR mismatch sign in 1 of 5 pLGGs with *MYB* and 3 of 4 pLGGs with a *MYBL1* rearrangement. *MYB* and *MYBL1* serve as transcriptional regulators important for cell proliferation and differentiation.<sup>1</sup> They are hypothesized to reflect a single tumor entity<sup>13</sup> and represent a distinct group within the pediatric-type diffuse low-grade gliomas in the 2021 WHO Classification of Tumors of the Central Nervous System.<sup>3</sup> Furthermore, the T2-FLAIR mismatch sign was present in 2 of 7 *FGFR1-TKDD* pLGGs (28.6%) and 2 of 6 *FGFR1-TACC1* fusion pLGGs (33.3%), which represented 2 diffuse astrocytomas and 2 low-grade astrocytomas histopathologically.

Other rare pLGG subtypes demonstrating the T2-FLAIR mismatch sign included the following molecular markers: *FGFR4* alteration (DNET), *GOPC-ROS1* fusion (pilocytic astrocytoma), *MET* N375S alteration (DNET), *IDH1* mutation, *MYB-QKI* fusion, and *PDGFB-LRP1* fusion (all low-grade astrocytomas). Regarding the commonly encountered histopathologic tumor types in pLGG, only 1 of 151 pilocytic astrocytomas (0.7%), 8 of 66 low-grade astrocytomas (12.1%), and none of 43 gangliogliomas demonstrated the T2-FLAIR mismatch sign. Instead, rarer histopathologies were enriched when encountering the T2-FLAIR mismatch sign, including 9 of 24 DNETs (37.5%), 5 of 22 diffuse astrocytomas (22.7%), 1 of 5 glioneuronal tumors (20%), and 1 of 5 angiocentric gliomas (20%). The rarity of the T2-FLAIR mismatch sign in common histologic tumor and molecular subtypes of pLGG suggests its potential as a diagnostic indicator for uncommon pLGG types.

Prior reports on *IDH*-mutant, 1p/19q noncodeleted low-grade gliomas in adults have demonstrated a strong association between the T2-FLAIR mismatch sign and intratumoral microcystic components.<sup>7,14–16</sup> This association can likely be attributed to the very long T1- and T2-relaxation times, which are the underlying MR imaging signal characteristics of the mismatched area.<sup>17</sup> Of our 25 pLGGs with T2-FLAIR mismatch, 9 were DNETs, a tumor entity known to demonstrate a microcystic pattern histologically.<sup>18</sup> It is difficult to say whether the microcystic pattern is related to the presence of the sign in other cases of our cohort, including low-grade, diffuse, and pilocytic astrocytomas and glioneuronal and angiocentric gliomas. The answer would require a histopathologic analysis of these cases beyond the scope of this study. While the underlying histopathologic characteristics of the T2-FLAIR mismatch sign in rare pLGG remain to be elucidated, we did not find the T2-FLAIR mismatch in the 2 most common types of molecular alterations of pLGG, *KIAA1549-BRAF* fusion and *BRAF* p.V600E mutation.

Several limitations need to be considered when interpreting the results of our study. First, 2 expert readers subjectively assessed the MR images in consensus, blinded to the molecular marker. Second, there were relatively few pLGGs with rare molecular markers in our sample. Consequently, the significance of the T2-FLAIR mismatch sign in *GOPC-ROS1*, *IDH1*, *MET* N375S, *MYB-QKI*, and *PDGFB-LRP1* requires further clarification. Third, 56 tumors had incomplete test panels. Of these, 11 demonstrated the T2-FLAIR mismatch sign. While it would be interesting to know whether there are rare pLGG molecular subtypes present in this group, we were able to exclude the most common molecular alterations (*KIAA1549-BRAF* fusion and *BRAF* p.V600E mutation) in addition to the *FGFR1-N546K* alteration and the mutation of *IDH1*. Additional molecular analysis in the future may help elucidate the significance of the sign in rare subtypes of pLGG.

## CONCLUSIONS

In a large institutional cohort of patients with pLGG, we assessed the occurrence of the T2-FLAIR mismatch sign and its relation to histopathologic and molecular markers. We found that the T2-FLAIR mismatch sign is absent in *KIAA1549-BRAF*-fused and *BRAF* p.V600E-mutated pLGG. The sign was encountered in rare molecular markers of pLGG, including *MYB/MYBL1*, *MYB-QKI*, *FGFR1-TKDD*, *FGFR1-TACC1*, *FGFR4*, *IDH1*, *GOPC-ROS1*, *MET* N375S, and *PDGFB-LRP1*. Due to the rarity of the T2-FLAIR mismatch sign in common histologic tumor types and molecular subtypes of pLGG, it could serve as a diagnostic marker for infrequent pLGG types.

Disclosure forms provided by the authors are available with the full text and PDF of this article at [www.ajnr.org](http://www.ajnr.org).

## REFERENCES

1. Ryall S, Tabori U, Hawkins C. Pediatric low-grade glioma in the era of molecular diagnostics. *Acta Neuropathol Commun* 2020;8:30 [CrossRef Medline](#)
2. Ostrom QT, Gittleman H, Liao P, et al. CBTRUS Statistical Report: Primary brain and other central nervous system tumors diagnosed

- in the United States in 2010-2014. *Neuro Oncol* 2017;19:v1-88 [CrossRef Medline](#)
3. Louis DN, Perry A, Wesseling P, et al. The 2021 WHO Classification of Tumors of the Central Nervous System: a summary. *Neuro Oncol* 2021;23:1231-51 [CrossRef Medline](#)
  4. Ryall S, Zapotocky M, Fukuoka K, et al. Integrated molecular and clinical analysis of 1,000 pediatric low-grade gliomas. *Cancer Cell* 2020;37:569-83.e5 [CrossRef Medline](#)
  5. Packer RJ, Pfister S, Bouffet E, et al. Pediatric low-grade gliomas: implications of the biologic era. *Neuro Oncol* 2017;19:750-61 [CrossRef Medline](#)
  6. AlRayahi J, Zapotocky M, Ramaswamy V, et al. Pediatric brain tumor genetics: what radiologists need to know. *Radiographics* 2018;38:2102-22 [CrossRef Medline](#)
  7. Patel SH, Poisson LM, Brat DJ, et al. T2-FLAIR mismatch, an imaging biomarker for IDH and 1p/19q status in lower-grade gliomas: a TCGA/TCIA project. *Clin Cancer Res* 2017;23:6078-85 [CrossRef Medline](#)
  8. Johnson DR, Kaufmann TJ, Patel SH, et al. There is an exception to every rule-T2-FLAIR mismatch sign in gliomas. *Neuroradiology* 2019;61:225-27 [CrossRef Medline](#)
  9. Louis DN, Perry A, Reifenberger G, et al. The 2016 World Health Organization Classification of Tumors of the Central Nervous System: a summary. *Acta Neuropathol* 2016;131:803-20 [CrossRef Medline](#)
  10. Jain R, Johnson DR, Patel SH, et al. "Real world" use of a highly reliable imaging sign: "T2-FLAIR mismatch" for identification of IDH mutant astrocytomas. *Neuro Oncol* 2020;22:936-43 [CrossRef Medline](#)
  11. Do YA, Cho SJ, Choi BS, et al. Predictive accuracy of T2-FLAIR mismatch sign for the IDH-mutant, 1p/19q noncodeleted low-grade glioma: an updated systematic review and meta-analysis. *Neurooncol Adv* 2022;4:vda010 [CrossRef Medline](#)
  12. Kalelioglu T, Rama B, Cho BB, et al. Pediatric-type diffuse low-grade glioma with MYB/MYBL1 alteration: report of 2 cases. *Neuroradiol J* 2023;36:232-35 [CrossRef Medline](#)
  13. Chiang J, Harreld JH, Tinkle CL, et al. A single-center study of the clinicopathologic correlates of gliomas with a MYB or MYBL1 alteration. *Acta Neuropathol* 2019;138:1091-92 [CrossRef Medline](#)
  14. Tay KL, Tsui A, Phal PM, et al. MR imaging characteristics of protoplasmic astrocytomas. *Neuroradiology* 2011;53:405-11 [CrossRef Medline](#)
  15. Deguchi S, Oishi T, Mitsuya K, et al. Clinicopathological analysis of T2-FLAIR mismatch sign in lower-grade gliomas. *Sci Rep* 2020;10:10113 [CrossRef Medline](#)
  16. Fujita Y, Nagashima H, Tanaka K, et al. The histopathologic and radiologic features of T2-FLAIR mismatch sign in IDH-mutant 1p/19q non-codeleted astrocytomas. *World Neurosurg* 2021;149:e253-60 [CrossRef Medline](#)
  17. Kinoshita M, Uchikoshi M, Sakai M, et al. T<sub>2</sub>-FLAIR mismatch sign is caused by long T<sub>1</sub> and T<sub>2</sub> of IDH-mutant, 1p19q non-codeleted astrocytoma. *Magn Reson Med Sci* 2021;20:119-23 [CrossRef Medline](#)
  18. Suh YL. Dysembryoplastic neuroepithelial tumors. *J Pathol Transl Med* 2015;49:438-49 [CrossRef Medline](#)