



Discover Generics

Cost-Effective CT & MRI Contrast Agents



FRESENIUS
KABI

WATCH VIDEO

AJNR

Sacral CSF-Venous Fistulas and Potential Imaging Techniques

I.T. Mark, P.P. Morris, W. Brinjikji, A.A. Madhavan, J.K. Cutsforth-Gregory and J.T. Verdoorn

AJNR Am J Neuroradiol 2022, 43 (12) 1824-1826

doi: <https://doi.org/10.3174/ajnr.A7699>

<http://www.ajnr.org/content/43/12/1824>

This information is current as
of June 4, 2025.

Sacral CSF-Venous Fistulas and Potential Imaging Techniques

 I.T. Mark,  P.P. Morris,  W. Brinjikji,  A.A. Madhavan,  J.K. Cutsforth-Gregory, and  J.T. Verdoorn

ABSTRACT

SUMMARY: This is the first study to describe CSF-venous fistulas involving the sacrum, a location that may be underrecognized on the basis of current imaging techniques. We describe a delayed decubitus flat CT myelogram technique that may be useful to identify sacral CSF-venous fistulas.

ABBREVIATIONS: CTM = CT myelography; CVF = CSF-venous fistula; DAVF = dural arteriovenous fistula; DECT = dual-energy CT; DSM = digital subtraction myelography

Spontaneous intracranial hypotension can cause debilitating headaches and other symptoms. One cause, which likely represents at least 25% of cases of spontaneous intracranial hypotension, is a CSF-venous fistula (CVF).¹ CVFs are occult on conventional MR imaging and CT. Diagnosis thus depends on myelography, most commonly with lateral decubitus digital subtraction myelography (DSM) and dynamic CT myelography (CTM).^{2,3}

CVFs are usually found in the thoracic spine, less often in the lower cervical or upper lumbar spine,⁴ but not previously reported in the sacrum. We present 2 patients with sacral CVFs. Our aim was to promote awareness of sacral CVFs and present a potential myelographic technique to aid in their discovery.

Cases

Two cases of sacral CVF and the myelographic techniques used to find them are described below.

Patient 1

A 56-year-old woman presented with 2 years of orthostatic headaches, brain fog, and nausea. Brain MR imaging demonstrated effacement of the suprasellar cistern and narrowing of the

mamillopontine distance (Bern score = 3/9).⁵ Spine MR imaging did not demonstrate extradural fluid. Lateral decubitus DSM showed a possible left T5 CVF, and she underwent a left T5 transvenous catheter embolization, after which symptoms improved but did not resolve.

Six months after her initial DSM, repeat left lateral decubitus DSM was performed. The thecal sac was accessed at L2–L3, and 11 mL of Omnipaque 300 (GE Healthcare) was injected with the patient in the Trendelenburg position. The DSM inferior FOV extended to the needle-access site. Following the DSM, per our standard technique, the patient was kept in the left lateral decubitus position and imaged with dual-energy CT (DECT) approximately 30 minutes after the DSM. The CT included nearly the entire sacrum in the FOV (below the S3 neural foramen). DECT images revealed a CVF originating from a left S2 diverticulum that extended to the left internal iliac vein (Fig 1), outside the DSM FOV. She was treated with a transvenous catheter embolization. One month later the patient had modest improvement in headache and brain fog, and resolution of the nausea.

Patient 2

A 48-year-old man presented with 2 years of nonorthostatic headaches, which were exacerbated by straining. Brain MR imaging was highly suggestive of a CSF leak (Bern score = 8/9). Spine MR imaging did not show extradural fluid. A nuclear medicine cisternogram showed radiotracer accumulation in the kidneys and bladder at 1 hour and failure of radiotracer ascent at 6 hours, suggestive of a CSF leak.

Conventional CTM was performed and read as having negative findings. Further work-up continued with a right-side-down DSM, with imaging down to the lumbar puncture level at L3–L4. A right lateral decubitus DECT extending to the sacrum was

Received September 8, 2022; accepted after revision October 5.

From the Departments of Radiology (I.T.M., P.P.M., W.B., A.A.M., J.T.V.) and Neurology (J.K.C.-G.), Mayo Clinic, Rochester, Minnesota.

Each of the authors (I.T.M., P.P.M., W.B., A.A.M., J.K.C.-G., J.T.V.) contributed to all categories established by the International Committee of Medical Journal Editors including the following: conception and design, or acquisition of data, or analysis and interpretation of data; drafting the article or revising it critically for important intellectual content; final approval of the version to be published; and agreement to be accountable for all aspects of the work in ensuring that questions related to the accuracy or integrity of any part of the work are appropriately investigated and resolved.

Please address correspondence to Ian Mark, MD, Department of Radiology, Mayo Building, 3-72W, Rochester, MN 55905; e-mail: Mark.Ian@mayo.edu; @iantmark
<http://dx.doi.org/10.3174/ajnr.A7699>

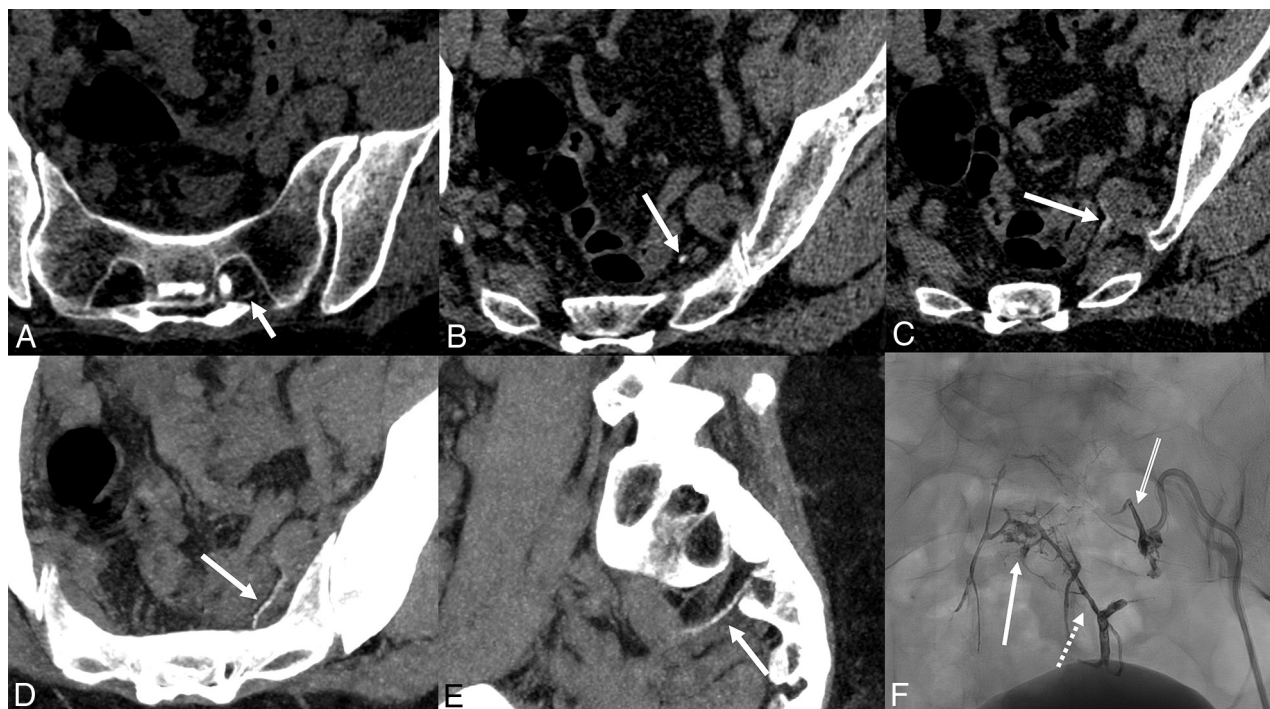

FIG 1. Left S2 CVF in patient 1. A–C, Axial images from a flat left-side-down CTM after DSM show a CVF (arrows) that arises from a left S2 nerve sheath diverticulum that empties into the left internal iliac vein. These images were reconstructed into 0.625-mm-thick slices from the 50-keV monoenergetic reconstructions from DECT. D and E, Multiplanar reformatted images from the CTM highlight the CVF (arrows). F, Postprocedural frontal projection image from transvenous catheter Onyx (Covidien) embolization of the CVF. The left S2 vein (double-line arrow), left S3 vein (broken arrow), and the pelvic epidural venous plexus (solid arrow) are opacified.

performed approximately 20 minutes after the DSM. On the inferior-most images, a CVF arising from a right S3 diverticulum was partially visualized, which, in retrospect, could be seen on the conventional CTM. A repeat DSM was performed several days later, this time with the patient in the reverse Trendelenburg position to opacify the CVF (Fig 2). Immediate post-DSM DECT in a flat right lateral decubitus position depicted the CVF as it arose from a complex multilobulated right S3 diverticulum and connected to the ipsilateral internal iliac vein. The patient encounter occurred before the advent of transvenous embolization, and the patient underwent a CT-guided epidural blood patch with fibrin glue. The patient had symptom relief for 1.5 years and is currently undergoing evaluation for a recurrent CSF leak.

DISCUSSION

We present our technique to identify sacral CVFs in 2 patients involving reverse Trendelenburg positioning during DSM and delayed decubitus CTM including the sacrum. To our knowledge, these are the first reported cases of sacral CVF. This report is important because the sacrum has not previously been described as a location for CVF and is not well-evaluated by current dynamic myelographic techniques, which typically involve a lumbar puncture with imaging superiorly from that site as contrast flows superiorly with the patient in the Trendelenburg position.

Prior work, including a systematic review, described most CVFs in the thoracic spine, with rare occurrence in the cervical or upper lumbar spine, without prior description of a sacral CVF.^{4,6–8}

To perform decubitus myelography, either DSM or CTM, contrast is injected via lumbar puncture and the patient must be in the Trendelenburg position for cranial flow of contrast. Therefore, this technique draws contrast away from the sacrum and negates the possibility of detecting a sacral CVF. Our technique involves a post-DSM CT in the flat (non-Trendelenburg) lateral decubitus position, allowing contrast to redistribute caudally and thereby opacify the sacral CSF, and could be performed after DSM or dynamic CTM.

While dynamic myelography is the preferred work-up for a CVF, CVF can occasionally be detected on conventional (nondynamic) myelograms.⁹ In retrospect, the sacral CVF was present on the conventional myelogram of patient 2. Important features of imaging for sacral CVF include patient positioning that allows contrast to distribute caudally to the sacrum and imaging through the inferior aspect of the sacrum. An additional option to interrogate the sacrum includes injecting contrast with the patient in the reverse Trendelenburg position during lateral decubitus DSM, as in patient 2.

Despite a clear thoracic predominance of CVF, the sacrum may be an underrecognized site of CVF, like what has been suggested with a dural arteriovenous fistula (DAVF). The sacrum has traditionally been thought to account for only 5%–10% of DAVFs, but Gioppo et al¹⁰ reported a sacral DAVF in 14% of cases. Lack of awareness may similarly cause sacral CVFs to be underrecognized.

Our standard practice includes lateral decubitus DSM from the cervicothoracic junction to the needle-insertion site in the lumbar

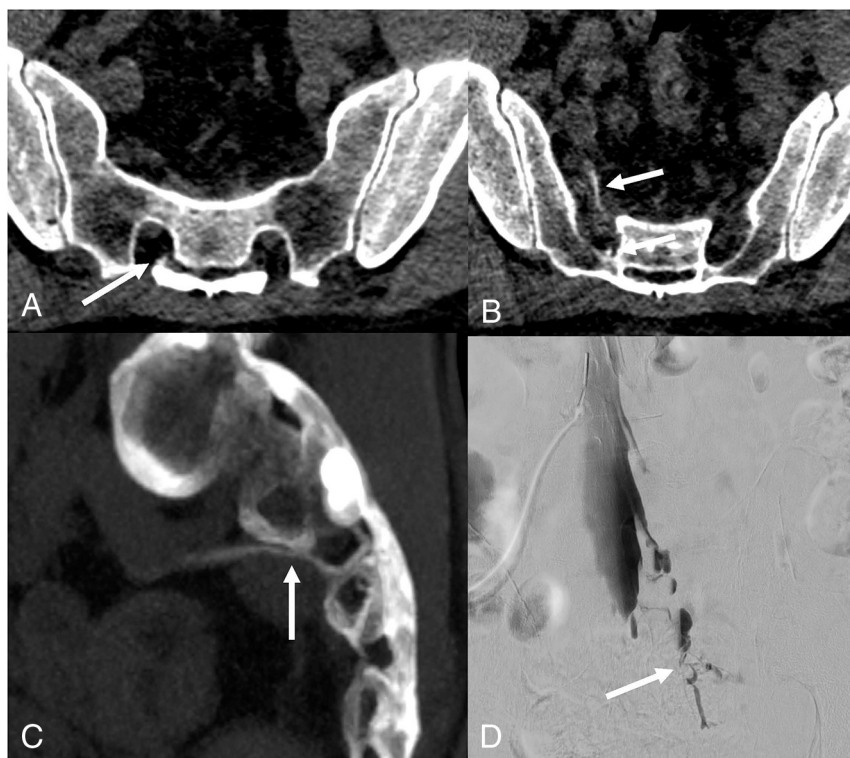


FIG 2. Right S3 CVF in patient 2. A and B, Axial images from a flat right-side-down CTM after DSM follow a CVF (arrows) that arises from a right S3 nerve sheath diverticulum and empties into the right internal iliac vein. These images were reconstructed into 0.625-mm-thick slices from the monoenergetic reconstructions from DECT. C, Reformatted image from the same examination better demonstrates the entire CVF (arrow). D, Right-side-down DSM frontal image with the patient in reverse Trendelenburg position shows the CVF (arrow).

spine. We then perform a post-DSM lateral decubitus DECT of the entire spine, including the inferior aspect of the sacrum. This series is performed during 2 days, with the right side on day 1 and the left side on day 2. A nuclear medicine cisternogram is performed in cases of “low probability” Bern scores⁵ on brain MR imaging.

This study is limited by its small size. Nonetheless, these 2 cases highlight the sacrum as a potential location of a CVF that is typically not investigated during a CVF work-up. A sacral CVF may account for an undiagnosed source of CSF leak in some patients who have undergone extensive work-up, and various technical modifications that we have described may be needed for its identification.

CONCLUSIONS

We describe 2 modifications to dynamic myelography that may aid in the detection of sacral CVFs, namely a delayed flat lateral decubitus DECT imaging inferiorly through the sacrum and

reverse Trendelenburg positioning during DSM while imaging the sacrum. These were instrumental in identifying sacral CVFs.

Disclosure forms provided by the authors are available with the full text and PDF of this article at www.ajnr.org.

REFERENCES

1. Schievink WI, Moser FG, Maya MM. CSF-venous fistula in spontaneous intracranial hypotension. *Neurology* 2014;83:472–73 [CrossRef Medline](#)
2. Kim DK, Brinjikji W, Morris PP, et al. Lateral decubitus digital subtraction myelography: tips, tricks, and pitfalls. *AJNR Am J Neuroradiol* 2020;41:21–28 [CrossRef Medline](#)
3. Kranz PG, Amrhein TJ, Gray L. CSF venous fistulas in spontaneous intracranial hypotension: imaging characteristics on dynamic and CT myelography. *AJR Am J Roentgenol* 2017;209:1360–66 [CrossRef Medline](#)
4. Shlobin NA, Shah VN, Chin CT, et al. Cerebrospinal fluid-venous fistulas: a systematic review and examination of individual patient data. *Neurosurgery* 2021;88:931–41 [CrossRef Medline](#)
5. Dobrocky T, Grunder L, Breiding PS, et al. Assessing spinal cerebrospinal fluid leaks in spontaneous intracranial hypotension with a scoring system based on brain magnetic resonance imaging findings. *JAMA Neurol* 2019;76:580–87 [CrossRef Medline](#)
6. Kim DK, Carr CM, Benson JC, et al. Diagnostic yield of lateral decubitus digital subtraction myelogram stratified by brain MRI findings. *Neurology* 2021;96:e1312–18 [CrossRef Medline](#)
7. Mamlouk MD, Ochi RP, Jun P, et al. Decubitus CT myelography for CSF-venous fistulas: a procedural approach. *AJNR Am J Neuroradiol* 2021;42:32–36 [CrossRef Medline](#)
8. Schievink WI, Moser FG, Maya MM, et al. Digital subtraction myelography for the identification of spontaneous spinal CSF-venous fistulas. *J Neurosurg Spine* 2016;24:960–64 [CrossRef Medline](#)
9. Clark MS, Diehn FE, Verdoorn JT, et al. Prevalence of hyperdense paraspinal vein sign in patients with spontaneous intracranial hypotension without dural CSF leak on standard CT myelography. *Diagn Interv Radiol* 2018;24:54–59 [CrossRef Medline](#)
10. Gioppo A, Faragò G, Giannitto C, et al. Sacral dural arteriovenous fistulas: a diagnostic and therapeutic challenge: single-centre experience of 13 cases and review of the literature. *J Neurointerv Surg* 2018;10:415–21 [CrossRef Medline](#)