



Providing Choice & Value

Generic CT and MRI Contrast Agents



CONTACT REP

AJNR

This information is current as
of July 24, 2025.

Involvement of the Thalamus, Hippocampus, and Brainstem in Hypsarrhythmia of West Syndrome: Simultaneous Recordings of Electroencephalography and fMRI Study

Y. Maki, J. Natsume, Y. Ito, Y. Okai, E. Bagarinao, H.
Yamamoto, S. Ogaya, T. Takeuchi, T. Fukasawa, F.
Sawamura, T. Mitsumatsu, S. Maesawa, R. Saito, Y.
Takahashi and H. Kidokoro

AJNR Am J Neuroradiol 2022, 43 (10) 1502-1507

doi: <https://doi.org/10.3174/ajnr.A7646>

<http://www.ajnr.org/content/43/10/1502>

Involvement of the Thalamus, Hippocampus, and Brainstem in Hypsarrhythmia of West Syndrome: Simultaneous Recordings of Electroencephalography and fMRI Study

Y. Maki, J. Natsume, Y. Ito, Y. Okai, E. Bagarinao, H. Yamamoto, S. Ogaya, T. Takeuchi, T. Fukasawa, F. Sawamura, T. Mitsumatsu, S. Maesawa, R. Saito, Y. Takahashi, and H. Kidokoro



ABSTRACT

BACKGROUND AND PURPOSE: West syndrome is a developmental and epileptic encephalopathy characterized by epileptic spasms, neurodevelopmental regression, and a specific EEG pattern called hypsarrhythmia. Our aim was to investigate the brain activities related to hypsarrhythmia at onset and focal epileptiform discharges in the remote period in children with West syndrome using simultaneous electroencephalography and fMRI recordings.

MATERIALS AND METHODS: Fourteen children with West syndrome underwent simultaneous electroencephalography and fMRI at the onset of West syndrome. Statistically significant blood oxygen level–dependent responses related to hypsarrhythmia were analyzed using an event-related design of 4 hemodynamic response functions with peaks at 3, 5, 7, and 9 seconds after the onset of each event. Six of 14 children had focal epileptiform discharges after treatment and underwent simultaneous electroencephalography and fMRI from 12 to 25 months of age.

RESULTS: At onset, positive blood oxygen level–dependent responses were seen in the brainstem (14/14 patients), thalami (13/14), basal ganglia (13/14), and hippocampi (13/14), in addition to multiple cerebral cortices. Group analysis using hemodynamic response functions with peaks at 3, 5, and 7 seconds showed positive blood oxygen level–dependent responses in the brainstem, thalamus, and hippocampus, while positive blood oxygen level–dependent responses in multiple cerebral cortices were seen using hemodynamic response functions with peaks at 5 and 7 seconds. In the remote period, 3 of 6 children had focal epileptiform discharge–related positive blood oxygen level–dependent responses in the thalamus, hippocampus, and brainstem.

CONCLUSIONS: Positive blood oxygen level–dependent responses with hypsarrhythmia appeared in the brainstem, thalamus, and hippocampus on earlier hemodynamic response functions than the cerebral cortices, suggesting the propagation of epileptogenic activities from the deep brain structures to the neocortices. Activation of the hippocampus, thalamus, and brainstem was still seen in half of the patients with focal epileptiform discharges after adrenocorticotrophic hormone therapy.

ABBREVIATIONS: ACTH = adrenocorticotrophic hormone; BOLD = blood oxygen level–dependent; ED = epileptiform discharge; EEG–fMRI = simultaneous recordings of electroencephalography and fMRI; HRF = hemodynamic response function; MNI = Montreal Neurological Institute; WS = West syndrome

West syndrome (WS) is a developmental and epileptic encephalopathy of infancy characterized by epileptic spasms, neurodevelopmental regression, and a specific electroencephalography (EEG) pattern called hypsarrhythmia.¹ Hypsarrhythmia consists of high-voltage slow waves and multifocal spikes without interhemispheric and intrahemispheric synchrony.^{2,3} In the

concept of developmental and epileptic encephalopathy, the abundant epileptiform activity interferes with psychomotor development, resulting in cognitive slowing and regression.⁴ In that sense, it is important to know which brain structures and networks are involved in the form of hypsarrhythmia to understand the mechanism of WS leading to cognitive slowing and regression.

Previous neuroimaging studies have implied the involvement of widespread cortical and subcortical structures in the

Received February 28, 2022; accepted after revision July 27.

From the Departments of Pediatrics (Y.M., J.N., Y.I., Y.O., H.Y., F.S., T.M., Y.T., H.K.), Developmental Disability Medicine (J.N.), and Neurosurgery (S.M., R.S.), Nagoya University Graduate School of Medicine, Nagoya, Japan; Brain and Mind Research Center (J.N., Y.I., Y.O., E.B., H.Y., S.M., H.K.), Nagoya University, Nagoya, Japan; Department of Pediatrics (Y.I.), Aichi Prefectural Mikawa Aotiori Medical and Rehabilitation Center, Okazaki, Japan; Department of Pediatric Neurology (Y.O.), Toyota Municipal Child Development Center, Toyota, Japan; Department of Pediatric Neurology (S.O.), Aichi Developmental Disability Center Central Hospital, Kasugai, Japan; Department of Pediatrics (T.T.), Japanese Red Cross Nagoya First Hospital, Nagoya, Japan; and Department of Pediatrics (T.F.), Anjo Kosei Hospital, Anjo, Japan.

This work was supported by JSPS Kakenhi grant No. JP16K09987.

Please address correspondence to Jun Natsume, MD, PhD, Department of Pediatrics, Nagoya University Graduate School of Medicine, 65 Tsurumai-cho, Showa-ku, Nagoya, 466-8550, Japan; e-mail: junnatsumi@med.nagoya-u.ac.jp

Indicates open access to non-subscribers at www.ajnr.org

Indicates article with online supplemental data.

<http://dx.doi.org/10.3174/ajnr.A7646>

pathophysiology of WS. FDG-PET shows hypermetabolism of the lenticular nuclei and brainstem.^{5,6} DTI has shown restricted diffusion in the brainstem at the onset of WS.⁷ However, because of the low temporal resolution of PET and DTI, it is difficult to assess the relationship of hypermetabolism and restricted diffusion with hypsarrhythmia directly.

Simultaneous recording of EEG and fMRI (EEG-fMRI) is a technique for evaluating hemodynamic changes by blood oxygenation level-dependent (BOLD) signals related to EEG activities. A previous EEG-fMRI study of hypsarrhythmia in children with WS showed a positive correlation between the Δ power of the occipital slow wave and a positive BOLD response in the brainstem and putamen.⁸ EEG-fMRI is a promising tool to identify the brain structures involved in hypsarrhythmia and to clarify the role of these structures in developmental and epileptic encephalopathies.

In the present study, EEG-fMRI was performed in patients with WS to evaluate the brain structures related to hypsarrhythmia. An event-related design of 4 hemodynamic response functions (HRFs) that peak at 3, 5, 7, and 9 seconds after the onset of clusters of the epileptiform discharge was used to assess the temporospatial propagation of the epileptiform activities. Additionally, EEG-fMRI was re-evaluated in the remote period after adrenocorticotrophic hormone (ACTH) therapy in patients who had remaining epileptiform discharges (EDs), and the results were compared with seizure outcomes.

MATERIALS AND METHODS

Ethics Approval

The present study was approved by the research ethics committee of Nagoya University Graduate School of Medicine. Written, informed consent was obtained from the children's caregivers before participation.

Patients and Clinical Data

Children with new-onset WS who were referred to Nagoya University Hospital between January 2016 and December 2021 were recruited. The diagnosis of WS was made from epileptic spasms in clusters confirmed by video-EEG recording and interictal EEG findings of hypsarrhythmia. The search for the etiology included laboratory tests and MR imaging, and the etiology of WS was regarded as unknown in children without abnormal findings on these examinations. Children were treated according to the following protocol: First, oral antiepileptic drugs were administered for at least 1 week, or ACTH was started. When spasms were not controlled by the oral antiepileptic drug, ACTH therapy was initiated immediately. Intramuscular injection of ACTH was administered for 2–4 weeks, followed by alternate-day administration for 1 week. The effectiveness was evaluated on the basis of the frequency of spasms and interictal EEG findings.

EEG-fMRI Acquisition

Patients underwent EEG-fMRI before the initiation of ACTH therapy. In patients who had remaining focal EDs after ACTH therapy, another EEG-fMRI scan was performed.

MR images were obtained using a Magnetom Verio (Siemens) 3T scanner with a 32-channel head coil using the same protocol as in previous studies.⁹ fMRIs were recorded in a single, continuous

session for 15 minutes using a T2-weighted gradient-echo echoplanar imaging sequence with the following imaging parameters: TR, 2.5 seconds; TE, 30 ms; FOV, 192 mm; matrix dimension, 64 × 64; 39 transverse slices with a 0.5-mm interslice interval and 3-mm thickness; flip angle, 80°; and a total of 360 volumes. EEGs and electrocardiograms were recorded simultaneously during fMRI scans using an MR imaging-compatible system (GES 400 MR, Electrical Geodesics, EGI; <https://www.egi.com/>). A 32-channel EEG cap was worn by the child throughout the scan and was connected to a combined digitizer-amplifier system. Data from the amplifier sampled at 1 kHz were continuously retrieved. Children were sedated in a drug-induced sleep condition with triclofos sodium, 80 mg/kg of body weight.

Image Preprocessing

Anatomic T1-weighted images and fMRIs were preprocessed using SPM12 software (<http://www.fil.ion.ucl.ac.uk/spm/software/spm12>) running on Matlab (MathWorks). For fMRI, the first 5 images were discarded to remove signal inhomogeneity. The remaining 355 images were corrected for temporal differences in section acquisitions, resampled relative to the middle image (20th of the 39 transverse slices), and corrected for head motion. The fMRI images were normalized to the Montreal Neurological Institute (MNI) space and smoothed with an 8-mm full width at half maximum Gaussian kernel.

EEG Preprocessing

Raw EEG data were preprocessed using EGI's Net Station software (<https://www.egi.com/clinical-division/net-station>). Gradient artifacts were removed using the template subtraction method, and ballistocardiogram artifacts were also removed using principal component analysis.^{10,11} The cleaned EEG was band-pass filtered within the frequency range from 0.1 to 100 Hz. Two epileptologists (Y.M. and Y.I.) independently marked the onset and end of intermittent hypsarrhythmia bursts during sleep for EEGs at WS onset and the onset of EDs for EEGs in the remote period. Each hypsarrhythmia burst was regarded as an event with duration, similar to that in a previous approach used in ictal EEG-fMRI analysis in childhood absence epilepsy or Lennox-Gastaut syndrome.^{12,13} The events for which 2 epileptologists obtained consensus were used for the subsequent analysis.

Individual-Level fMRI Analysis

fMRI data were analyzed using SPM12 software. Identified hypsarrhythmia bursts or ED onsets were used to generate a series of bursts or spikes, which were then convolved with HRFs and used in the statistical analyses of preprocessed fMRI data using an FSL General Linear Model approach (<http://fsl.fmrib.ox.ac.uk/fsl/fslwiki/GLM>). Four different HRFs that peaked at 3, 5, 7, and 9 seconds (P3, P5, P7, and P9) after the onset of each event were used for the analyses, as described previously.¹³ One-tailed *t* tests were applied to test hypsarrhythmia bursts or ED-related BOLD signal changes. A significant BOLD response was defined as at least 5 contiguous voxels above a *t* value of 3.1, which is equivalent to a *P* value < .01.¹⁴ All significant clusters obtained from 4 HRFs using this significance level were also regarded as significant for total individual-level analysis, and the results were superimposed on T1-weighted images of

each child. To combine the images of multiple HRFs, we followed the method that Gotman Lab described (<https://www.mcgill.ca/gotman-lab/research/combined-eeg-fmri-recordings/creating-combined-hrf-tmap>). A new image file was created using the *t*-maps for the individual models as the template. Each voxel was independently examined, and the value of the *t*-map with the highest absolute value was written into that voxel. Anatomic segmentation was according to Automated Anatomical Labeling (<https://www.gin.cnrs.fr/en/tools/aal/>).¹⁵

Group-Level fMRI Analysis

Group-level analysis was performed for individual results at the onset of WS. Analysis was first performed for each HRF (P3, P5, P7, and P9) using the SPM12 software. Age at scanning was used as a covariate. The significance level was set at $P < .01$ for multiple comparisons using family-wise error cluster-level correction with a cluster-forming threshold of $P = .001$. All significant clusters obtained from 4 HRFs using this significance level were also regarded as significant for the total group-level analysis, similar to findings in a previous EEG-fMRI study that used a time-shift model of a single HRF.¹⁶ The results were superimposed on the common T1-weighted image in MNI space.

RESULTS

Patient Demographics

Fourteen children with new-onset WS were included in the study (Online Supplemental Data). The median age at the onset of WS was 5 months (range, 3–10 months). Two children (patients 5 and 6) had tuberous sclerosis complex and focal motor seizures before the onset of spasms. In the remaining 12 children, the etiology of WS was unknown at the onset. Patient 7 had delayed myelination and WM volume loss on MR imaging, but gene panel exome sequencing of developmental and epileptic encephalopathies did not show causative abnormalities.

In 5 patients, clonazepam, valproate, levetiracetam, topiramate, or vigabatrin was administered before ACTH therapy. In other patients, ACTH therapy was the first medication. After ACTH therapy, patients 5, 7, and 12 had epileptic spasms and patients 5 and 7 received another course of ACTH therapy. In the other 11 patients, spasms and hypsarrhythmia were resolved by a single course of ACTH therapy. Four patients (patients 1, 2, 3, and 5) experienced focal seizures during the follow-up period. Patients 1 and 3 had focal seizures 12 and 42 months after completing ACTH therapy, respectively. Patients 2 and 5 had onset of focal seizures within a month after completing ACTH therapy. Patient 2 underwent right temporal lobe resection at 23 months of age, and pathology showed focal cortical dysplasia type IIa.

Of the 8 patients who did not have focal EDs after ACTH therapy, 3 (patients 7, 12, and 14) had generalized EDs, relapse of seizures, and mild-to-severe developmental delays. In the other 5 patients who did not have focal or generalized EDs, 4 had normal psychomotor development and 1 (patient 10) had a mild delay of language development.

On EEG during the follow-up period, 6 of 14 patients (patients 1–6) had focal EDs after ACTH therapy. Patient 7 had frequent diffuse sharp-slow waves on interictal EEG. Patient 12 had multifocal EDs on interictal EEG.

BOLD Responses Related to Hypsarrhythmia at Onset of WS

The median interval between the onset of WS and the first EEG-fMRI scan was 10.5 days (range 3–112 days). In the patient who underwent EEG-fMRI 112 days after the onset of WS, the family did not recognize the spasms as epileptic seizures and the diagnosis of WS was delayed to 84 days after onset. This patient had a series of epileptic spasms and typical hypsarrhythmia at diagnosis and was included in the present study.

The median number of bursts of EDs in a 15-minute scan of each patient was 55 (range, 11–129). BOLD responses related to ED bursts of each patient are in seen in Fig 1A. In cerebral neocortices, all children showed multiple positive BOLD responses in the bilateral frontal, temporal, parietal, and occipital lobes, and the cingulate gyri. Positive BOLD responses in the bilateral insulae were also observed in all except 1 patient. Negative BOLD responses were observed in the frontal (12/14 patients), temporal (10/14), parietal (12/14), and occipital lobes (12/14) of the cerebral cortices, though the areas were smaller than those of positive BOLD responses. Regarding subcortical structures and the hippocampus, positive BOLD responses were observed in the brainstem (14/14 patients), thalami (13/14), and hippocampi (13/14). Positive BOLD responses in the brainstem were observed in the pons in 13 patients. Positive BOLD responses in the thalami were observed bilaterally in 12 patients and unilaterally in 1. Positive BOLD responses in the hippocampi were observed bilaterally in 11 patients and unilaterally in 1. Positive BOLD responses in the basal ganglia were observed in 8 patients. Negative BOLD responses were observed in the brainstem in 2 patients, the thalami in 3, and the hippocampi in 2. Negative BOLD responses in the basal ganglia were observed in 12 of 14 patients. The BOLD responses with maximum *t* values were positive BOLD responses in all children and were observed in the cerebral neocortex in 8 patients, in the pons in 3, the hippocampus in 1, the pulvinar in 1, and the posterior cingulate gyrus in 1.

The result of group-level analysis is shown in Fig 2. No clusters with significant negative BOLD responses were identified. Group analysis using a P3 HRF showed significant positive BOLD responses in the dorsal pons, midbrain, bilateral hippocampus, bilateral thalami, and bilateral opercula, whereas positive BOLD responses in the cerebral neocortex were scarce. P5 and P7 HRFs showed significant positive BOLD responses in the cerebral neocortex, pons, midbrain, bilateral thalami, and left hippocampus. The P9 HRF yielded scattered positive BOLD responses in the cerebral neocortex and positive BOLD responses in the bilateral thalami and hippocampi.

BOLD Responses Related to Focal EDs after ACTH Therapy

The median age at the second EEG-fMRI scan was 16 months (range, 12–25 months) in 6 patients (patients 1–6) with focal EDs after ACTH therapy. The median number of focal EDs during a 15-minute scan was 27 (range, 13–76). Four of the 6 patients with focal EDs after ACTH therapy had focal seizures.

BOLD responses related to focal EDs are described in the Online Supplemental Data and Fig 1B. Patients 1–3 showed positive BOLD responses in the brainstem, thalami, and hippocampi, in addition to the cerebral cortex; maximum *t* values

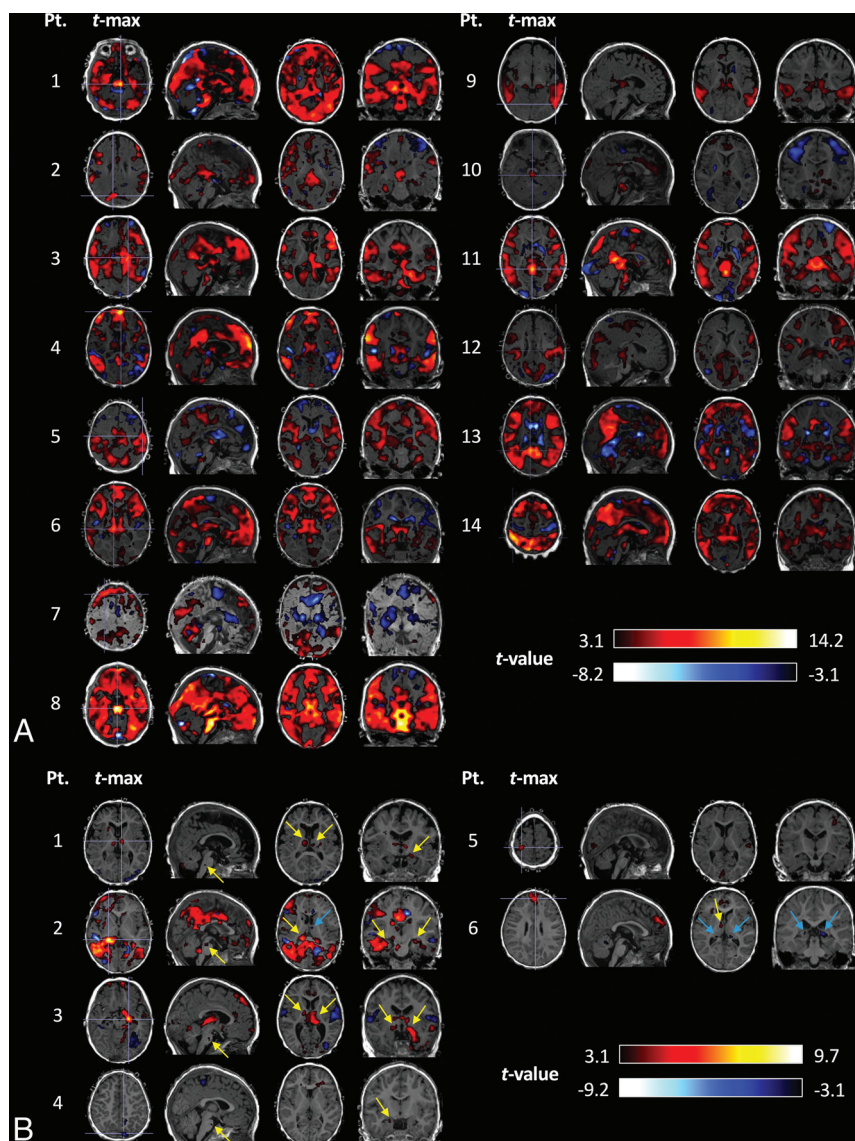


FIG 1. EEG-fMRI findings of all patients with WS. **A**, Combined *t*-maps of 4 HRFs on EEG-fMRI of all patients at the onset of WS. The first (leftmost) axial image of each patient shows the axial slice with the maximum *t* value. All children showed significant BOLD response in the brainstem, hippocampus, thalamus, and basal ganglia, as well as multiple cerebral neocortices. **B**, EEG-fMRI findings of 6 children who had focal epileptiform discharges in the remote period after ACTH therapy. Significant BOLD responses in the brainstem, thalamus, and hippocampus are shown by arrows on sagittal, axial, and coronal sections of each patient. Positive BOLD responses are indicated by yellow arrows, and negative BOLD responses are indicated by blue arrows. The MNI coordinates of maximum *t* values are described in the Online Supplemental Data. In both **A** and **B**, all significant BOLD responses from 4 HRFs are shown. Pt. indicates patient; t-max, time-to-maximum.

were observed in the hippocampus or thalamus. Patient 4 showed positive BOLD responses in the brainstem and right hippocampus. Of patients with tuberous sclerosis complex, patient 5 showed positive BOLD responses only in the cerebral cortices, and patient 6 showed significant BOLD responses in the thalamus and hippocampus, as well as in the cerebral cortices. The areas with positive BOLD responses in the cerebral cortices decreased in all except 1 patient (patient 2). The areas with positive BOLD responses in the brainstem, thalami, hippocampi, and basal ganglia decreased in all patients.

DISCUSSION

In the present study, individual and group analyses of EEG-fMRI with hypsarrhythmia showed activation of the brainstem, hippocampus, and thalamus, as well as the cerebral neocortices. In the group-level analysis, positive BOLD responses in the hippocampus, thalamus, and brainstem were obtained from the earlier timing of multiple HRFs than in the cerebral neocortex. On EEG-fMRI of focal EDs during the follow-up period after ACTH therapy, the hippocampus, thalamus, and brainstem were still activated with focal EDs in 3 of 6 children.

Previous neuroimaging studies stressed the importance of the brainstem in the pathophysiology of WS. An FDG-PET study by Chugani et al⁵ showed glucose hypermetabolism in the lenticular nuclei and brainstem in patients with WS, and they hypothesized that epileptic activity propagates from the brainstem to the basal ganglia and cerebral cortex. In a case report of ictal SPECT, increased perfusion in the brainstem was observed in a patient with a defective left hemisphere and symmetric epileptic spasms.¹⁷ Our DTI study showed increased fractional anisotropy and reduced mean diffusivity in the dorsal brainstem at the onset of WS.⁷ The finding of reduced diffusion may suggest cytotoxic edema of the dorsal brainstem. The dorsal raphe area of the brainstem has a large number of serotonergic cell bodies, and it has been hypothesized that raphe-cortical interactions induce hypsarrhythmia.⁶ The individual and group-level results of the present study support the involvement of the brainstem in the epileptic brain activities of WS. Furthermore, the results of the group analysis in the present study showing positive BOLD responses in the brainstem obtained from a P3

HRF and positive BOLD responses in the cerebral cortex from P5 or P7 HRFs support the hypothesis about the propagation pattern of epileptic activity in children with WS.⁶ Multiple HRF analyses provide interesting information about the formation of epileptic networks in WS, though the multiple HRF analyses were originally developed to cover the variable hemodynamics with EDs, and the difference in the HRF does not necessarily mean different timing of epileptiform activities.

The present study found group-level significant positive BOLD responses in the thalamus and hippocampus from P3, P5, and P7

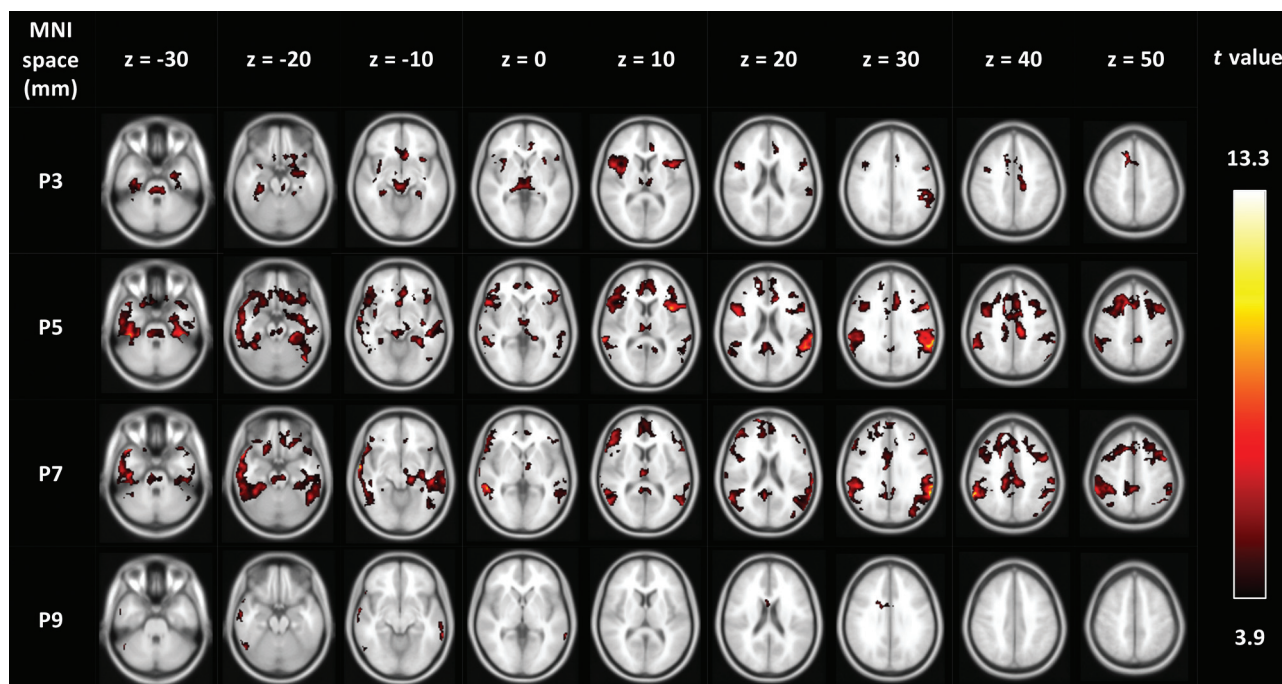


FIG 2. The results of group-level analysis at the onset of WS. With the P3 HRF, significant positive BOLD responses were observed in the brainstem, bilateral hippocampi, and bilateral thalami. Positive BOLD responses in the cerebral cortices were observed mainly with P5 and P7 HRFs, and these HRFs also yielded positive BOLD responses in the pons, midbrain, bilateral thalami, and left hippocampus. No group-level significant negative BOLD responses were observed.

HRFs. The role of the thalamus and hippocampus in WS and hypsarrhythmia is intriguing. It has been hypothesized that the thalamus and hippocampus form a limbic network with the role of distribution and synchronization of hyperexcitability determined from the results of animal model studies of temporal lobe epilepsy.¹⁸ The role of the thalamus and hippocampus in epilepsy has also been discussed in other types of focal and generalized epilepsy.^{19,20} On the other hand, the roles of the hippocampus and thalamus in WS are not fully understood. A previous study of interictal SPECT showed decreased perfusion of the thalamus and hippocampus in children with WS.²¹ The present EEG-fMRI study suggests that epileptogenic activities during hypsarrhythmia are associated with abnormal activities in the hippocampus and thalamus and lead to dysfunction of the limbic system. This hypothesis supports the idea that early cessation of the hypsarrhythmia is important for cognitive outcomes in WS.

The present results also showed that the hippocampus, thalamus, and brainstem were still activated with focal EDs in 3 of 6 children during the follow-up period. All 3 patients with activation in the hippocampus, thalamus, and brainstem with focal EDs had focal epilepsies and developmental delay. Previous EEG-fMRI studies indicated the involvement of subcortical GM, especially the thalamus, in patients with pharmacoresistant focal or multifocal epilepsies.²²⁻²⁴ The present findings indicate that part of the subcortical epileptic activities at the onset of WS remains in some children with focal epilepsies, even after the disappearance of hypsarrhythmia.

A previous EEG-fMRI study of 8 children with WS by Siniatchkin et al⁸ showed a positive correlation between occipital Δ power of the hypsarrhythmia and BOLD responses in

the brainstem, thalamus, and putamen. There are differences in analysis methods between the study by Siniatchkin et al and the present one. The method of the former study was capable of assessing spike components and slow waves of hypsarrhythmia separately. The present method included all spikes and slow waves of each hypsarrhythmia burst in each event and has a weak point in that it does not involve analyzing spike and slow-wave components separately. Another difference is that Siniatchkin et al used the canonical HRF, which has high amplitude with its peak at approximately 5 seconds after an event, and the present study used 4 HRFs with different temporal peaks and lower amplitude. The present method could reduce the *t* values of BOLD responses due to lower amplitude and could raise the sensitivity of significant BOLD responses by covering the temporal gap of the hemodynamic response among brain regions. Although it is uncertain how the methodologic difference affected the results, the present study confirmed the results of Siniatchkin et al, showing activation in the brainstem, thalamus, and basal ganglia, and it additionally found activation in the hippocampus with hypsarrhythmia.

There were some limitations in the present study. First, the number of patients was small. Second, the follow-up period was relatively short, and seizure and long-term developmental outcomes were not examined. Third, because EEG-fMRI is analyzed by marking the EDs on EEG, it cannot be performed in patients without EDs in the follow-up period. Therefore, it was not possible to evaluate the change of activity in the thalami, hippocampi, and brainstem in patients without EDs after ACTH therapy. Despite these limitations, the present results provide important insight into the pathophysiology of WS.

CONCLUSIONS

The present EEG-fMRI study showed the presence of subcortical epileptic networks involving the brainstem, hippocampus, and thalamus at the onset of WS. Activation of the hippocampus, thalamus, and brainstem was still seen in half of the patients with focal EDs after ACTH therapy.

ACKNOWLEDGMENTS

The authors thank Mr Akira Ishizuka of the Brain and Mind Research Center, Nagoya University, for providing technical support for EEG-fMRI scanning.

Disclosure forms provided by the authors are available with the full text and PDF of this article at www.ajnr.org.

REFERENCES

1. Pavone P, Striano P, Falsaperla R, et al. **Infantile spasms syndrome, West syndrome and related phenotypes: what we know in 2013.** *Brain Dev* 2014;36:739–51 [CrossRef Medline](#)
2. Gibbs FA, Gibbs EL. *Atlas of Electroencephalography*. Vol. 2. Chap 6. Addison-Wesley; 1952:24–30
3. Hrachovy RA, Frost JD. **Infantile epileptic encephalopathy with hypsarrhythmia (infantile spasms/West syndrome).** *J Clin Neurophysiol* 2003;20:408–25 [CrossRef Medline](#)
4. Scheffer IE, Berkovic S, Capovilla G, et al. **ILAE classification of the epilepsies: Position Paper of the ILAE Commission for Classification and Terminology.** *Epilepsia* 2017;58:512–21 [CrossRef Medline](#)
5. Chugani HT, Shewmon DA, Sankar R, et al. **Infantile spasms, II. lenticular nuclei and brain stem activation on positron emission tomography.** *Ann Neurol* 1992;31:212–19 [CrossRef Medline](#)
6. Juhasz C, Chugani HT, Muzik O, et al. **Neuroradiological assessment of brain structure and function and its implication in the pathogenesis of West syndrome.** *Brain Dev* 2001;23:488–95 [CrossRef Medline](#)
7. Ogawa C, Kidokoro H, Fukasawa T, et al. **Cytotoxic edema at onset in West syndrome of unknown etiology: a longitudinal diffusion tensor imaging study.** *Epilepsia* 2018;59:440–48 [CrossRef Medline](#)
8. Siniatchkin M, van Baalen A, Jacobs J, et al. **Different neuronal networks are associated with spikes and slow activity in hypsarrhythmia.** *Epilepsia* 2007;48:2312–21 [CrossRef Medline](#)
9. Ito Y, Maki Y, Okai Y, et al. **Involvement of brain structures in childhood epilepsy with centrotemporal spikes.** *Pediatr Int* 2021;64:e15001 [CrossRef Medline](#)
10. Allen PJ, Josephs O, Turner R. **A method for removing imaging artifact from continuous EEG recorded during functional MRI.** *Neuroimage* 2000;12:230–99 [CrossRef Medline](#)
11. Niazy RK, Beckmann CF, Lannetti GD, et al. **Removal of fMRI environment artifacts from EEG data using optimal basis sets.** *Neuroimage* 2005;28:720–37 [CrossRef Medline](#)
12. Warren AE, Harvey AS, Vogrin SJ, et al. **The epileptic network of Lennox-Gastaut syndrome: cortically driven and reproducible across age.** *Neurology* 2019;93:e215–26 [CrossRef](#)
13. Moeller F, Siebner HR, Wolff S, et al. **Simultaneous EEG-fMRI in drug-naïve children with newly diagnosed absence epilepsy.** *Epilepsia* 2008;49:1510–19 [CrossRef Medline](#)
14. Bagshaw AP, Aghakhani Y, Benar CG, et al. **EEG-fMRI of focal epileptic spikes: analysis with multiple haemodynamic functions and comparison with gadolinium-enhanced MR angiograms.** *Hum Brain Mapp* 2004;22:179–92 [CrossRef Medline](#)
15. Tzourio-Mazoyer N, Landeau B, Papathanassiou D, et al. **Automated anatomical labeling of activations in SPM using a macroscopic anatomical parcellation of the MNI MRI single-subject brain.** *Neuroimage* 2002;15:273–89 [CrossRef Medline](#)
16. Usami K, Matsumoto R, Sawamoto N, et al. **Epileptic network of hypothalamic hamartoma: an EEG-fMRI study.** *Epilepsy Res* 2016;125:1–9 [CrossRef Medline](#)
17. Haginoya K, Kon K, Tanaka S, et al. **The origin of hypsarrhythmia and tonic spasms in West syndrome: evidence from a case of porencephaly and hydrocephalus with focal hypsarrhythmia.** *Brain Dev* 1999;21:129–31 [CrossRef Medline](#)
18. Bertram EH, Zhang DX, Mangan P, et al. **Functional anatomy of limbic epilepsy: a proposal for central synchronization of a diffusely hyperexcitable network.** *Epilepsy Res* 1998;32:194–205 [CrossRef Medline](#)
19. Dell KL, Cook MJ, Maturana MI. **Deep brain stimulation for epilepsy: biomarkers for optimization.** *Curr Treat Options Neurol* 2019;21:47 [CrossRef Medline](#)
20. Ilyas A, Pizarro D, Romeo AK, et al. **The centromedian nucleus: anatomy, physiology, and clinical implications.** *J Clin Neurosci* 2019;63:1–7 [CrossRef Medline](#)
21. Hamano S, Higurashi N, Koichihara R, et al. **Interictal cerebral blood flow abnormality in cryptogenic West syndrome.** *Epilepsia* 2010;51:1259–65 [CrossRef Medline](#)
22. Fahoum F, Lopes R, Pittau F, et al. **Widespread epileptic networks in focal epilepsies: EEG-fMRI study.** *Epilepsia* 2012;53:1618–27 [CrossRef Medline](#)
23. An D, Dubeau F, Gotman J. **BOLD responses related to focal spikes and widespread bilateral synchronous discharges generated in the frontal lobe.** *Epilepsia* 2015;56:366–74 [CrossRef Medline](#)
24. Siniatchkin M, Moehring J, Kroeher B, et al. **Multifocal epilepsy in children is associated with increased long-distance functional connectivity: an explorative EEG-fMRI study.** *Eur J Paediatr Neurol* 2018;22:1054–65 [CrossRef Medline](#)