



## Discover Generics

Cost-Effective CT & MRI Contrast Agents



WATCH VIDEO

# AJNR

This information is current as of June 18, 2025.

## Postprocedural Antiplatelet Treatment after Emergent Carotid Stenting in Tandem Lesions Stroke: Impact on Stent Patency beyond Day 1







R. Pop, A. Hasiu, P.H. Mangin, F. Severac, D. Mihoc, D. Nistoran, M. Manisor, M. Simu, S. Chibbaro, R. Gheoca, V. Quenardelle, O. Rouyer, V. Wolff and R. Beaujeux

*AJNR Am J Neuroradiol* 2021, 42 (5) 921-925

doi: <https://doi.org/10.3174/ajnr.A6993>

<http://www.ajnr.org/content/42/5/921>

# Postprocedural Antiplatelet Treatment after Emergent Carotid Stenting in Tandem Lesions Stroke: Impact on Stent Patency beyond Day 1

 R. Pop,  A. Hasiu,  P.H. Mangin,  F. Severac,  D. Mihoc,  D. Nistoran,  M. Manisor,  M. Simu,  S. Chibbaro,  R. Gheoca,  V. Quenardelle,  O. Rouyer,  V. Wolff, and  R. Beaujeux



## ABSTRACT

**BACKGROUND AND PURPOSE:** Postprocedural dual-antiplatelet therapy is frequently withheld after emergent carotid stent placement during stroke thrombectomy. We aimed to assess whether antiplatelet regimen variations increase the risk of stent thrombosis beyond postprocedural day 1.

**MATERIALS AND METHODS:** Retrospective review was undertaken of all consecutive thrombectomies for acute stroke with tandem lesions in the anterior circulation performed in a single comprehensive stroke center between January 9, 2011 and March 30, 2020. Patients were included if carotid stent patency was confirmed at day 1 postprocedure. The group of patients with continuous dual-antiplatelet therapy from day 1 was compared with the group of patients with absent/discontinued dual-antiplatelet therapy.

**RESULTS:** Of a total of 109 tandem lesion thrombectomies, 96 patients had patent carotid stents at the end of the procedure. The early postprocedural stent thrombosis rate during the first 24 hours was 14/96 (14.5%). Of 82 patients with patent stents at day 1, in 28 (34.1%), dual-antiplatelet therapy was either not initiated at day 1 or was discontinued thereafter. After exclusion of cases without further controls of stent patency, there was no significant difference in the rate of subacute/late stent thrombosis between the 2 groups: 1/50 (2%) in patients with continuous dual-antiplatelet therapy versus 0/22 (0%) in patients with absent/discontinued dual-antiplatelet therapy ( $P=1.000$ ). In total, we observed 88 patient days without any antiplatelet treatment and 471 patient days with single antiplatelet treatment.

**CONCLUSIONS:** Discontinuation of dual-antiplatelet therapy was not associated with an increased risk of stent thrombosis beyond postprocedural day 1. Further studies are warranted to better assess the additional benefit and optimal duration of dual-antiplatelet therapy after tandem lesion stroke thrombectomy.

**ABBREVIATIONS:** DAPT = dual-antiplatelet therapy; ST = stent thrombosis

In around 15% of endovascular procedures for anterior circulation stroke,<sup>1</sup> there is a tight stenosis or occlusion of the cervical carotid artery in addition to the intracranial artery occlusion. The optimal endovascular management of tandem lesions has yet to be defined; however, there is mounting evidence<sup>2,3</sup> that emergent stent

placement in the carotid artery associated with at least 1 antiplatelet agent could lead to better recanalization rates and improved clinical outcomes. A more definitive answer should be provided by the Thrombectomy In TANdem lesions (TITAN) randomized multicenter trial,<sup>4</sup> designed to assess the safety and efficacy of emergent internal carotid artery stent placement in tandem lesion thrombectomy. This study recently enrolled the first patient in early 2020.

In patients undergoing emergent carotid stent placement, there is no consensus regarding the optimal periprocedural antiplatelet therapy. Many groups<sup>5,6</sup> chose to avoid dual-antiplatelet therapy (DAPT) during the first 24 hours in an attempt to reduce the risk of hemorrhagic transformation. Conversely, less aggressive antiplatelet regimens might increase the risk of carotid stent thrombosis.

Stent thrombosis was recently identified as a predictor of unfavorable clinical outcome.<sup>7,8</sup> To date, available data regarding stent patency rates remain scarce. Most case series of endovascular management for tandem lesions<sup>5,9-11</sup> do not report postprocedural

Received October 9, 2020; accepted after revision November 10.

From the Departments of Interventional Neuroradiology (R.P., A.H., D.M., D.N., M.M., R.B.), Public Healthcare (F.S.), Neurosurgery (S.C.), and Stroke Unit (R.G., V.Q., O.R., V.W.), Strasbourg University Hospitals, Strasbourg, France; Institut de Chirurgie Minimale Invasive Guidée par l'Image (R.P., R.B.), Strasbourg, France; Institut National de la Santé et de la Recherche Médicale (P.H.M.), University of Strasbourg, l'Établissement français du sang Grand-Est, BPPS UMR-S1255, Fédération de Médecine Translationnelle de Strasbourg, Strasbourg, France; Neurology Department (M.S.), Victor Babes University of Medicine and Pharmacy, Timisoara, Romania.

Please address correspondence to Raoul Pop, MD, PhD, Department of Interventional Neuroradiology, Strasbourg University Hospital, Strasbourg, France, 1 Ave Molière, 67098 Strasbourg, France; e-mail: pop.raoul@gmail.com; @RaoulPop25

 Indicates article with online supplemental data.

<http://dx.doi.org/10.3174/ajnr.A6993>

stent patency, while some publications<sup>12-15</sup> offer partial data for a subgroup of patients for whom carotid imaging controls were available. Reported rates of stent thrombosis ranged between 1.2% and 22.0%.<sup>6-8,12-14,16,17</sup>

To date, no study has attempted to differentiate between early (first 24 hours) and subacute/late postprocedural stent thrombosis. During the first 24 hours, protection against stent thrombosis is conferred by antiplatelet agents administered during the procedure (periprocedural antiplatelets). Beyond 24 hours, the recommended antiplatelet regimen is DAPT for 4–12 weeks,<sup>9,17</sup> but in reality, antiplatelets are often tailored in view of neurological and extra-neurological hemorrhagic events. It is currently unknown whether discontinuation of DAPT is associated with an increased risk of late stent thrombosis.

Thus, we aimed to describe the variations in the postprocedural antiplatelet regimen in a large consecutive cohort of tandem lesion thrombectomies with emergent carotid artery stent placement and to assess whether discontinuation of DAPT was associated with an increased risk of carotid stent thrombosis.

## MATERIALS AND METHODS

We performed a retrospective review of a prospectively collected data base of stroke endovascular procedures in a single comprehensive stroke center (Strasbourg University Hospital, France), including all consecutive cases treated by endovascular thrombectomy for acute stroke with tandem lesions in the anterior circulation between January 9, 2011, and March 30, 2020. Tandem lesions were defined as an association of extracranial ICA occlusion or stenosis of  $\geq 70\%$  using the NASCET criteria and an intracranial artery occlusion in the anterior circulation. Patients were included in the study if treated by emergent carotid stent placement during thrombectomy and if stent patency was confirmed at day 1 postprocedure. Exclusion criteria were as follows: no carotid stent implanted, failure of recanalization, periprocedural stent thrombosis, imaging study showing an occluded carotid stent at day 1, and absence of further imaging studies for stent patency after day 1 or after antiplatelet treatment discontinuation.

Images stored on the PACS and radiology reports were reviewed to extract technical details of the endovascular procedure, as well as postprocedural imaging. Patient files were reviewed to extract patient demographics, comorbidities, peri- and postprocedural antiplatelet regimens, clinical status at discharge, and clinical follow-up information.

### Patient Selection and Preprocedural Imaging

Patients with acute stroke were selected for endovascular procedures using MR imaging, except in case of extreme agitation or absolute contraindications. Patients with favorable profiles for recanalization were selected using clinical-radiologic mismatch (discrepancy between the severity of neurologic deficits and the size of acute ischemic lesion on the diffusion sequence) as well as estimation of leptomeningeal collateral status using FLAIR vascular hyperintensities.<sup>18</sup> Patients with acute infarction in more than two-thirds of the middle cerebral artery territory were generally not considered for treatment. Wake-up strokes and patients with unclear time of onset were considered for treatment if last seen well <12 hours before evaluation, using the same imaging selection criteria.

## Endovascular Procedure

All procedures were performed with the patient under general anesthesia. During the studied period, the strategy did not change significantly and consisted, in most cases, of an antegrade approach: stent placement and angioplasty of the proximal occlusion before addressing the intracranial occlusion.

### Periprocedural and Postprocedural Antiplatelet Treatment

The periprocedural antiplatelet regimen consisted of an IV loading dose of aspirin (250 mg) with or without a loading dose of clopidogrel (300 mg), depending on operator preferences and case-by-case discussion (estimation of hemorrhagic transformation risk depending on the size of the acute ischemic lesion and concomitant treatment with IV thrombolysis). Periprocedural DAPT was generally avoided in cases with a DWI ASPECTS of  $\leq 5$ . In selected cases, glycoprotein IIb/IIIa inhibitors were administered in the acute phase for treatment of periprocedural stent thrombosis.

Postprocedural antiplatelet treatment was initiated after 24 hours (day 1 postprocedure). If the stent was patent and in the absence of significant hemorrhagic transformation, clopidogrel, 75 mg/day, was administered for 3 months in addition to lifelong aspirin, 75 mg/day. In case of significant hemorrhagic transformation, antiplatelets were suspended or a single antiplatelet was administered (aspirin) until the clinical status was stable and the extent of hemorrhagic transformation was reassessed on repeat cerebral imaging.

### Postprocedural Imaging and Clinical Follow-up

All patients underwent cerebral CT at day 1 postprocedure. Hemorrhagic transformation was evaluated using the European Cooperative Acute Stroke Study criteria.<sup>19</sup> In addition, for patients with carotid stents, cervical and transcranial Doppler sonography was performed at day 1 and, if possible, before discharge, to check for stent patency. If a sonographic examination was not feasible at day 1, CT angiography of the carotid arteries was performed along with the CT examination. In addition, whenever possible, patients were recalled for additional clinical and carotid sonography examinations between 3 months and 1 year after the initial event.

### Statistical Analysis

Continuous variables were presented as median with interquartile range and compared using the Mann-Whitney test after assessment of the normality of distribution. Categorical variables were presented as numbers and percentages and compared using the Pearson  $\chi^2$  test or Fisher exact test, depending on theoretic numbers. Statistical data were analyzed using GraphPad Prism, Version 6.0 (GraphPad Software).

## RESULTS

During the study period, we identified 109 thrombectomies for acute strokes with tandem lesions. The Figure illustrates the patient-selection diagram. Among 96 patients with patent carotid stents at the end of the thrombectomy procedure, 14 cases had occluded carotid stents at day 1, accounting for an early postprocedural stent thrombosis rate of 14.5%. Among the 14 patients with occluded carotid stents at 24 hours, the median mRS score

at discharge was 4 (interquartile range, 4–4) and the mortality rate was 1/14 (7.1%). Only 1 patient (7.1%) had mRS  $\leq$  2.

Among 82 patients with patent carotid stents at day 1, in 54 cases (65.8%), DAPT could be initiated at day 1 and continued without interruptions. In the remaining 28 cases (34.1%), DAPT was either not initiated at day 1 or was discontinued thereafter.

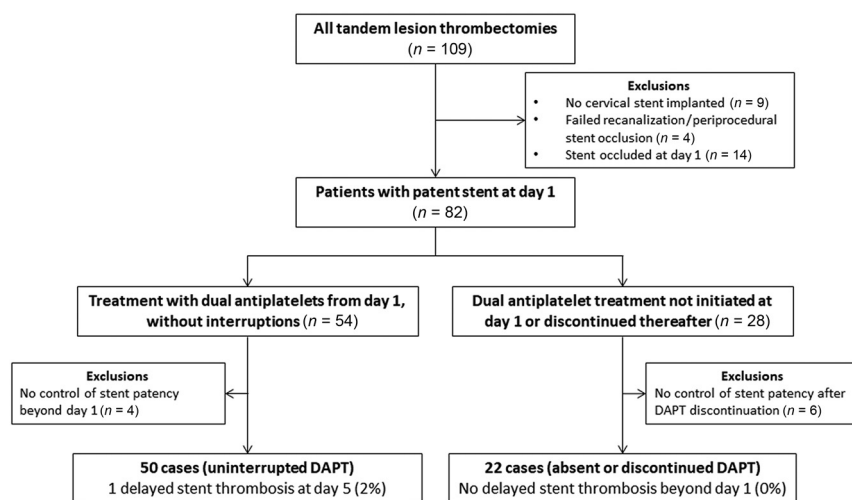
After further exclusion of cases without further controls of stent patency beyond day 1 or after DAPT discontinuation, the first group of 50 patients without interruptions in postprocedural DAPT was compared with the second group of 22 patients with absent or discontinued postprocedural DAPT.

A comparison of baseline characteristics, procedural metrics, and outcomes across the 2 groups is detailed in the Online

Supplemental Data. Patients with absent/discontinued DAPT had significantly longer onset-to-femoral puncture times, lower ASPECTSs, more frequent hemorrhagic transformation, and less favorable clinical outcomes. All these differences can be explained by the selection process: The main reason for avoiding DAPT was hemorrhagic transformation. Late time window treatment and lower baseline ASPECTS are known predictors of hemorrhagic transformation, while hemorrhagic transformation itself is a known predictor of worse clinical outcomes.

The Table details antiplatelet regimen variations within the group of 22 cases with absent/discontinued DAPT. Most frequently, DAPT was avoided because of hemorrhagic transformation of ischemic stroke (68.1%), followed by subarachnoid hemorrhage (9.1%) and decompressive craniectomy (13.6%). Nine patients (40.9%) never received DAPT, while for the remaining 13 (59.1%), DAPT was discontinued for varying periods (median, 9 days; interquartile range, 5–12 days). In total, we observed 88 patient days without any antiplatelet treatment and 471 patient days with single-antiplatelet treatment. The median stent patency follow-up duration in this group was 57 days (interquartile range, 35–125 days).

There was no significant difference in the rate of subacute/late stent thrombosis between the 2 groups: 1/50 (2%) in patients with continuous DAPT versus 0/22 (0%) in patients with absent/discontinued DAPT ( $P = 1.000$ ).



**FIGURE.** Patient-selection diagram.

#### Description of patients with absent/discontinued dual-antiplatelet treatment

	DAPT Not Initiated at Day 1 or Discontinued Thereafter (n = 22)
Antiplatelet regimen	
Never received DAPT (No) (%)	9/22 (40.9%)
Patient days without antiplatelet treatment	71
Patient days with single antiplatelet treatment	355
Discontinued DAPT (No) (%)	13/22 (59.1%)
Duration without DAPT (median) (IQR) (day)	9 (5–12)
Patient days without antiplatelet treatment	17
Patient days with single antiplatelet treatment	116
Total	
Patient days without antiplatelet treatment	88
Patient days with single antiplatelet treatment	471
Reason for avoiding DAPT (No) (%)	
Hemorrhagic transformation of ischemic stroke	15 (68.1%)
Subarachnoid hemorrhage	2 (9.1%)
Decompressive craniectomy	3 (13.6%)
Gastrointestinal bleeding <sup>a</sup>	2 (9.1%)
Planned interventional/surgical procedure <sup>b</sup>	2 (9.1%)
Lack of naso-/orogastric access	1 (4.5%)
Duration of stent patency follow-up (median) (IQR) (day)	57 (35–125)
Stent occlusion beyond day 1 (No) (%)	0 (0%)

**Note:**—IQR indicates interquartile range.

<sup>a</sup> One patient had both SAH and gastrointestinal bleeding; the second patient had both hemorrhagic transformation and gastrointestinal bleeding.

<sup>b</sup> One patient had both hemorrhagic transformation and a surgical procedure.

#### DISCUSSION

To the best of our knowledge, this is the first study to specifically assess the risk of subacute/late stent thrombosis beyond postprocedural day 1 in patients treated with emergent carotid stent placement for acute stroke with tandem lesions. The 3 main findings of this work are as follows: 1) Postprocedural DAPT is frequently discontinued in this population; 2) subacute/late stent thrombosis is much less frequent than early stent thrombosis (during the first 24 hours); and 3) discontinuation of postprocedural DAPT does not seem to be associated with an increased risk of stent thrombosis.

In a previous publication,<sup>7</sup> we analyzed predictors of postprocedural stent thrombosis in 73 patients. We observed 14 cases (19.1%) of stent thrombosis, most of which (13/14,

92.8%) occurred during the first 24 hours. Due to this finding, we hypothesized that the highest risk of stent thrombosis is observed during the first 24 hours. To further assess the real frequency of stent thrombosis in the subacute/late phase (beyond day 1), in the present study, we focused exclusively on patients with a patent stent at day 1. Although a multivariate analysis to identify predictors of late stent thrombosis was planned, this was not feasible due to the very low number of detected events. In the cardiology literature,<sup>20</sup> the timing of coronary stent thrombosis (ST) is delineated as follows: early ST (acute ST, between 0 and 24 hours, and subacute ST, 24 hours to 30 days), late ST (between 30 days and 1 year), and very late ST (>1 year). Given the very low rate of stent thrombosis observed beyond the first 24 hours, we chose to simplify the classification of carotid stent thrombosis into 2 categories: early ST (first 24 hours) and subacute/late ST (beyond day 1).

Few published studies have reported stent patency rates for a large proportion of patients in their cohort.<sup>8,12–14,17</sup> The time point of stent thrombosis (early versus subacute/late) is not listed in most of these studies. Malik et al<sup>16</sup> reported 24-hour imaging follow-up of stent patency for all 77 patients in their cohort, with only 1 (1.2%) thrombosed stent. Long-term stent patency follow-up was available in only 27 patients, with an in-stent restenosis rate of 2/27 (7.4%). Postprocedural antiplatelet regimen variations were not listed. Renú et al<sup>8</sup> reported a stent occlusion rate of 22% at 24 hours in a cohort of 99 patients; however, they did not record stent patency beyond day 1. Wallocha et al<sup>16</sup> reported 24-hour Doppler sonography results for all 149 patients with stents in their cohort, with 8 (5.4%) cases of stent thrombosis. Stent patency rates beyond day 1 were not listed. However, the authors did offer details on postprocedural antiplatelet regimen variations; 32.2% of patients received only a single antiplatelet agent, 3.3%, no antiplatelet agent. The duration of DAPT discontinuation was not provided; however, this relatively high proportion of patients who did not receive postprocedural DAPT is concordant with the findings in our study.

That postprocedural DAPT discontinuation was not associated with an increased risk of stent thrombosis is surprising. In the cardiology literature, early antiplatelet therapy discontinuation was identified as a prevalent and consistent, significant predictor of coronary stent thrombosis.<sup>20</sup> However, the comparison with our clinical setting is limited by significant differences in vessel size and morphology, types of stents, and local hemodynamic conditions. One possible explanation might be that the overall percentages of late stent thrombosis are very low, either with or without continuous postprocedural DAPT. To detect a small difference between the 2 groups, a very large sample size would be needed; thus, the negative result of the present study could represent a type II error. Nevertheless, the low rate of late stent thrombosis in itself (1/72, 1.3% for our entire cohort) could prove useful for decision-making in the clinical setting. There are no established criteria for withholding DAPT, and often the decisions are based on a subjective evaluation of the extent of hemorrhagic transformation. Given the overall low likelihood of carotid stent thrombosis, clinicians could probably use a low threshold to temporarily withhold DAPT in patients with concomitant hemorrhagic events.

In view of the worse clinical outcomes for patients with discontinued DAPT, an alternative hypothesis is that interruption of

DAPT could cause thromboembolic events short of stent occlusion. In the Safety and Efficacy Study for Reverse Flow Used During Carotid Artery Stenting Procedure (ROADSTER II) trial,<sup>21</sup> a report on elective transcatheter artery revascularization, the investigators blamed most of their strokes on discontinuation of DAPT. In the current study, because the group with discontinued DAPT did clinically worse mostly because of factors related to the index stroke and complications, it is not feasible to discern this effect.

Of note, the only case of late stent thrombosis observed in our study occurred at day 5 postthrombectomy in a patient treated with continuous DAPT from day 1. A Casper stent (MicroVention) was placed and then subsequently had to be covered with a second stent (Wallstent; Boston Scientific) due to malapposition in the carotid bifurcation. The presence of 3 layers of metal mesh, in addition to the initial stent malapposition, most likely played a principal role in the subsequent stent thrombosis in this case; however, clopidogrel resistance was not tested and might also have been a contributing factor.

Currently, there is no consensus on the optimal duration of postprocedural DAPT; available data in the literature reveal a large variation in practices, ranging from 4 to 12 weeks.<sup>6,9</sup> If the findings of our current study are confirmed in larger cohorts, in light of the low frequency of subacute/late stent thrombosis and the likely small additional benefit of DAPT versus single antiplatelet agent beyond the first 24 hours, the recommended duration of postprocedural DAPT could potentially be shortened in patients with higher neurologic or systemic hemorrhagic risk.

The present study has 2 main strengths. First, it included all consecutive cases of tandem lesion stroke thrombectomies performed during a long time interval. Second, all patients benefited from stent patency imaging at day 1, and most patients also had further controls during follow-up. This process allowed differentiation between early and subacute/late stent thrombosis. However, several limitations also need to be considered when interpreting the current data: most important, the retrospective study design, all patients being treated in a single center, and the reduced statistical power due to overall cohort size and the relatively small number of cases in the group with discontinued postprocedural DAPT. Moreover, a quarter of the patients with discontinued DAPT were followed for <35 days. Hence, they did not have the usual 1-month follow-up standard for determining stent patency as in carotid stent trials; thus, some cases of subacute stent thrombosis might have gone undetected.

## CONCLUSIONS

In this study of consecutive patients treated with emergent carotid stent placement during tandem lesion stroke thrombectomy, stent thrombosis beyond the first 24 hours was rare. Despite postprocedural DAPT being frequently discontinued in this population, this outcome was not associated with an increased risk of stent thrombosis. Further studies are warranted to better assess the additional benefit and the optimal duration of DAPT versus a single-antiplatelet agent beyond the first 24 hours postthrombectomy.



## REFERENCES

1. Rubiera M, Ribo M, Delgado-Mederos R, et al. **Tandem internal carotid artery/middle cerebral artery occlusion: an independent predictor of poor outcome after systemic thrombolysis.** *Stroke* 2006;37:2301–05 [CrossRef Medline](#)
2. Papanagiotou P, Haussen DC, Turjman F, et al; TITAN Investigators. **Carotid stenting with antithrombotic agents and intracranial thrombectomy leads to the highest recanalization rate in patients with acute stroke with tandem lesions.** *JACC Cardiovasc Interv* 2018;11:1290–99 [CrossRef Medline](#)
3. Dufort G, Chen BY, Jacquin G, et al. **Acute carotid stenting in patients undergoing thrombectomy: a systematic review and meta-analysis.** *J Neurointerv Surg* 2020 Jun 12. [Epub ahead of print] [CrossRef Medline](#)
4. Zhu F, Hossu G, Soudant M, et al. **Effect of emergent carotid stenting during endovascular therapy for acute anterior circulation stroke patients with tandem occlusion: a multicenter, randomized, clinical trial (TITAN) protocol.** *Int J Stroke* 2020 Jun 9. [Epub ahead of print] [CrossRef Medline](#)
5. Fahed R, Redjem H, Blanc R, et al. **Endovascular management of acute ischemic strokes with tandem occlusions.** *Cerebrovasc Dis* 2016;41:298–305 [CrossRef Medline](#)
6. Wallocha M, Chapot R, Nordmeyer H, et al. **Treatment methods and early neurologic improvement after endovascular treatment of tandem occlusions in acute ischemic stroke.** *Front Neurol* 2019;10:127 [CrossRef Medline](#)
7. Pop R, Zinchenko I, Quenardelle V, et al. **Predictors and clinical impact of delayed stent thrombosis after thrombectomy for acute stroke with tandem lesions.** *AJNR Am J Neuroradiol* 2019;40:533–39 [CrossRef Medline](#)
8. Renú A, Blasco J, Laredo C, et al. **Carotid stent occlusion after emergent stenting in acute ischemic stroke: incidence, predictors and clinical relevance.** *Atherosclerosis* 2020;313:8–13 [CrossRef Medline](#)
9. Behme D, Mpotsaris A, Zeyen P, et al. **Emergency stenting of the extracranial internal carotid artery in combination with anterior circulation thrombectomy in acute ischemic stroke: a retrospective multicenter study.** *AJNR Am J Neuroradiol* 2015;36:2340–44 [CrossRef Medline](#)
10. Maurer CJ, Joachimski F, Berlis A. **Two in one: endovascular treatment of acute tandem occlusions in the anterior circulation.** *Clin Neuroradiol* 2015;25:397–402 [CrossRef Medline](#)
11. Grigoryan M, Haussen DC, Hassan AE, et al. **Endovascular treatment of acute ischemic stroke due to tandem occlusions: large multicenter series and systematic review.** *Cerebrovasc Dis* 2016;41:306–12 [CrossRef Medline](#)
12. Heck DV, Brown MD. **Carotid stenting and intracranial thrombectomy for treatment of acute stroke due to tandem occlusions with aggressive antiplatelet therapy may be associated with a high incidence of intracranial hemorrhage.** *J Neurointerv Surg* 2015;7:170–75 [CrossRef Medline](#)
13. Lockau H, Liebig T, Henning T, et al. **Mechanical thrombectomy in tandem occlusion: procedural considerations and clinical results.** *Neuroradiology* 2015;57:589–98 [CrossRef Medline](#)
14. Steglich-Arnholm H, Holtmannspotter M, Kondziella D, et al. **Thrombectomy assisted by carotid stenting in acute ischemic stroke management: benefits and harms.** *J Neurol* 2015;262:2668–75 [CrossRef Medline](#)
15. Gory B, Haussen DC, Piotin M, et al; Thrombectomy In TANdem lesions (TITAN) investigators. **Impact of intravenous thrombolysis and emergent carotid stenting on reperfusion and clinical outcomes in acute stroke patients with tandem lesion treated with thrombectomy: a collaborative pooled analysis.** *Eur J Neurol* 2018;25:1115–20 [CrossRef Medline](#)
16. Malik AM, Vora NA, Lin R, et al. **Endovascular treatment of tandem extracranial/intracranial anterior circulation occlusions: preliminary single-center experience.** *Stroke* 2011;42:1653–57 [CrossRef Medline](#)
17. Neuberger U, Moteva K, Vollherbst DF, et al. **Tandem occlusions in acute ischemic stroke – impact of antithrombotic medication and complementary heparin on clinical outcome and stent patency.** *J Neurointerv Surg* 2020;12:1088–93 [CrossRef Medline](#)
18. Legrand L, Tisserand M, Turc G, et al. **Do FLAIR vascular hyperintensities beyond the DWI lesion represent the ischemic penumbra?** *AJNR Am J Neuroradiol* 2015;36:269–74 [CrossRef Medline](#)
19. Hacke W, Kaste M, Bluhmki E, et al; ECASS Investigators. **Thrombolysis with alteplase 3 to 4.5 hours after acute ischemic stroke.** *N Engl J Med* 2008;359:1317–29 [CrossRef Medline](#)
20. D'Ascenzo F, Bollati M, Clementi F, et al. **Incidence and predictors of coronary stent thrombosis: evidence from an international collaborative meta-analysis including 30 studies, 221,066 patients, and 4276 thromboses.** *Int J Cardiol* 2013;167:575–84 [CrossRef Medline](#)
21. Kashyap VS, Schneider PA, Foteh M, et al; ROADSTER 2 Investigators. **Early outcomes in the ROADSTER 2 study of trans-carotid artery revascularization in patients with significant carotid artery disease.** *Stroke* 2020;51:2620–29 [CrossRef Medline](#)