



Discover Generics

Cost-Effective CT & MRI Contrast Agents



FRESENIUS
KABI

WATCH VIDEO

AJNR

The "Bovine Aortic Arch": Time to Rethink the True Origin of the Term?

L.J. Ridley, J. Han and H. Xiang

AJNR Am J Neuroradiol 2019, 40 (2) E7-E8

doi: <https://doi.org/10.3174/ajnr.A5924>

<http://www.ajnr.org/content/40/2/E7>

This information is current as
of June 9, 2025.

The “Bovine Aortic Arch”: Time to Rethink the True Origin of the Term?

We read with some bemusement the ongoing debate about the term “bovine aortic arch” and calls for a change in name. The most recent is the letter by Rajagopal and Sharma, who nicely describe the embryologic basis but fail to prove that “bovine” is a misnomer.¹

We recently reviewed the bovine aortic arch as part of a collection of animal signs in radiology.² The debate about the bovine arch in the literature focuses on the recognition that this is not the normal aortic branching pattern in bovines. This is insufficient evidence to describe “bovine” as a misnomer, particularly when this fact was known several decades before the first articles to use the term (one of which even cited this preceding literature).

The appropriate question then becomes why is this variation called a bovine arch when it is not found in bovines?

Many signs in clinical medicine represent analogies being made to something known: pattern finding being an important and fundamental process in the way humans think. Describing the pattern of the stars as being in the shape of animals or heroes is just one of the more ancient examples. The uptake of the analogy depends on whether others find the association useful.

There are many ways in which one may ascribe an animal term. Some are indeed named because they are the normal pattern in such animals: such as avian appendix and feline esophagus. Galen’s writing describes several anatomic features resembling an animal, including muscle (“musculus” being Latin for “little mouse”) and coracoid process (Greek for “like a crow”). A few are named after movements resembling an animal such as the bullfrog swallow and jellyfish sign in pleural effusions. The eating disorder “Pica” is even named after an animal’s behavior (Pica being Latin for crow, a bird considered to eat anything). Many signs are named after the radiologic appearance resembling an animal, including butterfly glioma and the hummingbird sign as well as anatomic variants such as butterfly vertebra and fish tail pancreas.

There are also examples in which the origin of a term has not been recognized and alternate associations have been made. Many fish terms have been used to describe osteoporotic vertebrae, including “fish-mouth” and “fish-tail” (both being analogies with the radiologic appearance). The correct terminology was debated in the literature until Murphy and DiVito determined that Albright initially likened the pathologic pattern in humans to the normal vertebrae in fish.³ The homonyms of “thrush,” the bird

(from old English “songbird”) and the disease (from Scandinavian “rotten”), represent another example in which some have tried to find a visual association because of not being aware of the different etymology of the terms.

Recognizing the many ways in which one can be ascribe an animal descriptor widens the options for the origin of the term “bovine.” We favor Jiri Vitek’s radiologic derivation.⁴ During the decades when angiography was the primary method of assessing the cerebral vessels, overlapping of structures limited clear delineation of the anatomy. When the left common carotid artery arises from the brachiocephalic artery, it has a more horizontal initial course than with an aortic origin. This resembles the horns of a bovine, which are characteristically horizontal at the top of the bovine head before they curve superiorly (Figure).

In conclusion, the term “bovine aortic arch” is a widely used and a simple description. We believe that it is time to drop the notion that the name derives from the anatomic pattern in bovines because we are not aware of any evidence to support this as the origin of the term. No one, for example, would describe butterfly vertebra as a misnomer, even though butterflies do not have vertebrae.

Disclosures: Lloyd J. Ridley—UNRELATED: Payment for Lectures Including Service on Speakers Bureaus: AstraZeneca, Comments: state speaker honorarium for AstraZeneca.

REFERENCES

1. Rajagopal R, Sharma S. **Comment on “Common Origin of Brachiocephalic and Left Common Carotid Arteries: Proposal of New Terminology.”** *AJNR Am J Neuroradiol* 2018;39:E105 [CrossRef Medline](#)
2. Han J, Xiang H, Ridley WE, et al. **Bovine aortic arch.** *J Med Imaging Radiat Oncol* 2018;62 (supplement 1): 20–21 [Medline](#)
3. Murphy WA Jr, DiVito DM. **Fuller Albright, postmenopausal osteoporosis, and fish vertebrae.** *Radiology* 2013;268:323–26 [CrossRef Medline](#)
4. Vitek JJ. **Comment on: Bovine aortic arch variant in humans: clarification of a common misnomer.** *AJNR Am J Neuroradiol* 2007;28:1205, author reply 1205 [CrossRef Medline](#)

 **L.J. Ridley**

Department of Radiology
Concord Repatriation General Hospital
Concord, New South Wales, Australia

 **J. Han**

Medical Imaging
University of Sydney
Sydney, New South Wales, Australia

 **H. Xiang**

Department of Radiology
Concord Repatriation General Hospital
Concord, New South Wales, Australia

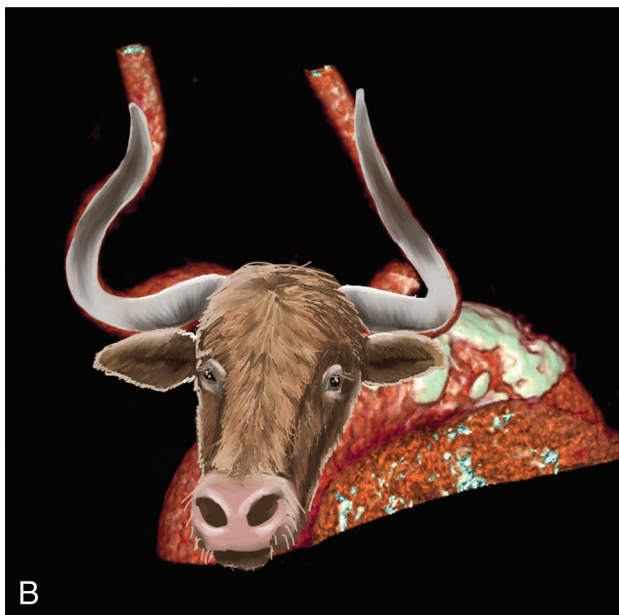
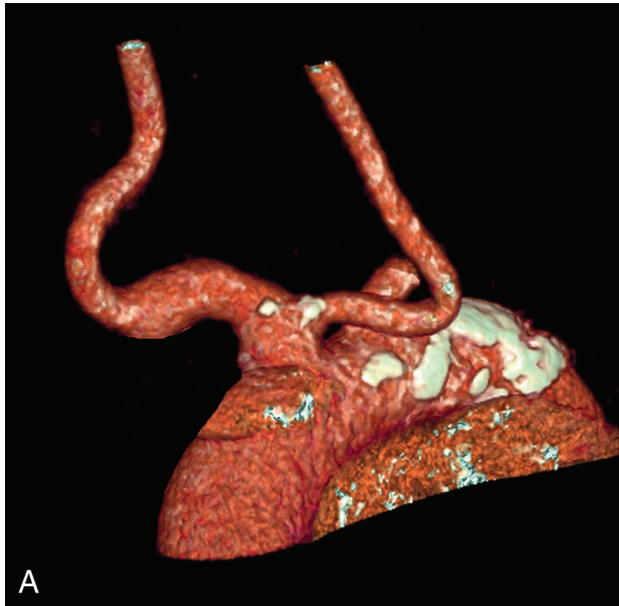

FIGURE. *A*, Volume-rendered 3D image of a bovine arch derived from a CT angiogram. *B*, Graphic of a bovine head drawn onto the volume-rendered image shown in *A*.