



## Discover Generics

Cost-Effective CT & MRI Contrast Agents



FRESENIUS  
KABI

WATCH VIDEO

# AJNR

## Leakage of iodinated contrast material into the cerebral ventricles in an adult with ependymitis.

W T Sullivan and R H Dorwart

*AJNR Am J Neuroradiol* 1983, 4 (6) 1251-1253

<http://www.ajnr.org/content/4/6/1251.citation>

This information is current as  
of June 8, 2025.

# Leakage of Iodinated Contrast Material into the Cerebral Ventricles in an Adult with Ependymitis

William T. Sullivan<sup>1</sup> and Robert H. Dorwart<sup>1, 2</sup>

A 64-year-old man with postmeningitic ependymitis demonstrated intraventricular opacification secondary to extravasated contrast material. Leakage of contrast material was believed to be secondary to inflammatory alteration of the blood-brain barrier (BBB) of the subependymal vasculature.

## Case Report

A 64-year-old man was admitted in June 1981 for neurosurgical evaluation of a right hemifacial spasm. Two years before, an enhanced computed tomographic (CT) brain scan obtained for chronic dementia had been normal (fig. 1A). The patient underwent a Janetta procedure on June 26, 1981. Postoperatively, he was placed on steroids: 6 mg of intravenous Decadron every 6 hr followed by an oral taper regimen; this was discontinued on July 8. The postoperative course was complicated by unrelenting headache. A lumbar puncture on July 7 revealed 7,000 white blood cells/mm<sup>3</sup> and no glucose. Cultures of cerebrospinal fluid (CSF) were positive for *Serratia marcescens*. The patient was treated with 1 g of intravenous chloramphenicol every 6 hr, and parenteral and intrathecal gentamicin, with clinical improvement. CT on July 31 demonstrated enhancement of the ventricular margins consistent with ependymitis (figs. 1B and 1C). By August 10, CSF culture for a confusional episode yielded *Propionibacterium*. Chloramphenicol was given for 14 days, after which CSF cultures were sterile. Antibiotics and steroids were discontinued. The patient remained confused and agitated. An enhanced CT brain scan only was repeated on September 1, and this demonstrated high-density substance occupying the occipital horns of the lateral ventricles. CT attenuation values were similar to those of blood, and consideration was given to an intraventricular hemorrhage. Therefore, an unenhanced CT brain scan was obtained on September 3, and this revealed soft-tissue sludge settling within the occipital horns. The CT attenuation values of this sludge were nearly equal to that of surrounding brain parenchyma. Because the patient's clinical picture was inconsistent with intraventricular hemorrhage and because of the confusing CT findings, repeat unenhanced and enhanced scans (figs. 1D and 1E) were obtained on September 8. These demonstrated filling of the occipital horns by soft-tissue sludge, with extravasation of contrast material into the occipital horns on the enhanced scan. The findings were identical to those on scans from September 1 and 3.

The patient was observed to make gradual improvement off medication and was discharged for outpatient care. Follow-up scans were not obtained.

## Discussion

In the brain, abnormal contrast enhancement or opacification occurs by two mechanisms: extravasation of contrast material from the intravascular space or a localized pathologic increase in blood flow. The latter may result from dysautoregulation or increased vascularity. Extravasation of contrast material is due to alteration of the BBB [1]. The normally continuous basement membrane and endothelial intercellular tight junctions may lose their integrity in pathologic states. In meningitis, pial vessels and others are involved in the inflammatory reaction.

The CT scan in leptomenigeal infections may be normal. When abnormal, findings associated with meningitis include abnormal enhancement of the basal and convexity meninges and intraparenchymal zones of diminished attenuation and irregular contrast enhancement. These latter findings represent a focus of encephalitis. Complications of meningitis that can be detected on CT scans include subdural effusions or empyema, ventricular enlargement, encephalomalacia, abscess [2], and ventriculitis [3].

Acutely, with purulent ventriculitis, the ependymal surface may be lined with neutrophils and fibrin [4]. With healing, ependymal adhesions or small subependymal foci of gliosis may occur. The latter, also termed granular ependymitis [5], are small hummocks of neuroglial fibers that may break through the ependymal lining. They usually rise no further than 0.5 mm above the level of the ependyma [6]. Neovascularity in these areas presumably is associated with alteration in the BBB.

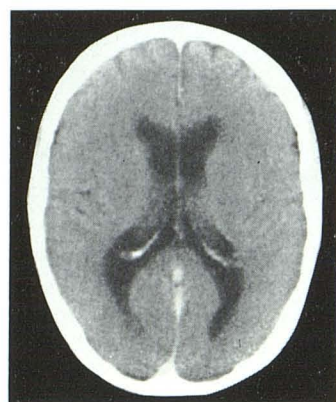
Enhancement of the lateral margins of the bodies of the lateral ventricles is normally seen and is thought to be secondary to enhancement of subependymal veins and/or the body of the caudate nucleus [7]. However, enhancement of the margins of the occipital horns of the lateral ventricles is not a normal finding. There have been infrequent reports of enhancement of the cerebral ventricles in inflammatory disease. Lee and Zimmer [8] observed ventricular opacification in two infants, one asymptomatic and one with fatal anoxic brain damage. They did not observe ventricular opacification in adults. Scotti and Harwood-Nash [9] asserted their observation of ependymal enhancement with

Received July 15, 1982; accepted after revision October 19, 1982.

<sup>1</sup>Department of Radiology/SGHQRD, Wilford Hall USAF Medical Center, Lackland AFB, TX 78236. Address reprint requests to W. T. Sullivan.

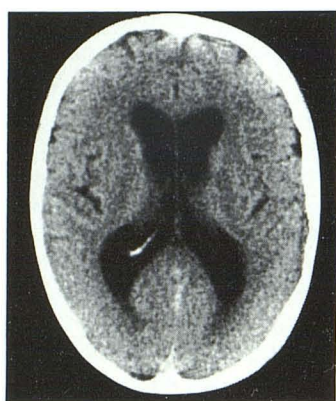<sup>2</sup>Present address: Department of Radiology/Nuclear Medicine, Uniformed Services University of Health Sciences School of Medicine, Bethesda, MD 20814.



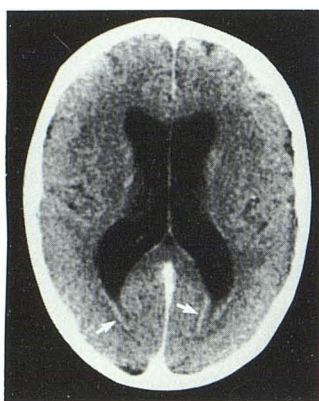


A

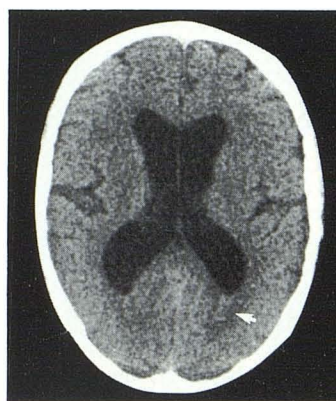Fig. 1.—A, Normal baseline axial CT scan at level of lateral ventricles in workup of chronic dementia. B, Unenhanced scan 2 years later for meningitis. Occipital horns of lateral ventricles are normal. C, After contrast administration. Linear enhancement of ependymal margins of occipital horns of lateral ventricles. D, Unenhanced scan 1½ months later for persistent confusion and agitation. Soft-tissue sludge in occipital horns of left (arrow) and right lateral ventricles is nearly isodense with surrounding brain parenchyma and represents necrotic cellular debris. (Identical findings were present on unenhanced scan 5 days before.) E, Enhanced scan immediately after D. Opacification of occipital horns of lateral ventricles by contrast extravasated into ventricular system. Meniscus (arrow) is formed by posterior layering of contrast. (Identical findings were present on enhanced scan 7 days before.)



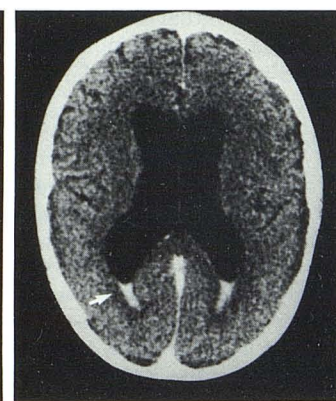
B



C



D



E

contrast leakage into the ventricles but did not provide case material. No other example of ventricular enhancement in adults was found in our literature search.

Our case represents intraventricular extravasation of contrast material in the setting of known meningitis and presumed ependymitis. Prone scans or other positional alterations would have been of value in further demonstrating a fluid-fluid level. It is interesting that the observation was made at a time of improving clinical status, sterile CSF cultures, and when the patient was not receiving steroids. Perhaps the stabilizing effects of steroids on vascular endothelium are responsible for the absence of this finding earlier in the patient's course. The inflammatory changes in the subependymal vasculature and reduced integrity of the BBB are believed to have permitted contrast extravasation into the occipital horn in this case. Enhancing soft-tissue density in the occipital horns probably represents necrotic cellular debris and not granulation tissue, since the secondary gliosis of the ependymal lining does not characteristically extend more than 0.5 mm above the ependyma [6].

In the clinical setting of meningitis and ependymitis, there is a potential pitfall in the interpretation of enhanced CT brain scans when no unenhanced scan is obtained. The layering of iodinated contrast material within the ventricular system might be construed as intraventricular hemorrhage. Correlation of this CT finding with the patient's clinical status

will sometimes help the interpreter avoid this error. However, an unenhanced scan should be obtained 24 hr after the enhanced scan to clarify the source of the substance within the ventricles. Routine use of both unenhanced and enhanced CT scans in the evaluation of inflammatory conditions of the brain remains prudent practice [10].

#### ACKNOWLEDGMENT

We thank Lee Greenwood for manuscript review and Naomi Jordan for assistance in manuscript preparation.

#### REFERENCES

1. Sage M. Blood-brain barrier: review. *AJNR* 1982;3:127-138, *AJR* 1981;138:887-898
2. Cockrill HH Jr, Driesbach J, Lowe B, Yamanouchi T. Computed tomography in leptomenigeal infections. *AJR* 1978;130:511-515
3. Warmser GP, Shashan A. Ventriculitis complicating Gram-negative meningitis in an adult. *Mt Sinai J Med (NY)* 1980;47:575-578
4. Slager UT. *Basic neuropathology*. Baltimore: Williams & Wilkins, 1970
5. Norman R. Normal structure and general pathology of the nerve cell and neuroglia (revised by Blackwood D). In: Blackwood W, Corsellis JAN, eds. *Greenfields neuropathology*. Chi-

- cago: Year Book Medical, **1976**:1-42
6. Harriman DGF. Bacterial infections of the central nervous system. In: Blackwood W, Corsellis JAN, eds. *Greenfields neuropathology*. Chicago: Year Book Medical, **1976**:238-268
  7. Naidich TP, Pudlowski RM, Leeds NE, Naidich JB, Chisolm AJ, Rifkin MD. The normal contrast-enhanced computed axial tomogram of the brain. *J Comput Assist Tomogr* **1977**;1:16-29
  8. Lee BCP, Zimmer J. Ventricular opacification after intravascular injections of contrast material. *Radiology* **1978**;128:647-649
  9. Scotti G, Harwood-Nash DC. Leakage of contrast into a postmeningitic subdural effusion: a CT finding. *Neuroradiology* **1980**;20:95-98
  10. Latchaw RE, Gold LHA, Tourje EJ. A protocol for the use of contrast enhancement in cranial computed tomography. *Radiology* **1978**;126:681-687