



## Discover Generics

Cost-Effective CT & MRI Contrast Agents



WATCH VIDEO

# AJNR

## "Squirt-pull" technique for left carotid catheterization.

F J Hahn

*AJNR Am J Neuroradiol* 1983, 4 (5) 1129

<http://www.ajnr.org/content/4/5/1129.citation>

This information is current as  
of June 23, 2025.

# “Squirt-Pull” Technique for Left Carotid Catheterization

Francis J. Hahn<sup>1</sup>

The technique of carotid angiography using a “sidewinder” femorocerebral catheter [1] has proved satisfactory in most instances. However, left carotid catheterization is still difficult and may prolong the procedure time. A simple “squirt-pull” technique facilitates catheter placement in the left carotid during cerebral angiography.

## Technique

Using the Seldinger technique in a percutaneous femoral approach, a 7 French sidewinder femorocerebral catheter is advanced over a movable-core safety J guide wire [2] to the aortic arch, where catheterization of the left carotid is attempted initially by the conventional open-loop method with withdrawal hooking of the arterial orifice.

When difficulty is encountered, the following technique can be used: The catheter tip is placed midway between the innominate artery and the left common carotid artery (fig. 1A, position 1) or midway between the left subclavian artery and the left common carotid artery (fig. 1B, position 1). Under fluoroscopic guidance, about 7 ml of contrast material is injected rapidly by means of a 10 ml syringe. The force of injection causes the catheter tip to be medially deflected (fig 1, position 2). The deflected catheter tip approaches the opening of the left common carotid artery, allowing the

artery to be opacified. While the contrast material is being injected, the catheter is gently pulled. Preferentially it will follow the flow of the contrast material into the left common carotid artery. If this fails to occur initially, repeat attempts are usually successful.

The most common hindrance in attempts to catheterize the left carotid artery is atherosclerotic plaques surrounding the orifice. To facilitate catheterization of the irregular orifice without damage, the squirt-pull technique can be used. In the author's experience, this technique allows the catheter to be placed in the left carotid with less trauma than with other techniques and also saves procedure time.

## ACKNOWLEDGMENTS

We thank Lloyd L. Barta and Phoebe Kaplan for assistance in manuscript preparation.

## REFERENCES

1. Simmons CR, Tsao EC, Thompson JR. Angiographic approach to the difficult aortic arch: a new technique for transfemoral cerebral angiography in the aged. *AJR* 1973;119:605-612
2. Judkins MP, Kodo HJ, Frische LH, Dotter CT. Lumen-following safety J-guide for catheterization of tortuous vessels. *Radiology* 1967;88:1127-1130

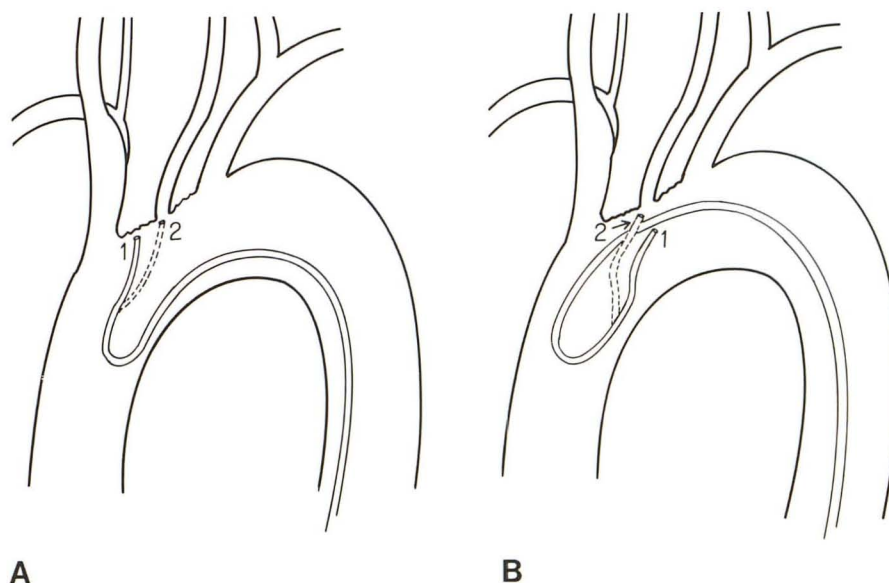


Fig. 1.—7 French sidewinder femorocerebral catheter in aortic arch with catheter tip located either anterior to left common carotid artery (A, position 1) or between left common carotid and left subclavian artery (B, position 1; loop obtained by 180° rotation of catheter). Dotted profile (position 2) shows tip displacement during injection.

Received October 28, 1982; accepted after revision March 14, 1983.

<sup>1</sup> Department of Radiology, University of Nebraska Medical Center, 42d and Dewey Ave., Omaha, NE 68105.