



Discover Generics

Cost-Effective CT & MRI Contrast Agents



FRESENIUS
KABI

WATCH VIDEO

AJNR

Myelography with lopamidol.

J T Lamb and I M Holland

AJNR Am J Neuroradiol 1983, 4 (3) 851-853

<http://www.ajnr.org/content/4/3/851>

This information is current as
of June 18, 2025.

Myelography with Iopamidol

John T. Lamb¹ and Ian M. Holland¹

Two hundred patients who underwent myelography with iopamidol were independently assessed as to film quality and adverse side effects. Comparison was made with a similarly assessed group of 1,000 patients who underwent myelography with metrizamide. Diagnostic quality was generally excellent with both contrast media. The incidence of side effects, notably vomiting and headache, was significantly less with iopamidol but remains appreciable. More severe side effects may occasionally occur with either contrast medium.

Metrizamide (Amipaque) was the first nonionic contrast medium developed for myelography [1]; its advent marked a milestone. For the first time it was possible to examine the entire spinal canal with an absorbable contrast medium in relative safety. During the past 7 years over 3,000 metrizamide myelograms have been obtained in our departments without any permanent adverse sequelae. However, the high incidence of side effects, which occasionally are disturbingly severe, has been a continuing cause for concern. The present trial of iopamidol was undertaken in the hope of reducing these side effects. Iopamidol (Niopam; Bracco, Milan) is a nonionic contrast medium, stable in solution and claimed to have relatively low general and neural toxicity.

Subjects, Materials, and Methods

Two hundred consecutive and unselected adult patients who underwent myelography with iopamidol were compared with a similar group of 1,000 patients examined with metrizamide. The contrast agent was introduced into the lumbar canal in about 60% of subjects and into the cervical canal via lateral C1–C2 puncture in about 40%. The age and gender distributions were similar in the two groups. No special preparation was given other than verbal reassurance and the withdrawal of any drugs that lower the seizure threshold for 48 hr before and after the examination. Myelographic technique was standard in the two groups [2]. A 22 gauge needle was usually used. The total amount of contrast medium injected never exceeded 3.5 g and was usually well below 3.0 g. Concentrations varied according to the particular problem but were generally 170–220 mg I/ml. Great care was taken to prevent or minimize entry of contrast material into the cranial cavity. Clear instructions on aftercare ensured that the patient remained in sitting or semireclining position for 6 hr after the myelographic examination.

Films were independently assessed for quality with particular regard to the delineation of the spinal cord and of small structures

such as the rootlets and root sleeves.

The protocol for the prospective study included a complete neurologic examination both before and at 6 and 24 hr after myelography. Patients in whom this protocol could not be observed (e.g., those submitted to surgery within 24 hr) were excluded from the study. The neurologic examination included an attempt to elucidate any neuropsychologic reaction; an analysis of these not infrequent reactions will form the basis of a later communication. In an independent assessment of side effects, particular care was taken first to obtain the patient's unprompted opinion as to his tolerance of the procedure.

Results

Independent comparison of radiographs taken with the two contrast media showed that diagnostic quality was generally excellent with both metrizamide and iopamidol. Quality was improved by avoiding too dense a concentration of contrast material and by paying careful attention to radiographic factors such as low kilovoltage techniques. Figures 1 and 2 illustrate myelograms obtained with iopamidol.

No patient in either group experienced any permanent adverse reaction or complication attributable to myelography.

The comparative incidence of individual side effects is illustrated in figure 3. Headache, anorexia, nausea, and vomiting were all significantly less frequent with iopamidol than with metrizamide. The most common complaint with both media was headache; figure 4 gives the comparative statistics for the two media and shows that not only the incidence but also the severity of headache is less with iopamidol than with metrizamide. The onset of headache, which is typically delayed for several hr, tended to appear sooner with iopamidol than with metrizamide.

In both groups side effects were significantly more frequent in females and less frequent with direct cervical injection than after lumbar introduction. The overall incidence of side effects was 41% with iopamidol and 56% with metrizamide.

Serious side effects occurred in 8% of the iopamidol series and 12% of the metrizamide series. The most common serious side effect was severe, often prolonged headache (fig. 4); other serious side effects included adverse mental reactions ranging from confusion and nightmares to severe agitation and hallucinatory psychotic syndromes. These occurred in 3% of the metrizamide series and in 0.5% of the iopamidol series (one patient). One patient in the iopamidol series developed myoclonus of the hands after cervical myelography. No myoclonus occurred in the metrizamide series and no seizures occurred in either group. Other serious side effects encountered in both groups included pyrexia, severe neck stiffness,

¹ Department of Neuroradiology, The General Infirmary, Great George St., Leeds LS1 3EX, England. Address reprint requests to J. T. Lamb.

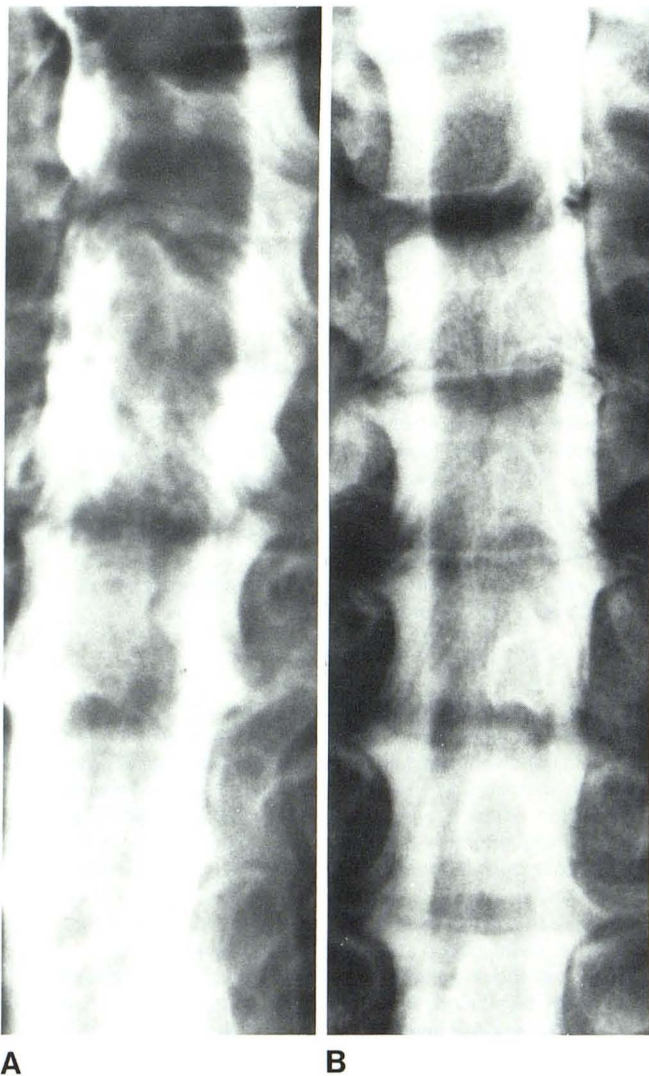

Fig. 1.—Cervical myelograms obtained with iopamidol. Normal spinal cord and rootlets. A, Oblique projection. B, Patient prone.

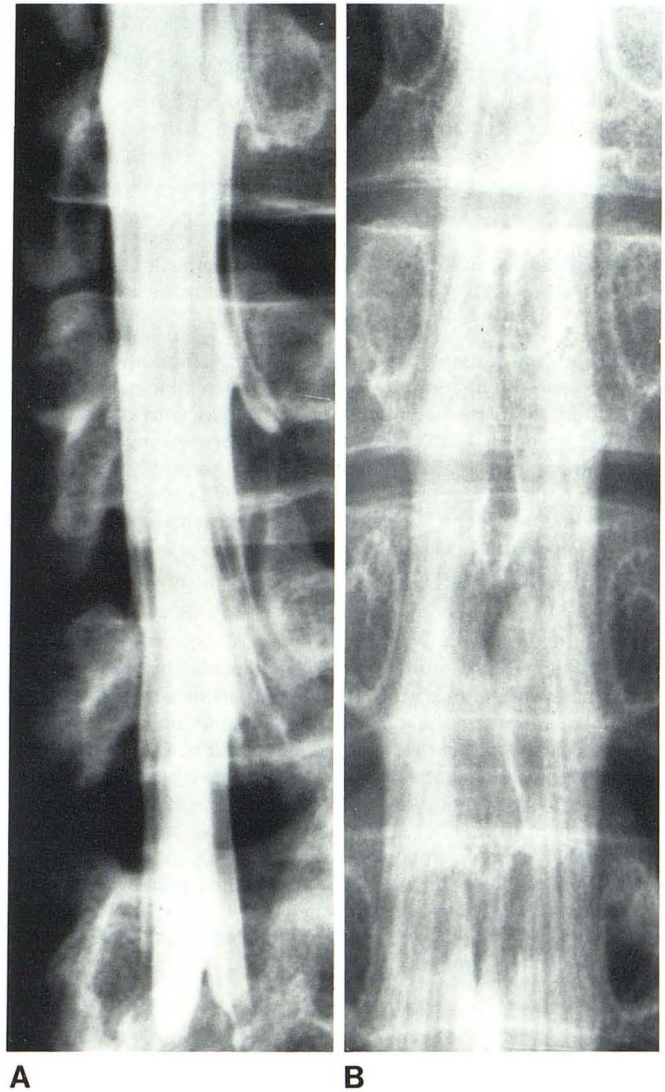


Fig. 2.—Lumbar myelograms obtained with iopamidol. A, Root sleeves. Root anomaly at L4–L5 level. B, Normal conus and cauda equina.

and backache. Two patients in the metrizamide group were found to have sterile meningitis, presumed chemical in origin; they made a complete recovery.

Six patients from the iopamidol group subsequently underwent repeat myelographies; none showed evidence of arachnoiditis.

Discussion

The disadvantages of myelography with oil-based contrast media, namely, inadequate visualization of fine detail and the development of adhesive arachnoiditis, have not been encountered with the newer nonionic, water-soluble contrast media. The improved diagnostic potential and the absence of arachnoiditis associated with metrizamide myelography are believed to be related to the nonionic nature of this medium and its resultant low osmolality. However, the high incidence of side effects observed after metrizamide myelography, although admittedly usually minor and short-term, has been

a continuing cause for concern, as has been the occasional occurrence of disturbingly severe side effects.

The development of another nonionic contrast medium, iopamidol (Bracco, Milan), which was also reported to have low neurotoxicity, encouraged us to compare this substance with metrizamide as to its diagnostic potential and the incidence of side effects. Our comparison of radiographs with the two media has shown them to be of equal diagnostic quality, as might have been expected from their similar iodine content and physical characteristics. Hammer and Lackner [3] reported similar results. The slight incidence of side effects with iopamidol, significantly reduced as compared with metrizamide, is unexplained; our findings are similar to those of McAllister (V. McAllister, unpublished data), who conducted a double-blind comparison of the two media in lumbar radiculography. The development of myoclonus in one patient who underwent iopamidol myelography and the complete absence of this complication in our much larger series of metrizamide myelographies is also unexplained.

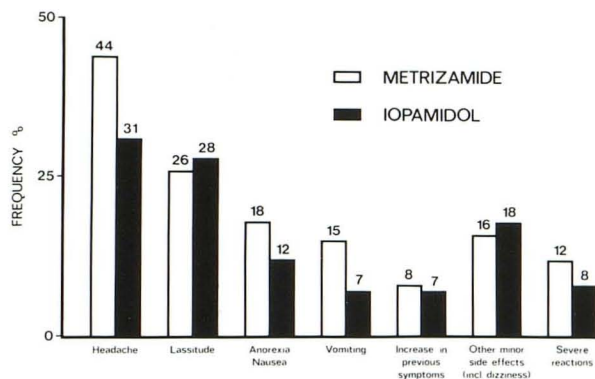


Fig. 3.—Incidence of various side effects after myelography with metrizamide and iopamidol, respectively.

We consider iopamidol to be a relatively safe myelographic contrast agent when properly administered. A total dose of 3.0 g should only rarely be exceeded, and most examinations should be performed with 2.5 g or less. Concentrations should not exceed 300 mg I/ml, and most examinations should be performed with lower concentrations. The incidence of side effects, particularly headache, anorexia, nausea, and vomiting, is significantly less with iopamidol than with metrizamide. Nevertheless, 41% of patients will experience side effects, predominantly minor in nature. Eight percent will suffer more serious side effects.

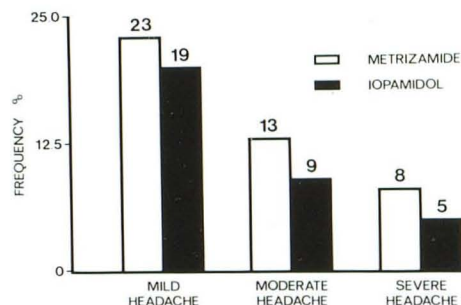


Fig. 4.—Incidence of severity of headache after myelography with metrizamide and iopamidol, respectively.

REFERENCES

1. Almen T. Contrast agent design. Some aspects of the synthesis of water soluble contrast agents of low osmolality. *J Theor Biol* 1969;24:216-226
2. Grainger RG, Lamb JT. *Myelographic techniques with metrizamide*. Birmingham, England: Nyegaard UK, 1980:31-36, 59-73
3. Hammer B, Lackner W. Iopamidol, a new non-ionic hydrosoluble contrast medium for neuroradiology. *Neuroradiology* 1980;19:119-121