



Discover Generics

Cost-Effective CT & MRI Contrast Agents



FRESENIUS
KABI

WATCH VIDEO

AJNR

Focused encephalography.

G Ruggiero and M Manfredini

AJNR Am J Neuroradiol 1983, 4 (3) 767-769

<http://www.ajnr.org/content/4/3/767>

This information is current as
of June 6, 2025.

Focused Encephalography

Giovanni Ruggiero¹ and Manuela Manfredini¹

Focused encephalography is a diagnostic procedure performed after computed tomography (CT) that can be specifically focused on diagnostic problems not solved by CT. The authors have used the procedure in 20 cases, and it has proved to be quick, risk-free, and without serious side effects. It provides useful supplementary diagnostic information, and can be especially helpful when CT is not available or when the CT scanner is an early-generation model.

Computed tomography (CT) has reduced tremendously the number of encephalographies, but encephalographies are still used for some purposes, especially in those departments not equipped with the recent CT machines that allow reconstruction in coronal and sagittal planes. These purposes include lesions in the brainstem, posterior fossa, and suprasellar regions [1], and functional, dynamic studies of the cerebrospinal fluid pathways. Encephalography is a difficult procedure and requires skillful neuroradiologists. Moreover, it is widely believed that this technique is highly invasive. However, we consider encephalography to be a rather safe procedure when performed in the proper manner [2, 3]. Encephalographic techniques and materials have improved in recent years [4, 5]; moreover, CT is neither risk-free nor without side effects in all cases [6].

However, it would still be inconceivable to perform encephalography before CT, and just as unthinkable to perform encephalography that for the most part duplicates CT data already obtained. Encephalography must first consider all the information provided by CT (even if it has not been sufficient for diagnosis). Then encephalography can be directed to the unsolved problem and focused on one region. Very small amounts of air and a limited number of

encephalograms are usually sufficient using this approach, and the examination can therefore be carried out safely and quickly.

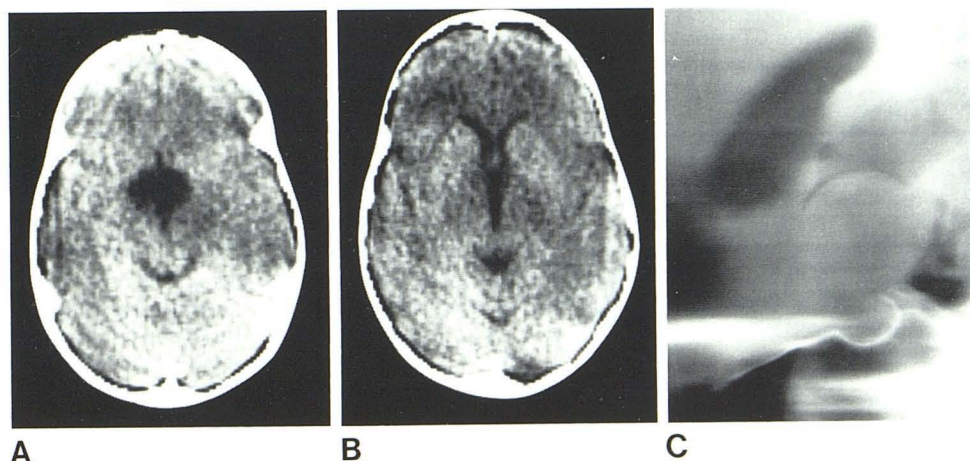
Materials and Methods

Twenty patients (including two under general anesthesia) were examined using our technique. The examinations were all performed by the same radiologist, who monitored the patients for 3 days. The amount of air injected ranged from 5 to 30 cm³ (average, 16 cm³), and the number of pictures obtained ranged from three to 21 (average, eight). The duration of the procedure was calculated in two ways: as the time the intrathecal needle remained inserted (usually considered the most dangerous part of the encephalography); and as the total time for its performance, including encephalograms. The average duration of these two parts of the technique was 8 and 15 min, respectively; however, those figures are unrealistically high because in one case the examination times were long (23 and 35 min) due to a breakdown of the machine. For this reason the number of encephalograms and the amount of air injected were relatively high in this case as well. In most cases the examination lasted less than 5 min for the first part and less than 10 min for the entire procedure, with fewer than 10 encephalograms obtained and less than 15 cm³ of air injected.

Results

The most frequent side effect observed was headache, with 13 of 18 conscious patients reporting it. Except for four cases, the headache lasted for only a few hr after the examination. Headache

Fig. 1.—Case 7: craniopharyngioma. CT shows rounded hypodensity in region of suprasellar cisterns (A), while inferior portion of third ventricle appears normal (B). Focused encephalography (C) shows huge tumor with large suprasellar extension and displacement of brainstem posteriorly. Because of this additional information, patient was operated by intracranial approach.



¹Department of Neuroradiology, Bellaria Hospital, Via Altura 3, 40139 Bologna, Italy. Address reprint requests to G. Ruggiero.

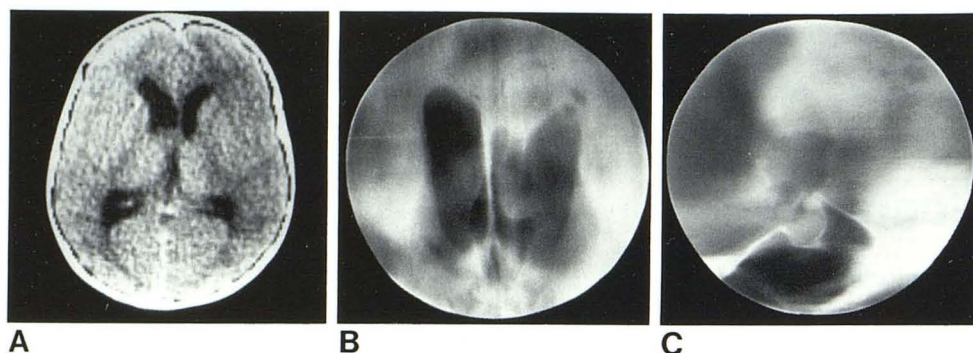


Fig. 2.—Case 15: colloid cyst of third ventricle attached to left foramen of Monro. A, CT shows deformation of posterior inferior portion of dilated left frontal horn. B and C, Focused encephalography is pathognomonic due to typical deformation of third ventricle.

TABLE 1: Summary of Diagnostic and Clinical Results after CT and after Encephalography

Case No.	Diagnosis after CT	Unanswered Question(s)	Answer after Focused Encephalography
1	Recurrence of pituitary adenoma	Suprasellar extension?	No
2	Slight hypodensity at the level of sellar floor; "peculiar" suprasellar cisterns	Degree of empty sella? Communication with suprasellar cisterns?	Same size as shown by CT Yes
3	Hydrocephalus; fourth ventricle deformed?	Tumor in posterior fossa?	Yes, probably in fourth ventricle
4	(No CT available)	Sellar tumor?	No
5	Poroencephalia?	Communication between ventricles and subarachnoid space? Shunt?	No No
6	Intrasellar tumor	Suprasellar extension?	No
7	Suprasellar cyst	Suprasellar tumor or arachnoid cyst?	Tumor. Craniopharyngioma?
8	Craniopharyngioma	Degree of suprasellar extension?	Intracerebral suprasellar tumor, probably optic glioma
9	Recurrence of pituitary adenoma	Suprasellar extension?	No
10	Hypodensity in posterior fossa	Cyst? Tumor?	Cystic extracerebral expansive process in the cerebellopontine angle)
11	Postoperative cystic herniation	Communication with ventricles? Indicated shunt?	Yes No
12	Suprasellar calcific tumor	Size? Intra- or extracerebral?	Diffuse Intracerebral
13	Recurrence of pituitary adenoma	Suprasellar extension?	Yes
14	Hyperdensity, positive CT	Tumor?	No
15	Hydrocephalus: dilated and unshaped fourth ventricle	Posterior fossa tumor? Review after focused encephalography: foramen of Monro tumor?	No Yes: colloid cyst?
16	Clinically suspected brainstem tumor (CT negative)	?	Certainly no tumor
17	Hydrocephalus	Aqueduct stenosis?	Yes
18	(No CT available, epilepsy)	Temporal periventricular gliosis?	No
19	Vertigo with negative CT	Posterior fossa arachnoiditis?	No
20	Right optic glioma?	Retroorbital and suprasellar extension?	No

was mild to moderate in all but three cases. Lumbar pain, fever, and vomiting were each experienced by two patients, and five patients reported no side effects. The clinical and diagnostic results of this study are summarized in table 1 and the most interesting cases are illustrated in figures 1–3.

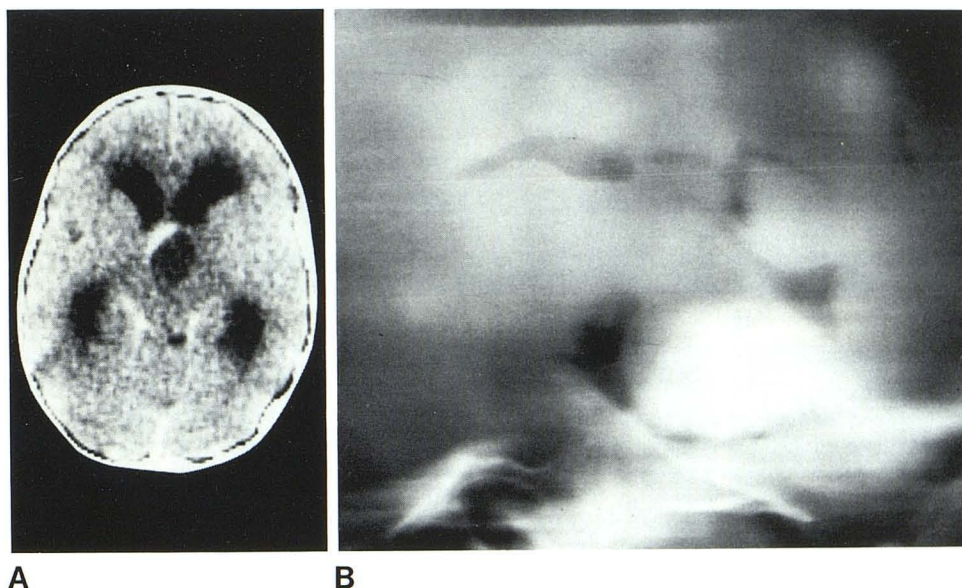
Discussion

Focused encephalography is a very benign procedure. It is short, risk-free, and without serious side effects. Although superseded for the most part by CT, we believe it retains an important role as a

diagnostic tool. It provides information that can complete a CT diagnosis and that can be especially useful to a surgeon for choosing the optimal operative technique. In addition, focused encephalography can be useful in those departments that do not have newer-generation CT machines or in cases when the CT scanner is unavailable and the patient cannot wait.

Perhaps its greatest weakness lies in the physician performing the examination. Increasingly fewer radiologists know encephalographic techniques; those who do are usually older neuroradiologists. We believe the teaching of this elegant but difficult technique should be continued, at least in larger departments.

Fig. 3.—Case 8: optic glioma. A, CT shows ballooned hypodensity partially enhanced in region of third ventricle, suggesting cystic craniopharyngioma. B, Focused encephalography demonstrates large intracerebral tumor, probably suprasellar glioma.



REFERENCES

1. Ruggiero G, Cristi G, Federico F, Sabattini L. Pneumography in supratentorial space-occupying lesions. In: Diethelm L, Wende S, eds. *Encyclopedia of medical radiology*. Berlin: Springer-Verlag, 1977:203-330
2. Ruggiero G, Cristi G, Trevisan C. Clinical aspects of encephalography. *Acta Radiol [Suppl]* (Stockh) 1969;292:1-56
3. Ruggiero G, Bories J, Calabrò A, et al. *Radiological exploration of the ventricle and subarachnoid space*. Berlin: Springer-Verlag, 1974
4. Ruggiero G, Sabattini L, Nuzzo G. C.T. and encephalography. *Neuroradiology* 1977;13:45-49
5. Ruggiero G, Sabattini L. C.T. and encephalography. In: Bories J, ed. *The diagnostic limitations of computerized axial tomography*. Berlin: Springer-Verlag, 1978:132-155
6. Ruggiero G. Is C.T. really a non-invasive technique? *Radiologie J CEPUR* 1981;1:161-165