



## Discover Generics

Cost-Effective CT & MRI Contrast Agents



WATCH VIDEO

# AJNR

### **Three-dimensional neuroanatomic images in CT-guided stereotaxic neurosurgery.**

C Giorgi, G Broggi, G Garibotto, A Passerini, U Cerchiari, M G Abele and M Koslow

*AJNR Am J Neuroradiol* 1983, 4 (3) 719-721

<http://www.ajnr.org/content/4/3/719>

This information is current as of June 21, 2025.

# Three-Dimensional Neuroanatomic Images in CT-Guided Stereotaxic Neurosurgery

C. Giorgi,<sup>1</sup> G. Broggi,<sup>1</sup> G. Garibotto,<sup>1</sup> A. Passerini,<sup>2</sup> U. Cerchiari,<sup>3</sup> M. G. Abele,<sup>4</sup> and M. Koslow<sup>5</sup>

A technique is described for three-dimensional reconstruction of human diencephalic structures based on information contained in a widely used stereotaxic brain atlas. Various methods of graphically representing the obtained diencephalic volumes are discussed and examples are given. The anatomic information contained in the computerized atlas can be implemented with computed tomography performed under stereotaxic conditions. Volume data provided by the tomograms are used for three-dimensional "stretching" of the volumes presented in the atlas. Improved accuracy in identifying "invisible" diencephalic targets in functional stereotaxic neurosurgery is expected to result from this new technique.

Stereotaxy is a technique that allows the neurosurgeon to reach deep-seated targets in the brain without direct visualization. Targets that are directly visible on computed tomographic (CT) images, arteriograms, and ventriculograms can be easily located within the reference of a stereotaxic frame when the stereotaxic operation involves tumor biopsy, interstitial radiation, or interventricular shunting. The same technique can be used to reach brain structures whose positions can only be inferred from anatomic reference points identified on radiologic examinations. These are thus "invisible" targets that are defined by their functional properties, rather than by tissue density characteristics. Surgery for motor disorders, spasticity, pain, and epilepsy is directed toward these targets, whose positions are indicated on the stereotaxic brain atlases [1, 2]. These atlases show the subsections of diencephalic regions involved in this type of surgery; the functional subdivisions of the thalamus and basal ganglia are accurately identified by their spatial relation with the "visible" reference structures.

CT performed under stereotaxic conditions [3] has been widely used to reach visible targets within the stereotaxic frame. We have extended this extraordinarily accurate technique to include the invisible targets of functional stereotaxic operations [4, 5].

## Technique

The set of parallel sections of diencephalic structures illustrated in the atlas of Shaltenbrand and Wahren [2] (fig. 1A) was converted to numeric form by means of a digitizing board. The resulting maps (fig. 1B) contain all the subdivisions indicated in the atlas, but for

practical purposes further processing is performed so that only the outlines of the main diencephalic structures, which share anatomic or functional properties, are shown. Color coding is useful for identifying the various regions. The same system was used to identify small subnuclei that are occasionally targets for stereotaxic operations (fig. 1C). The original set of parallel frames was then aligned along the x axis, their distance being that indicated in the atlas. Owing to nonuniform spacing of the sections of the atlas, three-dimensional interpolation was performed to reconstruct the volume, which was selected as the minimum distance between successive sections in the atlas (i.e., 0.5 mm). Linear interpolation was used separately to reconstruct in intermediate planes; this was done individually for each structure. In order to satisfy the theoretic limits of the digital signal processing, three-dimensional low-pass filtering of the reconstructed volume was performed to reduce the band-width of the signal uniformly to the maximum distance between successive sections. By this method no artifacts were introduced in the three-dimensional images, although some detail was lost (fig. 2).

The reconstructed volume images obtained from these processes (fig. 3) can be arbitrarily sectioned to show the anatomy of the region of interest along planes that contain the stereotaxic probe. This in fact very seldom lies in one of the planes illustrated in the atlas. Figure 4B shows an example of a computer-generated map drawn along a plane perpendicular to the probe at the Vci-Vce target (thalamic sensory relay nuclei). A corresponding map from a semihorizontal section in the atlas is reproduced for comparison (fig. 4A).

## Discussion

The reformatted anatomic information from the stereotaxic atlas cannot be used in its original form owing to individual variability. However, the advent of a computerized stereotaxic scanner featuring high spatial resolution along the three axes will greatly increase the importance and usefulness of a numeric atlas. The images generated by a surgical scanner under development at the Imaging Science Center of the New York University Medical Center (fig. 5) will provide a large set of anatomic reference points with which the atlas can be scaled to the patient's anatomy [6]. We anticipate that this will offer a more precise method of anatomic verification of neurophysiologic data obtained during the course of stereotaxic procedures. Neurophysiologic data recorded during the procedure

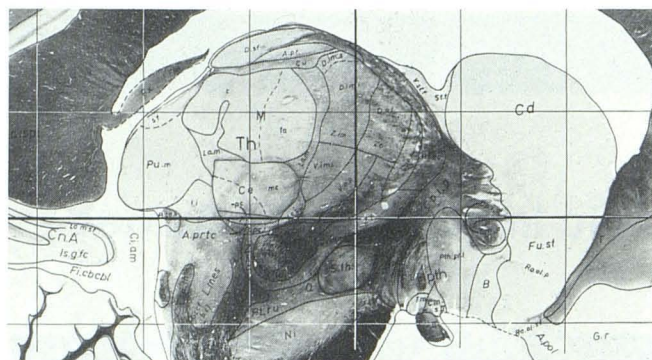
<sup>1</sup>Division of Neurosurgery, Istituto Neurologico "C. Besta," 11 via Celoria, 20133 Milan, Italy. Address reprint requests to C. Giorgi.

<sup>2</sup>Division of Neuroradiology, Istituto Neurologico "C. Besta," 20133 Milan, Italy.

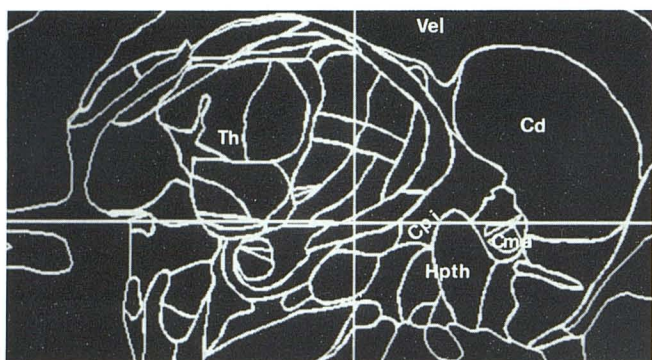
<sup>3</sup>Department of Physics, Istituto Nazionale dei Tumori, Milan, Italy.

<sup>4</sup>Department of Radiology, New York University Medical Center, New York, NY 10016.

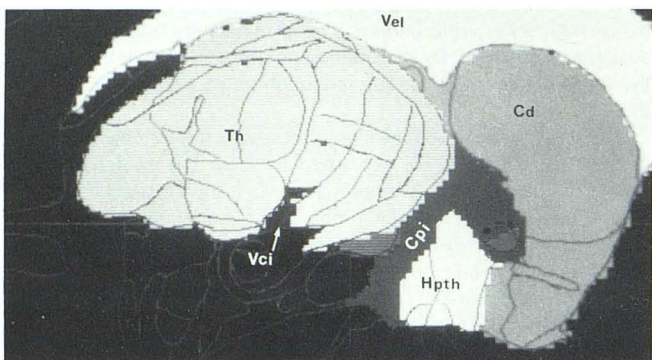
<sup>5</sup>Department of Neurosurgery, New York University Medical Center, New York, NY 10016.



A



B



C

Fig. 1.—Stereotaxic diagrams of diencephalic structures. Sagittal section 9 mm lateral from origin of intercommissural reference system. **A**, Reprinted from [2]. **B**, Digital conversion showing contours of various regions and structures. **C** shows effect of color-coding or shading major regions of interest within which a given substructure (arrow) can be "recalled." Vel = lateral ventricle; Th = thalamus; Cd = caudate nucleus; Cpi = internal capsule; Cma = anterior commissure; Hpth = hypothalamus; Vci = sensory relay nuclei.


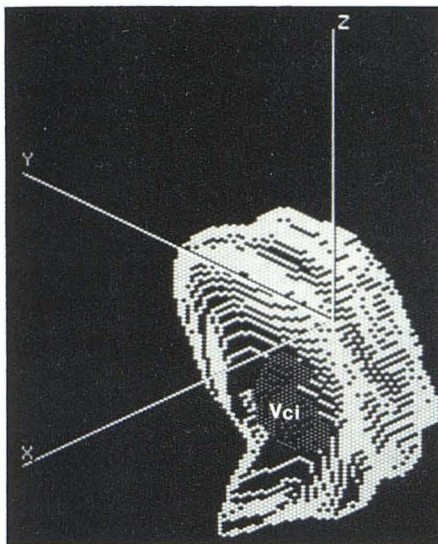


Fig. 2.—Series of parallel sagittal sections after color-coding, interpolation, and filtering.

can then be presented in numeric form, located spatially within the anatomic frames of the atlas, and continuously enlarged with successive procedures.

#### REFERENCES

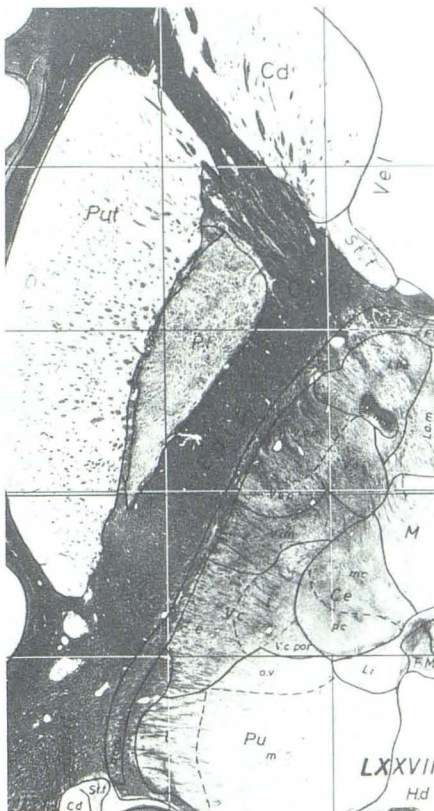
1. Andrew J, Watkins ES. *A stereotactic atlas of the human thalamus and adjacent structures*. Baltimore: Williams & Wilkins, 1969
2. Schaltenbrand G, Wahren W. *Atlas for stereotaxy of the human brain*, 2d ed. Stuttgart: Thieme, 1977
3. Boëthius J, Bergström M, Greitz T. Stereotactic computerized tomography with a GE 8800 scanner. *J Neurosurg* 1980;52:794-800
4. Garibotto G, Garozzo S, Micca G, Piretta G, Giorgi C. Three dimensional digital signal processing in neurosurgical applications. In: *Proceedings of the International Conference on Digital Signal Processing*. 1981
5. Giorgi C, Garibotto G, Garozzo S, Micca G, Piretta G. Three dimensional processing of a stereotactic brain atlas. *Appl Neurophysiol* 1982;45:419-425
6. Koslow M, Abele MG, Griffith RC, Mair GA, Chase NE. Stereotactic surgical system controlled by computed tomography. *Neurosurgery* 1981;8:72-82



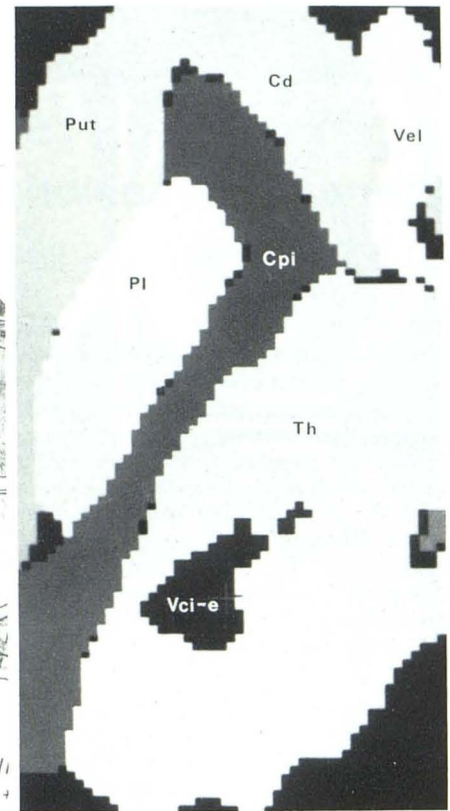
3

Fig. 3.—Thalamus with sensory relay nuclei (Vci). Reconstructed volume image (after interpolation and filtering).

Fig. 4.—**A**, Semihorizontal section reprinted from stereotaxic brain atlas [2]. **B**, Corresponding computer-generated map obtained by sectioning of volume image derived from series of sagittal sections. Put = putamen; Cd = caudate nucleus; Vel = lateral ventricle; Pl = pallidum; Cpi = internal capsule; Th = thalamus; Vci-e = sensory relay nuclei.



4A



4B

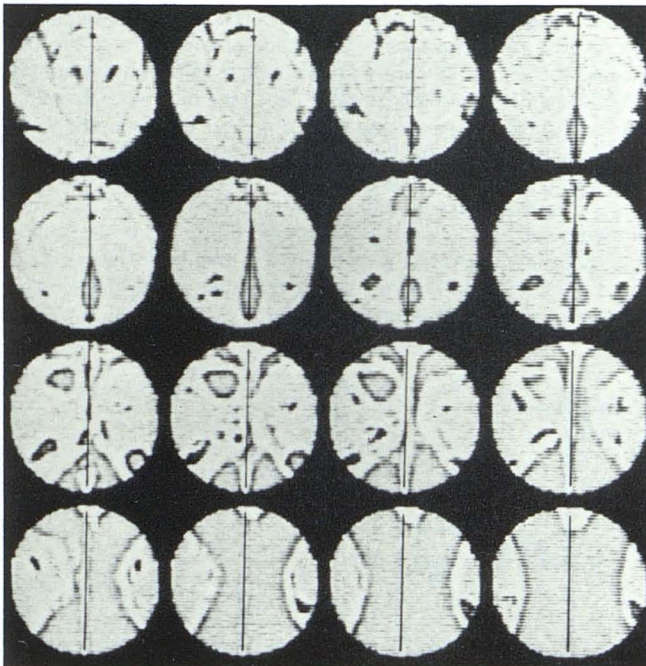


Fig. 5.—Sequence of sections generated by laboratory prototype model of neurosurgical stereotaxic scanner. Reconstructed images show diencephalic region around third ventricle at 2 mm intervals.