



## Discover Generics

Cost-Effective CT & MRI Contrast Agents



FRESENIUS  
KABI

WATCH VIDEO

# AJNR

## Cerebral cysticercosis with reference to the natural history of parenchymal lesions.

L C Handler and B Mervis

*AJNR Am J Neuroradiol* 1983, 4 (3) 709-712

<http://www.ajnr.org/content/4/3/709>

This information is current as  
of June 14, 2025.

# Infections and Infestations

## Cerebral Cysticercosis with Reference to the Natural History of Parenchymal Lesions

Leonard C. Handler<sup>1</sup> and Ben Mervis<sup>1</sup>

The cerebral parenchymal response to degeneration of cysticerci was studied in 83 consecutive patients investigated over 5½ years. Virtually all came from an endemic region of South Africa and 67% were children. Occasionally, computed tomography (CT) delineated an inert shower of cysticerci. The humoral and tissue reactions resulting from larval death cause intense cerebral edema and granulomata, which manifest particularly in the pediatric age group. Local and diffuse cerebral edema has not been stressed before nor has its incidence been evaluated. The shortest interval between cysticercal degeneration and its granulomatous response to the final radiographic calcification was found to be 25 months.

The life cycle of *Taenia solium* is well described in the standard texts on parasitology. Man is the only definitive host of the adult tapeworm, and eggs are passed in the feces. Being coprophagous, the pig serves as a natural intermediate host. Should a person ingest eggs either through poor hygiene or because of a contaminated water or food supply, the eggs develop into the larval stage in various tissues, especially the brain. Through poor socioeconomic conditions [1] or negligence man can become an inadvertent intermediate host; however, only 50% of those infested develop clinical features [2].

It is known that viable cysticerci that develop in the ventricular system may cause a blockage and obstructive hydrocephalus. Viable cysticerci in other locations in the brain or cranial cavity are totally inert and do not evoke any reaction whatsoever [2, 3].

After a variable period (probably more than 5 years [4]) the cysticerci die and degenerate for unknown reasons [5]. Until then there is no host response. Clinical and radiologic features are entirely dependent on the host's inflammatory response to this degenerative process. Disruption of the degenerating cyst wall allows its fluid content to escape and so provokes an immune

response. The humoral component results in edema, while the tissue reaction is one of endarteritis and cellular infiltration by mononuclear cells from a peripheral zone of granulation tissue [2, 3]. As the lesions age the edema and cellular response are replaced by gliosis. A calcific focus is eventually all that is left. The change in size and tissue tension of these lesions as they undergo degeneration may be seen and palpated in those few with subcutaneous nodules [4].

Because living cysticerci provoke no host response, the point in time at which infestation occurs is unknown unless subcutaneous nodules develop *pari passu*. However, as cerebral parenchymal cysts die the inflammatory response may trigger an epileptic focus, or the edema may be such that it causes a significant rise in intracranial pressure. Other mechanisms elevating intracranial pressure are: (1) obstruction of cerebrospinal fluid (CSF) pathways by cysts; (2) the inflammatory response to their degeneration within the ventricular system or the basal cisterns (racemose cyst) [2, 3]; or (3) sheer bulk of numerous cysts [6].

### Materials and Methods

From January 1971 to June 1982, 99 patients were diagnosed with cysticercosis. During the first 6 years, the diagnosis was made in only 16 of the patients. During the next 5½ years, after the advent of computed tomography (CT) and the cysticercosis indirect hemagglutination (IHA) test, the diagnosis was made in 83 patients. This report concerns those 83 patients, 56 (67%) of whom were under 13 years of age. All had plain skull radiography. CT was performed with an EMI (180 × 180 matrix) or Elscint 905 (256 × 256 matrix) scanner. Intravenous contrast medium was administered to most in a dose of 500 mg iodine/kg body weight. Eleven patients also had an air study. Neither angiography nor myelography was needed to confirm the diagnosis.

<sup>1</sup>Department of Neuroradiology, Groote Schuur Hospital, Observatory, Cape Town 7925, South Africa. Address reprint requests to L. C. Handler.



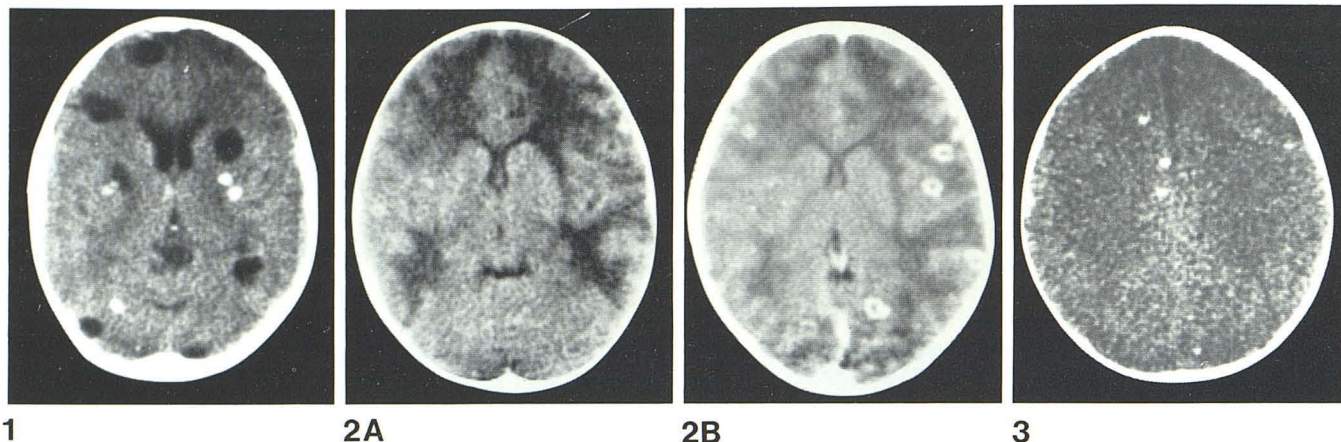


Fig. 1.—24-year-old black man with 2 year history of convulsions. This CT slice shows old calcified granulomata and six nonenhancing cysts, which represent old and recent episodes of larval infestation.

Fig. 2.—8-year-old black boy after 2 months of aseptic meningitis and sutural diastasis. **A**, Noncontrast CT. Patchy bilateral edema and small,

compressed ventricles. **B**, After contrast. Multiple granulomata with necrotic cores enhanced.

Fig. 3.—5-year-old black girl with 1 year history of convulsions. Mild CSF pleocytosis. CT without intravenous contrast shows multiple small dense granulomata not visible on skull films.

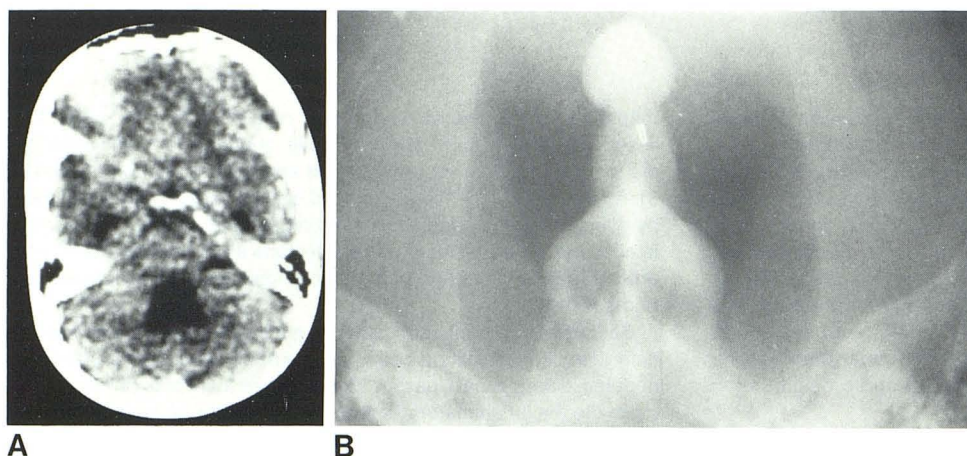


Fig. 4.—40-year-old black man with headache and sudden loss of consciousness. CSF pleocytosis. **A**, Postcontrast CT. Hydrocephalus and large fourth ventricle without demonstrable cysts. **B**, Dimer ventriculogram shows cysts as filling defects in fourth ventricle.

The mean age was 18.6 years (range, 25 months to 66 years in a woman investigated for other reasons). There was an equal distribution of males and females but the racial incidence was noteworthy in that 85% were black, 10% of mixed origin, and 5% white. Virtually all the patients came from farms or rural villages in the eastern part of the cape province (Ciskei and Transkei).

#### Criteria for Inclusion

To qualify for inclusion in this series two of the following criteria had to be met:

1. *Origin from endemic area* was almost more important than the clinical features of epilepsy or raised intracranial pressure.
2. *Multiple punctate calcific foci on skull radiographs* have long been recognized for their diagnostic importance; however, on occasion grains of sand trapped in the patient's hair may lead to an erroneous conclusion. The other causes of intracranial calcification were easily excluded by recourse to simple clinical evaluation, CSF examination, and serology.
3. *Multiple small granulomata on CT* have been described recently [7, 8]. Histologic proof linking a cysticercus to an enhancing

granuloma detected on CT has also been reported [9]. In our region the odd case of multiple cerebral tuberculomata has been recognized either at surgery or by successful response to tuberculochemotherapy.

4. *IHA test is positive* in 85% of patients with cysticercosis, although cross-reactivity with other parasitic diseases may cause confusion [10].

#### Results

##### Soft-Tissue Radiography

Calcific foci in the soft tissues were not found in any of 18 cases in which appropriate radiographs were obtained.

##### Skull Radiography

*Raised intracranial pressure:* Sutural diastasis (sometimes extremely marked) was present in 20 cases and another six had sellar changes of raised intracranial pressure. Therefore 31% had plain film evidence of raised pressure.



**Calcification:** Multiple punctate calcific foci were present in 39 cases (47%), half of whom were under 13 years of age. The youngest was a 4½-year-old girl. In a boy of 5 years, typical cysticercal calcification was detected only 25 months after a rather stormy acute edematous phase. The calcific foci were more readily recognized on the lateral skull projections than on the anteroposterior views. In six instances the classic ring calcifications were recognized, and in two of these a little dot was identified as probably representing the calcified scolex. Far more frequently, the calcific foci were rather amorphous and of variable density, with a diameter of 1–4 mm.

## CT

**Viable larvae:** Cysts were identified within the cerebrum in four patients but always in association with granulomata of varying densities. The cysts were multiple; the maximum counted in one patient was 15 (fig. 1). Slight contrast enhancement was observed around the margins of the cysts in one patient.

**Edema:** Low-density areas were identified in 20 patients. Because these black areas have the same attenuation coefficient as edema and because there was concomitant clinical evidence of raised pressure with splayed sutures on skull radiography and collapsed ventricles on CT, we termed these areas edema (fig. 2A). The edema involved the white matter and always spared the cerebral cortex. The cerebellum was not involved in any case.

All patients were under 13 years of age. The youngest proven case (positive IHA) was a black child of 26 months. The mean age was 6.2 years. The common clinical mode of presentation was with convulsions and headaches. The IHA test was positive in 13 of the 15 on whom it was done. Skull radiographs revealed sutural diastasis in 10.

The edema involved all the white matter of both hemispheres in 12 cases and was patchy in seven. In one with evidence of raised intracranial pressure it was isodense. The lateral ventricles were small or completely collapsed in 10 cases, while one manifested cerebral and cortical atrophy. In 12 cases (60%) of this group granulomata were identified in the edematous areas after contrast enhancement (fig. 2B). The incidence of associated granulomata would probably have been higher had contrast medium been administered routinely. In only one patient were the granulomata of increased density before contrast injection.

**Granulomata:** Enhancing or dense areas were identified in 24 patients, 20 (83%) of whom were under the age of 13 years. Although the mean age was slightly higher than those with edema only, it was not statistically significant. The youngest was a boy of 25 months with a 6% eosinophilia and negative Mantoux test. The IHA test was not done.

The CT appearances of these granulomatous lesions varied. In three patients with early isodense lesions identification was possible only after contrast administration, and in these three a zone of surrounding edema was also present. In 18 cases lesions of increased density enhanced after contrast injection. Surrounding edema was present in three of these. The next stage was represented by a group of three patients with high-density nonenhancing lesions about 3 mm in diameter (fig. 3). However, in none of these patients was there any calcification on the skull radiographs. The findings of end-stage calcification are reported above.

This group is similar to those with edema in that the IHA test was positive in 14 of the 16 on whom it was done. One of the two with a negative test had eosinophilia of 16%, and the other had small hyperdense granulomata and the IHA test had probably reverted. Other features of similarity were the high incidence of sutural diastasis in eight, pressure sella in three, and CT features of small or collapsed ventricles indicative of a swollen brain in 12.

Thirty-five cases (42%) of the entire group of 83 had edema and/or enhancing granulomata (i.e., an acute or subacute encephalitic phase of cysticercosis).

**Intraventricular cysticerci:** Larvae could not be identified on CT because the cyst fluid has the same attenuation coefficient as CSF (fig. 4A). Their presence in eight cases was proven on air studies.

## Air Study

Eleven patients had an air study, mostly ventriculography, with air and dimer as contrast media. (The findings, together with those of a further 13 from the period 1971–76, form the substance of a separate communication). Of relevance in the context of our CT findings was the observation that cysticerci within the ventricles were easily recognized on air or positive contrast studies because they were well outlined as filling defects (fig. 4B).

## Discussion

### Radiology

Before the advent of CT the thrust of radiologic investigations was toward identification of the cause of hydrocephalus [11, 12]. The entity of acute parenchymal cysticercosis was known, but its radiologic diagnosis was by inference in the presence of normal or small ventricles with clinical evidence of raised intracranial pressure [6, 12, 13]. Benign intracranial hypertension or chronic aseptic meningitis (viral or tuberculous) must have been better alternative diagnoses. Some authors considered that the sheer bulk of cysticerci caused the brain swelling and indentation of ventricular walls by cysts [6]. At our hospital an initial ventriculographic diagnosis of megalencephaly (enlarged brain) was made in a number of patients from the endemic areas, and two were subsequently proven to be the encephalitic phase of cysticercosis.

### Evolution and Correlation of CT Changes

By extrapolation from what is known of the pathology [2, 3] and from the two cases we have been able to study by CT over an extended interval, we believe that living cysticerci are inert and do not cause symptoms. Thus, of 83 patients we found only four with cysts, and in these the symptoms were caused either by a cohort of old granulomata or early cyst degeneration with rim enhancement. On the other hand, it has been postulated that the stage of infestation causes the inflammatory host response [6]. If this were so the cysts would be surrounded by edema and zones of contrast enhancement, and our series would have had many more examples of cysts because the patients would have been symptomatic.

As the cysts degenerate they provoke a humoral response, which in our experience is more intense in children than has been suggested previously [6, 13]; however, it has also been reported in adults [6, 11–13] prior to the advent of CT. This humoral response manifests as cerebral edema with sutural diastasis. The cellular responses of endarteritis and granulation tissue are responsible for 5–10 mm zones of contrast enhancement. These might have been found in more cases had they been diligently searched for by obtaining contiguous cuts after intravenous contrast administration. There is a case report [14] of edema without enhancing lesions, in which the lesions later appeared. In one of our children the edema progressed rapidly over 2 weeks, but the enhancing granulomata were only identified 6 months later despite contrast administration in all three studies. Early granulomata are isodense without contrast enhancement, but as the outer zone of vascular granulation tissue forms gliosis [3] the lesions become denser than the surrounding



white matter. Contrast enhancement continues for a period because of the endarteritis and the granulation tissue, which later converts to gliosis so that the lesions appear dense without contrast enhancement. Finally the gliotic nodules calcify. This is detected initially on CT, but later, as the calcium content rises, it can be seen on plain skull radiographs. In short, as a result of larval degeneration, granulomata develop and mature to end up as gliotic calcific nodules.

The time interval required to progress through these stages has been given variously as 18 months [6] to about 10 years [4]. We recognized calcification on a plain skull film in a 5-year-old 25 months after a rather stormy acute edematous phase. Demonstrable skull calcification therefore can develop in just 2 years from larval death. Because there were other young children of 4 years and younger with skull calcification we concluded that the entire inflammatory response can progress to gliosis and calcification in 1½–2 years.

Acute or subacute parenchymal involvement as manifested by edema or enhancing granulomata was present in 42% in our series. This incidence matches the pseudotumoral picture found by Obrador [12] due to cerebral edema on ventriculography, but is higher than other recent CT series [7, 15, 16]. Because two-thirds of the entire series comprised children and most had the acute or subacute encephalitic phase we suggest that one or more of the following explanations apply: (1) the antigenic stimulus (cysticercal fluid) may be greater in children because of their play habits [1]; (2) children respond differently to the antigenic stimulus; or (3) selection of patients for specialized investigation from the rural areas of the Eastern Cape may have weighted this group toward a more dramatic mode of presentation.

Recent articles on CT findings in cysticercosis report on the prevalence in Mexico [15] and in Central American immigrants in California [7, 16] but do not stress the high incidence in children as was found here [8]. Our larger series confirms our previous observation [8] that cerebral edema is far more common (about 25% of this series) than the sparse mention other reports indicate [7, 15, 16]. Diffuse cerebral edema has not been reported previously.

## REFERENCES

1. Goni PB. Cysticercosis of the nervous system. III. Clinical findings and treatment. *J Neurosurg* 1962;19:641–643
2. Marquez-Monter H. Cysticercosis. In: Marcial-Rojas RA, ed. *Pathology of protozoal and helminthic diseases with clinical correlation*. Baltimore: Williams & Wilkins, 1971:592–617
3. Adams JH. Parasitic and fungal infections of the nervous system. In: Blackwood W, Corsellis JAN, eds. *Greenfield's neuropathology*. London: Arnold, 1976:269–291
4. Dixon HBF, Lipscomb FM. *Cysticercosis: an analysis and follow-up of 450 cases*. Medical Research Council special report series, no. 299. London: Her Majesty's Stationery Office, 1961:3–47
5. Biagi F, Willms K. Immunologic problems in the diagnosis of human cysticercosis. *Ann Parasitol Hum Comp* 1974;49:509–513
6. Balasubramaniam V, Kanaka TS, Ramamurthi B. Cerebral cysticercosis in India. *Int Surg* 1971;56:172–181
7. Bentson JR, Wilson GH, Helmer E, Winter J. Computed tomography in intracranial cysticercosis. *J Comput Assist Tomogr* 1977;1:464–471
8. Mervis B, Lotz JW. Computed tomography (CT) in parenchymatous cerebral cysticercosis. *Clin Radiol* 1980;31:521–528
9. Percy AK, Byrd SE, Locke GE. Cerebral cysticercosis. *Pediatrics* 1980;66:967–971
10. Proctor EM, Powell SJ, Elsdon-Dew R. Serological diagnosis of cysticercosis. *Ann Trop Med Parasitol* 1966;60:146–151
11. Dorfsman J. Radiologic aspects of cysticercosis. *Acta Radiol [Diagn] (Stockh)* 1963;1:836–842
12. Obrador S. Cysticercosis cerebri. *Acta Neurochir (Wien)*, 1962;5:320–364
13. Stepien L. Cerebral cysticercosis in Poland: clinical symptoms and operative results in 132 cases. *J Neurosurg* 1962;19:505–513
14. Schraberg D, Weisberg L, de Urrutia JR, LaCorte WS. Cysticercosis cerebri: evolution of central nervous system involvement as visualized by computed tomography. *Comput Tomogr* 1980;4:261–266
15. Carbajal JR, Palacios E, Azar-Kia B, Churchill R. Radiology of cysticercosis of the central nervous system including computed tomography. *Radiology* 1977;125:127–131
16. Zee C, Segall HD, Miller C, et al. Unusual features of intracranial cysticercosis. *Radiology* 1980;137:397–407