

Generic Contrast Agents

Our portfolio is growing to serve you better. Now you have a *choice*.



FRESENIUS
KABI

[VIEW CATALOG](#)

AJNR

Regional correlation of PET and CT in senile dementia of the Alzheimer type.

M J de Leon, A E George, S H Ferris, S Rosenbloom, D R Christman, C I Gentes, B Reisberg, I I Kricheff and A P Wolf

AJNR Am J Neuroradiol 1983, 4 (3) 553-556

<http://www.ajnr.org/content/4/3/553>

This information is current as of May 29, 2025.

Regional Correlation of PET and CT in Senile Dementia of the Alzheimer Type

Mony J. de Leon,¹ Ajax E. George,² Steven H. Ferris,¹ Shelley Rosenbloom,² David R. Christman,³ Cynthia I. Gentes,¹ Barry Reisberg,¹ Irvin I. Kricheff,² and Alfred P. Wolf³

Alzheimer disease is manifested by both widespread and regionally restricted brain changes, some of which have recently been identified in vivo with computed tomography (CT) and positron emission tomography (PET). This is a report of the regional correlation of CT and PET measurements in 19 carefully diagnosed subjects comprising 11 controls and eight patients with senile dementia of the Alzheimer type. Regional CT attenuation values did not discriminate between the two groups, but PET using ¹⁸F-2-deoxy-2-fluoro-D-glucose demonstrated significant regional reductions (range, 21%–28%) in glucose utilization in the Alzheimer group. PET measures were also more consistently related to cognitive decline. The correlation between CT structural measures and PET metabolic measures demonstrated consistent relations between widespread PET regions and CT changes in the thalamus, posterior limb of the internal capsule, and temporal lobes. However, CT changes in the frontal white matter, caudate nucleus, and anterior limb of the internal capsule were not related to any regional PET changes. These data support previous findings of temporal lobe involvement in Alzheimer disease and suggest the involvement of structures in the region of the third ventricle.

Histopathologic studies have revealed that senile plaques, neurofibrillary tangles, and granulovacuolar degeneration are more likely to be found in the brains of patients with senile dementia of the Alzheimer type (SDAT) than in age-matched cognitively normal controls [1–3]. Recent studies have also provided preliminary evidence for selective regional neuronal losses in SDAT. Terry et al. [4] and Mountjoy et al. [5] found reductions in the larger-sized neurons, especially in the frontal and temporal cortex. Whitehouse et al. [6] reported significant neuronal loss in the nucleus basalis of Meynert. Other recent experimental evidence has indicated that lesions in this group of basal forebrain cells produce substantial and widespread reductions in cortical levels of choline acetyltransferase. Thus, a subcortical lesion may account for some of the cholinergic and intellectual dysfunctions characteristic of SDAT [7].

Gross pathologic evaluations of SDAT patients have demonstrated frontal and temporal shrinkage of the cerebral convolutions with widening of the cortical sulci and ventricular dilatation [8]. However, these atrophic changes are not specifically diagnostic for SDAT. Computed tomography (CT) has revealed ventricular and sulcal enlargements associated with increasing cognitive impair-

ment [9, 10]. A review of CT studies of SDAT [11] concluded that ventricular changes are more prominent than sulcal changes. In addition, there has been some recent CT evidence for regionally specific brain changes in SDAT. In a study of different CT scan evaluation strategies [9], the width of the third ventricle was found to be the best linear ventricular correlate of degree of cognitive impairment and also the best correlate of total ventricular volume [12].

Improved gray-matter/white-matter discrimination is possible with modern CT equipment. Recent studies have shown that attenuation changes in white matter are associated with cognitive impairment in presenile Alzheimer disease [13] and SDAT [14, 15]. In a study of regional CT attenuation changes in 35 SDAT patients [10] we found that decreasing thalamic attenuation values were the most consistent correlates of cognitive decline. We also reported [15] that the subjective ability to discriminate between gray matter and white matter in patients decreased with increasing impairment. The best ventricular predictor of this parenchymal change was the width of the third ventricle.

Positron emission tomography (PET) permits for the first time in vivo regional biochemical evaluation of the human brain. Recent PET studies using several metabolic tracers have demonstrated decreases in brain metabolism in SDAT relative to controls [16–18] and have also shown correlations between metabolic diminution and cognitive impairment.

Thus, in SDAT, correlations between altered structure and behavior have been shown by CT and correlations between altered metabolic function and behavior have been shown by PET. We report the first combined use of CT and PET (glucose metabolism) in the regional analysis of structure-function relations in the brain.

Subjects and Methods

Nineteen subjects between 60 and 85 years of age received medical, neurologic, psychiatric, and neuroradiologic examination. Of these, eight were clinically diagnosed as having SDAT (mean age, 72.6 ± 2.5); the other 11 were diagnosed as normal and served as control subjects (mean age, 67.9 ± 2.3). The age difference between two groups was not statistically significant.

CT studies were conducted at NYU Medical Center using a GE CT/T 8800 scanner. The CT images were obtained with standard

This work was supported in part by grants MH36969 and NS15638.

¹Department of Psychiatry, New York University Medical Center, 550 First Ave., New York, NY 10016. Address reprint requests to M. J. de Leon.

²Department of Radiology (Neuroradiology), New York University Medical Center, New York, NY 10016.

³Department of Chemistry, Brookhaven National Laboratory, Upton, NY 11973.

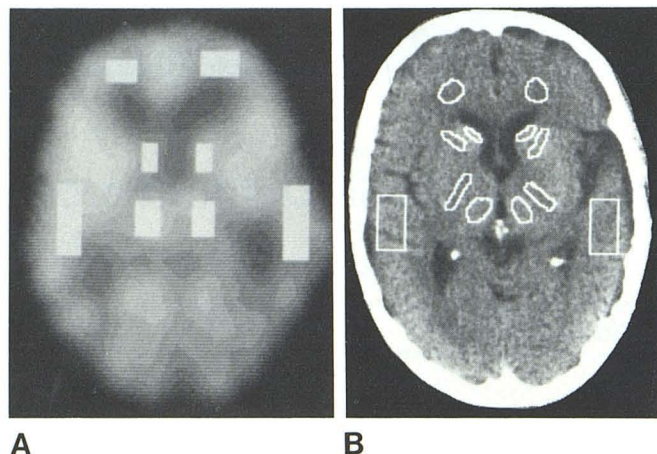


Fig. 1.—A, Representative PET scan depicts regions of brain sampled for metabolic study. B, Representative CT scan depicts regions of brain evaluated in structural attenuation study.

TABLE 1: Regional Differences in PET and CT Brain Measures between SDAT Patients and Controls

Brain Region Sampled	Difference (%)	
	PET: Glucose Metabolism	CT: Structural Attenuation
Frontal lobe:		
R	-24*	-2
L	-24*	-3
Caudate nucleus:		
R	-23*	+2
L	-27*	-2
Thalamus:		
R	-25*	-2
L	-28*	-2
Temporal lobe:		
R	-21*	-6
L	-22*	-7
Internal capsule:†		
Anterior limb:		
R	+5
L	+2
Posterior limb:		
R	-2
L	-2
Whole slice‡	-25*	...

Note.—The study group comprised eight patients with senile dementia of the Alzheimer type (SDAT) and 11 normal controls. R = right; L = left.

* $p \leq 0.05$.

† CT only.

‡ PET only.

kilovoltage and milliamperage settings and a scan time of 9.6 sec. The spatial resolution was 1 mm × 1 mm × 10 mm. No contrast agents were used.

PET studies using ^{18}F -2-deoxy-2-fluoro-D-glucose (FDG) and a PETT III scanner were conducted at the Brookhaven National Laboratory. The intrinsic spatial resolution of the PETT III is 1.7 cm × 1.7 cm × 1.7 cm, full-width-half-maximum. Each patient received an intravenous bolus of 5–10 mCi (185–370 MBq) FDG in the arm contralateral to the one from which arterial or arterialized venous blood was sampled. Scanning began after a 30 min tracer uptake period during which the subjects rested quietly in the dimly lit scan room. With PET III and FDG, each scan takes 9–12 min. At least five scans were obtained for each patient.

TABLE 2: Pearson Correlations of Regional PET and CT Brain Measures with Mental Status and Age

Brain Region Sampled	PET: Glucose Metabolism		CT: Structural Attenuation	
	MSQ	Age	MSQ	Age
Frontal lobe:				
R	-0.56*	-0.17	-0.29	-0.28
L	-0.58*	-0.27	-0.45*	-0.29
Caudate nucleus:				
R	-0.57*	-0.34	-0.11	-0.07
L	-0.51	-0.33	-0.31	-0.27
Thalamus:				
R	-0.56*	-0.22	-0.49*	-0.30
L	-0.57*	-0.32	-0.34	-0.30
Temporal lobe:				
R	-0.40*	-0.12	-0.48*	-0.43*
L	-0.49*	-0.12	-0.51*	-0.36
Internal capsule:†				
Anterior limb:				
R	0.04	0.14
L	-0.16	0.10
Posterior limb:				
R	-0.43*	-0.44*
L	-0.27	-0.16
Whole slice‡	-0.58*	-0.21

Note.—The 19 member study group comprised eight patients with Alzheimer disease and 11 normal controls. MSQ = Mental Status Questionnaire; R = right; L = left.

* $p \leq 0.05$.

† CT only.

‡ PET only.

Patients were positioned in both the CT and PET scanners using the same model head holder and three identically aligned laser lights. Photographs were taken of the laser-lighted patient in the CT scanner to replicate the same head positioning in the PET scanner. All scans were taken parallel to the canthomeatal line at 10 mm intervals.

PET and CT scans from the basal ganglia level of the brain were matched using information from the recorded table positions and from the subjective alignment of slice features. In computing rates of glucose utilization, regions of interest on the PET scans were identified by their locations relative to the center of the image on the corresponding CT scans. The regions sampled for the PET study were as follows: frontal white matter, head of caudate nucleus (probably including some anterior limb of the internal capsule), thalamus (possibly including some posterior limb of the internal capsule), and temporal lobe (posterior to the sylvian fissure and lateral to the atrium of the lateral ventricles) (fig. 1A). The PET measures also include the average whole slice metabolic rate. Because of the relative resolution differences of CT and PET, the regions sampled for the attenuation analysis were smaller and anatomically more homogeneous than the PET regions. The CT regions, in addition to those encompassed by the PET scan, included the anterior and posterior limbs of the internal capsule (fig. 1B).

Results

All mean regional glucose utilization values were significantly lower in the SDAT patients than in controls. The regional difference between the two groups ranged from 21% to 28%. These regional changes are comparable to those found in our larger PET study ($n = 44$; de Leon et al., also reported in this issue), indicating that this sample of patients and controls is representative of our larger series. However, regional CT attenuation data reflected no differences between SDAT patients and normal controls (table 1).

TABLE 3: Pearson Correlations between Regional PET and CT Brain Measures

Region of Brain Studied by PET for Metabolic Change	Region of Brain Studied by CT for Structural Change												Significance (%)
	Frontal Lobe		Caudate Nucleus		Thalamus		Temporal Lobe		Ant. Internal Capsule		Post. Internal Capsule		
	R	L	R	L	R	L	R	L	R	L	R	L	
Frontal lobe:													
R	0.21	0.31	0.24	0.29	0.45*	0.55*	0.73*	0.67*	0.17	0.20	0.49*	0.55*	50
L	0.16	0.25	0.17	0.23	0.41*	0.49*	0.69*	0.65*	0.12	0.13	0.49*	0.51*	50
Caudate nucleus:													
R	0.19	0.27	0.31	0.29	0.39*	0.54*	0.64*	0.58*	0.21	0.27	0.53*	0.57*	50
L	0.11	0.17	0.18	0.24	0.32	0.45*	0.64*	0.56*	0.14	0.22	0.51*	0.51*	42
Thalamus:													
R	0.18	0.20	0.22	0.21	0.43*	0.52*	0.53*	0.50*	0.12	0.17	0.46*	0.48*	50
L	0.07	0.11	0.12	0.13	0.31	0.44*	0.51*	0.45*	0.05	0.15	0.39	0.46*	33
Temporal lobe:													
R	0.15	0.21	0.18	0.20	0.44*	0.48*	0.58*	0.51*	0.11	0.14	0.41	0.57*	42
L	0.04	0.13	0.08	0.06	0.35	0.39	0.46*	0.45*	0.04	0.05	0.37	0.49*	25
Whole slice	0.19	0.23	0.20	0.23	0.46*	0.52*	0.58*	0.48*	0.08	0.15	0.46*	0.51*	50
Significance (%)	0	0	0	0	67	89	100	100	0	0	67	100	

Note.—The 19 member study group comprised eight patients with Alzheimer disease and 11 normal controls. R = right; L = left.

* $p \leq 0.05$.

The correlations of CT and PET measurements with the Mental Status Questionnaire [19] are found in table 2. For CT the most consistent correlation between structural attenuation and mental status was in the region of the temporal lobes. For PET, highly significant correlations were found between each of the regional glucose utilization measures and the mental status measure. The correlation with age was negligible for the regional PET measures but somewhat more significant for some CT regions.

The correlations between CT and PET regions of interest are found in table 3. The varying numbers (percentages) of PET metabolic measures that are correlated with the respective CT structural attenuation values reflect regional differences in the structure-function relation. CT structural changes in the thalami, temporal lobes, and posterior limbs of the internal capsule were consistently related to widespread regional PET metabolic changes. Structural attenuation changes in the frontal white matter, the head of the caudate nucleus, and the anterior limbs of the internal capsule were not associated with metabolic changes. The most consistent regional correlations between CT structural attenuation changes and PET metabolic changes were found in the temporal lobes. No single PET region was consistently associated with widespread CT structural change.

Discussion

Postmortem neuropathologic studies have demonstrated widespread structural and neurochemical changes associated with Alzheimer disease. While there is pathologic evidence for regional brain changes in SDAT, many of these findings are preliminary and some are contradictory. Moreover, pathologic studies of SDAT have not specifically examined the regions adjacent to the third ventricle.

Our recent CT and PET studies [9, 14–16] suggested independently the possible clinical importance of structural and metabolic changes in areas adjacent to the third ventricle (i.e., the thalamus). The present study confirms those observations. These data also show a correlation between thalamic CT attenuation and widespread reduction in brain metabolic activity. Furthermore, structural changes in the posterior limbs of the internal capsule and in the temporal lobes are consistently associated with reduced metabolic activity in the cortical and subcortical regions.

The structure-function relations described here are merely correlational and do not necessarily imply that structural changes

cause the decreased metabolic activity in SDAT. However, Carpenter [20] has observed that the thalamus is the key to understanding the functional organization of the central nervous system. Thalamic functions include regulation of cortical electrical activity, the distribution of afferent input to the cortex, and integration of motor functions via relays between the basal ganglia/motor cortex and cerebellum. It is intriguing but speculative at this point to suggest that the anatomic and metabolic changes reported here reflect impairment of some of these functions or related pathways. Our results do, however, suggest the general involvement of structures in the region of the third ventricle and indicate the need for further in vivo and pathologic study.

REFERENCES

1. Blessed WF, Tomlinson BE, Roth M. The association between quantitative measures of dementia and of senile change in the cerebral grey matter of elderly subjects. *Br J Psychiatry* 1968;114:797–811
2. Farmer PM, Peck A, Terry RD. Correlations among numbers of neuritic plaques, neurofibrillary tangles, and the severity of senile dementia. Presented at the annual meeting of the American Association of Neuropathology, San Francisco, June 1976
3. Tomlinson BE, Kitchner D. Granulovacuolar degeneration of hippocampal pyramidal cells. *J Pathol* 1972;106:165–185
4. Terry RD, Peck A, DeTeresa R, Schechter R, Horoupina DS. Some morphometric aspects of the brain in senile dementia of the Alzheimer type. *Ann Neurol* 1981;10:184–192
5. Mountjoy CQ, Roth M, Evans NJR, Evans HM. Neuronal loss in senile dementia of the Alzheimer's type. Presented at the Aharon Katzir-Katchalsky Conference on the Aging of the Brain, Mantua, Italy, March 1982
6. Whitehouse PJ, Price DL, Struble RG, Clark AW, Coyle JT, De Long MR. Alzheimer's disease and senile dementia: loss of neurons in the basal forebrain. *Science* 1982;215:1237–1239
7. Johnston MV, Young AC, Coyle JT. Laminar distribution of cholinergic markers in neocortex: effects of lesions. *J Neurosci Res* 1981;6:597–607
8. Tomlinson BE, Blessed G, Roth M. Observations of brains of demented old people. *J Neurol Sci* 1970;11:205–242
9. de Leon MJ, Ferris SH, George AE, Reisberg B, Kricheff II, Gershon S. Computed tomography evaluations of brain-behav-

- ior relationships in senile dementia of the Alzheimer's type. *Neurobiol Aging* **1980**;1:69-79
10. Jacoby RJ, Levy R. Computed tomography in the elderly. 2. Senile dementia: diagnosis and functional impairment. *Br J Psychiatry* **1980**;136:256-269
 11. de Leon MJ, George AE. Computed tomography in aging and senile dementia of the Alzheimer's type. In: Mayeux R, Rosen W, eds. *The dementias. Advances in neurology*. New York: Raven (in press)
 12. George AE, de Leon MJ, Rosenbloom S, et al. CT ventricular volume and its relationship to cognitive impairment in dementia. Presented at the annual meeting of the American Aging Association, New York, September **1981**
 13. Naeser MA, Gebhardt CT, Levine HL. Decreased computerized tomography numbers in patients with presenile dementia. *Arch Neurol* **1980**;37:401-409
 14. de Leon MJ, George AE, Ferris SH, Rosenbloom S, Gentes CI, Reisberg B. Grey matter and white matter CT correlates in senile dementia of the Alzheimer's type. Presented at the Aharon Katzir-Katchalsky Conference on the Aging of the Brain, Mantua, Italy, March **1982**
 15. George AE, de Leon MJ, Ferris SH, Kricheff II. Parenchymal CT correlates of senile dementia (Alzheimer's disease): loss of gray-white matter discriminability. *AJNR* **1981**;2:205-211
 16. Ferris SH, de Leon MJ, Wolf AP, et al. Positron emission tomography in the study of aging and senile dementia. *Neurobiol Aging* **1980**;1:127-131
 17. Bustany P, Sargent T, Saudubray JM, Henry JF, Comar D. Regional human brain uptake and protein incorporation of ^{11}C -L-methionine studied *in vivo* with PET. *J Cerebral Blood Flow Metabolism* **1981**;1:517-518
 18. Frackowiak RSJ, Pozzilli C, Legg NJ, et al. Regional cerebral oxygen supply and utilization in dementia—a clinical and physiological study with oxygen-15 and positron tomography. *Brain* **1981**;104:753-778
 19. Kann RL, Goldfarb AI, Pollack M, Peck A. Brief objective measures for the determination of mental status in the aged. *Am J Psychiatry* **1960**;117:326-328.
 20. Carpenter MB. *Human neuroanatomy*, 7th ed. Baltimore: Williams & Wilkins, **1976**