



Discover Generics

Cost-Effective CT & MRI Contrast Agents



FRESENIUS
KABI

WATCH VIDEO

AJNR

Computed tomography of olivopontocerebellar degeneration.

M Savoiardo, M Bracchi, A Passerini, A Visciani, S Di Donato and F Cocchini

AJNR Am J Neuroradiol 1983, 4 (3) 509-512

<http://www.ajnr.org/content/4/3/509>

This information is current as
of June 26, 2025.

Computed Tomography of Olivopontocerebellar Degeneration

Mario Savoiardo,¹ Maurizio Bracchi,¹ Angelo Passerini,¹ Anna Visciani,¹ Stefano Di Donato,² and Franco Cocchini³

Computed tomographic (CT) studies of 17 cases of olivopontocerebellar degeneration are reported. In all cases, atrophy of brainstem and cerebellum was found. Atrophy of the cerebellar hemispheres was equal to, or more marked than, atrophy of the vermis. Dilatation of lateral ventricles and cerebral sulci was often present. These findings, which are in agreement with the pathologic data, are compared with those reported in other cerebellar atrophic processes. Knowledge of the distribution of the atrophic changes is essential in attempting a differential diagnosis among the degenerative diseases involving the posterior fossa nervous structures.

In 1900 Déjerine and André-Thomas [1] described a disease manifested clinically by disturbances of cerebellar functions and characterized at pathologic examination by atrophy of cerebellar cortex, inferior olives, gray matter of the pons, and degeneration of the middle cerebellar peduncles. A similar picture, including spinal cord changes, with autosomal dominant transmission, had been reported by Menzel in 1891 (cited in [2]).

Since 1900, many similar cases, both familial and isolated, have been reported. In the vast group of degenerative diseases affecting the cerebellum, olivopontocerebellar degeneration (OPCD) is now a well defined entity, clearly distinct from cerebellar cortical atrophy, first described by Holmes, in which pontine nuclei are spared, and from Friedreich ataxia, in which the most conspicuous lesions are in the spinal cord. However, several isolated cases or families have been reported that fall between these three entities [3]. In addition, conditions of known etiology in which cerebellar degeneration is found, such as carcinomatous cerebellar degeneration and alcoholic and phenytoin cerebellar degenerations have to be mentioned.

We report a series of 17 patients observed at the Istituto Neurologico of Milan over a period of 8 years, in whom diagnosis of OPCD was made. The clinical diagnosis was sharply supported by clearly depicted brain abnormalities seen on computed tomography (CT).

Materials and Methods

The clinical and radiologic records of 17 cases with current diagnosis of OPCD were reviewed. The patients were observed at our institute over an 8 year period and had a follow-up of 1–4 years (average, 2 years). Twelve were familial cases and five were sporadic. There were nine males and eight females. The average age was 40 years (range, 9–61) with a mean duration of disease of 9 years.

Ataxia was usually the presenting symptom, but all the patients had limb incoordination and dysarthria at the time of CT. Difficulty in swallowing was present in 14 cases and conjugate ocular movements were impaired in 12. Mental deterioration was present in 12 patients; in four, extrapyramidal signs were also found.

Brainstem auditory-evoked responses (BAER), studied in 10 patients, were found abnormal in nine, suggesting a lesion of brainstem central auditory pathways.

All the patients had one or more CT studies, usually performed with an EMI 1010 machine and 10 mm cuts, rarely with 5 mm cuts and 320 × 320 matrix. In three patients, pneumoencephalography performed 6, 5, and 3 years before CT, respectively, was available for comparison.

Initial attempts to quantify the degree of atrophy observed on CT by measuring the width of sulci and cisterns appeared unreliable. Therefore, atrophy was rated subjectively and separately as minimal, marked or extremely severe by three different neuroradiologists. The rating was usually identical. When different, the case was classified by consensus. Attention was focused on all the cisterns surrounding the brainstem, on vermian and hemispheric cerebellar sulci, and, in the supratentorial compartment, on the ventricles and sulci of the cerebral hemispheres.

Results

CT studies were abnormal in all cases, demonstrating atrophy of different degrees of both brainstem and cerebellum. Atrophic changes were *minimal* in only one familial case, having the shortest duration of the disease (case 3, sister of case 4), while they were *marked* in 13 and *extremely severe* in three (cases 1, 9, and 15) (fig. 1, table 1). The degree of atrophy of the cerebellum and brainstem in an individual case was always similar (fig. 2). While recognition of dilatation of superior cerebellar sulci was always easy, assessment of changes of the cisterns surrounding the inferior part of the brainstem was sometimes uncertain because of bony artifacts. Dilatation of cerebellar sulci was equal or more marked on the hemispheres compared with the superior vermis (fig. 2). Dilatation of the fourth ventricle was frequently present, but usually less striking. Lateral ventricles were dilated in six cases and evidence of cerebral cortical atrophy was found in 13 cases. There was a fairly good correlation between clinical impairment and atrophy in the posterior fossa. Furthermore, of 13 patients with evidence of cerebral atrophy, 12 had some degree of mental deterioration.

¹ Department of Neuroradiology, Istituto Neurologico, Via Celoria 11, 20133 Milan, Italy. Address reprint requests to M. Savoiardo.

² Laboratory of Neurometabolic Diseases, Istituto Neurologico, 20133 Milan, Italy.

³ ENT Service, Istituto Neurologico, 20133 Milan, Italy.

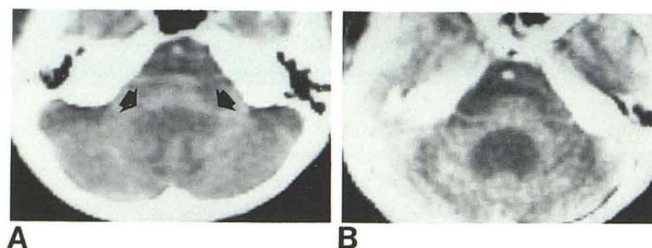


Fig. 1.—Case 1. Extremely severe atrophy of brainstem and cerebellar hemispheres with enlargement of fourth ventricle. A, Inferior cerebellar peduncles are thinned (arrows). B, Pons is wedge-shaped and middle cerebellar peduncles are thinned.

The pneumoencephalograms in three patients all showed atrophy of the brainstem and vermis, but hemispheric atrophy was recognizable in only one case (case 12).

Discussion

Definitive proof of diagnosis of OPCD can be obtained only by postmortem histologic examination, until an *in vivo* biologic marker can be found. However, in the attempt to obtain a strong confirmation of clinical diagnosis *in vivo*, the first step was made by Le May and Abramowicz [4], who in 1965 described pneumoencephalographic changes in various forms of cerebellar degenerative diseases. Recently, CT has added new possibilities with a noninvasive method. Several reports [5–8] have dealt with the diagnosis of cerebellar atrophic processes by CT, but, in these series, the number of cases of OPCD was usually small.

Our series demonstrated a relatively uniform pattern of the atrophic changes, which correlates well with the distribution of the atrophic and degenerative processes demonstrated previously in

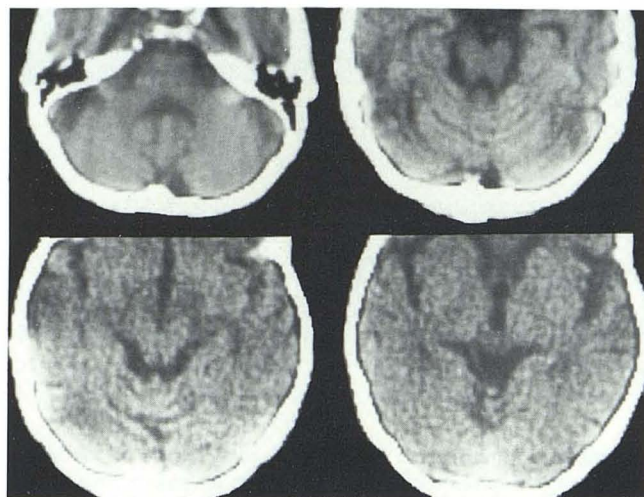


Fig. 2.—Case 6. Marked dilatation of peripontine and lateral cerebellar cisterns. Atrophy of cerebellar hemispheres is more marked than of vermis. Pneumoencephalogram 6 years before showed mild dilatation of vermian sulci, but no air over hemispheres.

OPCD cases at pathologic examination. In fact, in this disease, atrophy in the brainstem involves mostly the ventral part of the pons with degeneration of transverse fibers and of middle cerebellar peduncles. Preservation of tegmentum and pyramidal tracts results in a wedge shape of the central part of the pons and in a quadrangular shape of its superior segment (figs. 1 and 3). Less severe changes are observed at the level of the medulla oblongata, where shrinkage and loss of neurons occur in the inferior olives with loss of olivocerebellar fibers (fig. 1A). In the cerebellum, the vermis and the flocculus tend to be spared compared with the cortex of the

TABLE 1: CT Findings in Olivopontocerebellar Degeneration

Origin: Case No. (age, gender)	Duration (years)	Degree of Atrophy on CT*					
		Brainstem	Fourth Ventricle	Cerebellum		Cerebrum	
				Vermis	Hemispheres	Ventricles	Cortex
Familial:							
1 (15, F)	10	+++	+++	+++	+++	+++	+++
2 (22, M)	15	++	++	+	++	+	++
3 (39, F)	1	+	—	±	—	—	+
4 (42, M)	5	++	+	++	++	—	++
5 (9, F)	2	++	++	++	++	+++	+++
6 (41, M)	14	++	+	+	++	+	++
7 (24, F)	4	++	—	++	++	—	+
8 (54, F)	14	+	—	++	++	—	—
9 (46, M)	8	+++	+	++	++	—	++
10 (48, M)	7	++	—	+	++	—	—
11 (29, F)	4	++	—	+	+	—	—
12 (56, M)	16	+	—	++	++	—	+
Sporadic:							
13 (33, F)	7	++	++	++	++	—	—
14 (47, M)	5	++	++	++	++	—	+
15 (66, F)	5	+++	++	++	++	++	+
16 (60, M)	20	+	—	+	++	+	+
17 (39, M)	11	+	++	++	++	—	+

Note.—Pneumoencephalography was performed in cases 2, 6, and 12.

* — = normal; + = minimal atrophy; ++ = marked atrophy; +++ = extremely severe atrophy.

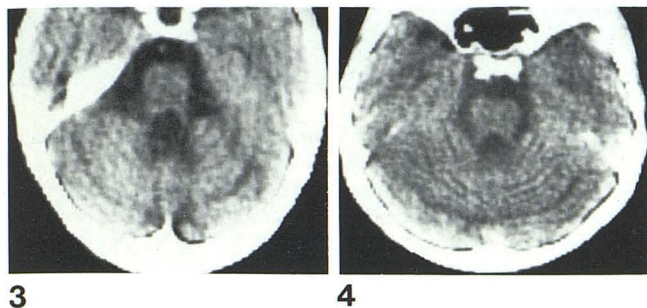


Fig. 3.—Case 15. Section through superior pons demonstrates quadrangular shape.

Fig. 4.—Case 14. Dilatation of posterior superior fissure and of hemispheric sulci.

cerebellar hemispheres (fig. 4) [3]. In the cerebrum, cell loss is found in the basal ganglia and in the cortex, as manifested clinically by extrapyramidal signs and mental deterioration.

Knowledge of this distribution of the atrophic changes is essential in attempting a differential diagnosis by CT from other degenerative diseases involving the cerebellum.

Studies of CT in cerebellar atrophic processes have not attempted a differential diagnosis within the heterogeneous group of primary degenerative diseases [7, 8]; however, involvement of the brainstem in OPCD is recognized [7], and frequent normal findings in the posterior fossa in Friedreich ataxia cases have been reported [6, 7] and were observed by us in our cases. Sparing of the brainstem and prevalence of vermian versus hemispheric atrophy should differentiate Holmes cerebellar cortical atrophy from OPCD, as already pointed out on pneumoencephalographic studies by LeMay and Abramowicz [4, 9] and others [2]. On the contrary, severe atrophy of the pons with normal cerebellum is consistent with the rare form of spinopontine degeneration described by Boller and Segarra [10].

Several reports deal with other atrophic processes involving the cerebellum. Chronic alcoholism is consistently found to involve particularly the superior vermis [5, 7], although more than half the patients with alcoholism in the series of Koller et al. [8] also had atrophy of the cerebellar hemispheres and a significantly increased incidence of cerebral atrophy. CT evidence of cerebellar atrophy in chronic alcoholics without clinical signs or symptoms is also reported [11]. Carcinomatous cerebellar degeneration should diffusely involve the cerebellum, but, in the five cases observed by Koller et al. [8], CT showed atrophy only of the vermis and not of the cerebellar hemispheres. Chronic phenytoin usage in epileptic patients causes more diffuse cerebellar atrophic changes [7, 8], which may be attributable both to the toxic effect of the drug and to the result of repeated anoxia due to epileptic seizures. As in alcoholism, atrophic changes may appear on CT even in the absence of clinical symptoms; however, in both conditions, alcoholism and chronic phenytoin usage, the etiologic factor is known and, therefore, occurrence of atrophy in these patients does not raise a diagnostic problem.

Three of our patients with OPCD had pneumoencephalography some years before CT. It had beautifully demonstrated atrophy of the brainstem, particularly of the pons and of the vermis, fairly marked in two cases and minimal in one. Demonstration of cerebellar hemispheric atrophy was obtained in only one case. However, in the other two cases (cases 2 and 6), CT demonstrated more evident enlargement of hemispheric sulci than of those of the vermis, and presumably the hemispheres were atrophic also at time

TABLE 2: Expected CT Distribution of Atrophy in Atrophic Processes Involving Posterior Fossa Structures

	Brainstem	Fourth Ventricle	Cerebellum	
			Vermis	Hemispheres
Olivopontocerebellar degeneration (Déjerine-Thomas and Menzel types)	++	+	++	++
Cerebellar cortical atrophy (Holmes type)	—	±	++	+
Friedreich ataxia	—	—	±	±
Chronic alcoholism	—	—	++	±
Phenytoin intoxication	—	—	+	+
Carcinomatous cerebellar degeneration	—	—	+	±

Note.— = normal; + = mild atrophy; ++ = moderate or severe atrophy.

of previous pneumoencephalography. Lack of demonstration of hemispheric atrophy by pneumoencephalography may be explained by the shape of the superior cerebellum and tentorium, which are more elevated on the midline; therefore, the air collects on the midline, and, if large amounts of air are not employed, cerebellar hemispheric atrophy may remain undetected. There may be another reason why hemispheric atrophy was overlooked in pneumoencephalographic studies: in the routine pneumoencephalogram, tomograms in the lateral view were usually obtained only on the midline with consequent perfect delineation of the profile of the brainstem and of the vermis, while less attention was given to defining the hemispheric sulci [12]. The expected distribution of atrophies in posterior fossa, from radiologic and pathologic reported data of the most common degenerative and toxic diseases, is summarized in table 2.

In conclusion, although bony artifacts or lack of fine details may impair CT versus pneumoencephalography in the definition of atrophic changes of the brainstem and of the cerebellum, CT is superior to pneumoencephalography in demonstrating atrophy of cerebellar hemispheres, and it is now obviously the method of choice for studying atrophic processes involving the nervous structures of the posterior fossa.

With finer details of thin slices and reformatted images of late-generation, high-resolution CT scanners, it will be possible to define atrophy of the brainstem not on the basis of enlargement of the surrounding cisterns, but on the basis of millimetric measurements of the real size of the brainstem itself. It is also possible that the combination of BAER studies and CT [13] will prove helpful in differentiating the various atrophic processes involving the posterior fossa structures.

In suspected cases of OPCD, the distribution of the atrophies with selective involvement of the pons, of middle cerebellar peduncles, of the cerebellar hemispheres and vermis, in addition to the more widespread atrophic changes that may affect the other segments of the brainstem and the cerebral hemispheres, provide a strong support to the clinical diagnosis and may be essential in discriminating this disease from Holmes cerebellar atrophy, rendering the diagnosis of OPCD almost certain *in vivo*.

REFERENCES

1. Déjerine J, André-Thomas M. L'atrophie olivo-ponto-cérébelleuse. *Nouv Iconogr Salpêtr* 1900;13:330-370
2. Eadie MJ. Olivo-ponto-cerebellar atrophy (Déjerine-Thomas type, Menzel type). In: Vinken PJ, Bruyn GW, eds. *Handbook*

- of clinical neurology, vol 21. New York: American Elsevier, 1975:415-431, 433-449
3. Oppenheimer DR. Diseases of the basal ganglia, cerebellum and motor neurons. In: Blackwood W, Corsellis JAN, eds. *Greenfield's neuropathology*. London: Arnold, 1976:622-632
 4. LeMay M, Abramowicz A. The pneumoencephalographic findings in various forms of cerebellar degeneration. *Radiology* 1965;85:284-290
 5. Rothman SLG, Glanz S. Cerebellar atrophy; the differential diagnosis by computerized tomography. *Neuroradiology* 1978;16:123-126
 6. Pedersen L, Gyldensted C. Computerized tomography in hereditary ataxias. *Acta Neurol Scand* 1978;58:81-88
 7. Allen JH, Martin JT, McLain LW. Computed tomography in cerebellar atrophic processes. *Radiology* 1979;130:379-382
 8. Koller WC, Glatt SL, Perlik S, Huckman MS, Fox JH. Cerebellar atrophy demonstrated by computed tomography. *Neurology* (NY) 1981;31:405-412
 9. LeMay M, Abramowicz A. Encephalography in the diagnosis of cerebellar atrophy. *Acta Radiol [Diagn]* (Stockh) 1966;5:667-674
 10. Boller F, Segarra JM. Spino-pontine degeneration. In: Vinken PJ, Bruyn GW, eds. *Handbook of clinical neurology*, vol 21. New York: American Elsevier, 1975:389-402
 11. Haubek A, Lee K. Computed tomography in alcoholic cerebellar atrophy. *Neuroradiology* 1979;18:77-79
 12. Kennedy P, Swash M, Wylie IG. The clinical significance of pneumographic cerebellar atrophy. *Br J Radiol* 1976;49:903-911
 13. Gilroy J, Lynn GE. Computerized tomography and auditory-evoked potentials. *Arch Neurol* 1978;35:143-147