



Discover Generics

Cost-Effective CT & MRI Contrast Agents

 FRESENIUS
KABI

[WATCH VIDEO](#)

AJNR

Morphologic cerebral changes in patients undergoing dialysis for renal failure.

K Kretschmar, W Nix, H Zschiedrich and T Philipp

AJNR Am J Neuroradiol 1983, 4 (3) 439-441

<http://www.ajnr.org/content/4/3/439>

This information is current as
of June 17, 2025.

Morphologic Cerebral Changes in Patients Undergoing Dialysis for Renal Failure

K. Kretzschmar,¹ W. Nix,² H. Zschiedrich,³ and T. Philipp³

Cranial computed tomographic examinations were performed on 22 patients before and after hemodialysis, and on 11 of those patients 8 months later. In 11 cases widening of the cerebrospinal fluid spaces due to brain atrophy was recognizable. Density measurements disclosed decreased absorption of cerebral parenchyma after dialysis in 73% of the cases. This finding is partly explained by cerebral edema or hydration, although the necessary contemporaneous narrowing of cerebrospinal fluid spaces existed in only six patients (27%). Long-term follow-up studies have not displayed any realizable changes in results. Finally, despite striking computed tomographic findings and alterations after dialysis, only mild neurologic symptoms or disequilibrium syndromes have been registered.

A combination of severe neurological deficits and mild disorders may be observed in patients with acute or chronic renal failure subsequently treated by dialysis. These symptoms are characterized as disequilibrium syndrome [1]. In 90% of cases, the discomforts (usually headache, weariness, nausea, and vomiting) a patient may experience can be considered mild; however, some patients have side effects that can be considered moderately severe, such as tremor, disorientation, and somnolence. In rare cases, serious disorders occur, such as psychosis, muscle cramps, and coma [2]. Psychodiagnostic procedures and electroencephalographic changes can also disclose functional or capacity cerebral changes in dialyzed patients [3].

In comparative computed tomographic (CT) studies of patients with end-stage chronic renal failure or under chronic hemodialysis, ventricular enlargement can usually be found, appropriate to a brain atrophy [4]. Dettori et al. [5] confirm a diminution of the density of parenchyma without showing any changes of cerebrospinal fluid (CSF) spaces on CT.

The purpose of our study was to elucidate, by means of CT, pathomorphologic alterations of the cerebral parenchyma and the CSF spaces due to neurologic syndromes possibly occurring during and after dialysis.

Subjects and Methods

The study dealt with 22 patients (10 men, 12 women) aged 21–73 years (average, 49 years) with end-stage renal failure. Three times a week, all patients underwent 4–5 hr of hemodialysis. The duration of these treatments ranged from 6 months to 10 years. Only in rare cases was there slight discomfort after hemodialysis, such as headache, nausea, vomiting, and muscle cramps.

Predialytic chest films were obtained to determine the patient's state of hydration; however, they were not obtained in all cases at the same time as the CT examination. Cranial CT (using a CT 1010 EMI scanner, 10 mm slices) was performed just before and immediately after hemodialysis. In 11 patients, the initial findings were checked by CT 6–9 months later (average, 8 months).

All investigations were analyzed as to density of parenchyma and width of CSF spaces. The determination of the absorption values of cerebral parenchyma was based on the densitometry of a rectangular region of interest (ROI) in the white and gray matter of both the frontal and parietal lobes. Both sides were measured twice; the mean values were registered. Additional densitometric measurements of the basal ganglia using circular regions of interest were also obtained. In order to determine the CSF spaces we analyzed the width of the third ventricle, the sylvian fissure, and the fronto-basal interhemispheric fissure according to the work of Meese and Grumme [6]. These spaces are considered to be normal up to a width of 5 mm. The cella media index according to Schiersmann relates the width of lateral ventricles in the cella media region to the biparietal diameter of the inner table of the skull. This index is abnormal if it is less than 4. The statement of a pathologic widening of CSF spaces was made if the normal range was exceeded by at least three criteria. All of these data are reported in table 1.

Results

A decrease in body weight due to water ultrafiltration of 1.2–5.2 kg (average 3.0 kg) was observed in our patients. There were 16 patients (73%) examined by CT after hemodialysis who displayed a decrease in density of cerebral parenchyma. These changes were evident in the frontal and parietal regions as well as in the basal ganglia. The white matter exhibited a decrease in radioabsorption by 2 Hounsfield units (H); the cortex of both the frontal and parietal lobes decreased by 3 H on average. The decrease in density of parenchyma appeared in every decade of age without relation to the duration of hemodialytic treatment or body weight of the patients. The other six cases revealed no changes of the absorption values. Follow-up studies 8 months after the initial examinations disclosed no further alterations in brain density.

In 11 cases (50%), widening of the ventricular system and subarachnoid spaces was evident before dialysis treatment. After dialysis, seven patients demonstrated an unchanged dilatation of the CSF spaces. In four patients a narrowing of both the ventricular system and the sulci could be observed (fig. 1). Chest films in four of these 11 patients showed that the relation between heart and thoracotransverse diameter exceeded the value 0.5. Furthermore,

¹ Department of Neuroradiology, University Hospital Mainz, Langenbeckstrasse 1, D-6500 Mainz, West Germany. Address reprint requests to K. Kretzschmar.

² Department of Neurology, University Hospital Mainz, D-6500 Mainz, West Germany.

³ Department of Internal Medicine, University Hospital Mainz, D-6500, Mainz, West Germany.

TABLE 1: Measurements of Brain Density and Width of CSF Spaces before and after Hemodialysis, with Changes of Body Weight

Case No. (Age, Gender)	Body Weight (kg)	Frontal Matter (H)		Parietal Matter (H)		Basal Ganglia (H)	Measurements (mm)				Remarks
		White	Gray	White	Gray		(1)*	(2)*	(3)*	(4)*	
1 (21, M)	65.4	32 ± 5	40 ± 4	30 ± 4	37 ± 5	32 ± 3	5	3	3	5.4	Norm/stationary
	63.0	30 ± 5	36 ± 4	28 ± 4	35 ± 5	30 ± 3	5	3	3	5.2	
2 (24, F)	48.8	33 ± 4	43 ± 5	32 ± 4	40 ± 5	34 ± 4	4	4	5	4.2	Norm/mild narr aft dial
	46.2	31 ± 4	39 ± 4	29 ± 4	38 ± 6	32 ± 4	3	3	4	4.5	
3 (25, F)	40.0	32 ± 5	42 ± 5	31 ± 4	41 ± 6	33 ± 4	6	5	5	4.2	Norm/mild narr aft dial
	35.6	33 ± 4	42 ± 5	30 ± 5	42 ± 6	33 ± 4	4	5	4	4.3	
4 (29, M)	57.0	32 ± 3	38 ± 4	29 ± 4	34 ± 3	34 ± 5	4	4	4	4.2	Norm/mild narr aft dial
	55.8	30 ± 4	36 ± 4	30 ± 4	38 ± 3	36 ± 4	2	3	3	4.5	
5 (38, M)	60.2	33 ± 5	40 ± 5	32 ± 5	45 ± 6	34 ± 3	9	9	6	3.5	Enlarged/stationary
	58.6	30 ± 5	38 ± 6	30 ± 5	40 ± 6	31 ± 4	9	9	6	3.5	
6 (39, M)	78.5	30 ± 5	36 ± 5	28 ± 4	38 ± 4	33 ± 4	3	4	3	6.0	Norm/stationary
	74.0	29 ± 5	36 ± 5	28 ± 3	38 ± 4	33 ± 4	3	4	3	5.9	
7 (39, F)	63.9	36 ± 4	47 ± 6	37 ± 5	46 ± 5	38 ± 4	4	4	3	5.7	Norm/stationary
	62.5	37 ± 4	46 ± 7	37 ± 4	45 ± 5	38 ± 4	4	4	3	5.6	
8 (43, F)	72.0	35 ± 4	44 ± 6	34 ± 4	45 ± 5	37 ± 4	8	5	5	4.0	Mild enlargement/narr aft dial
	69.5	34 ± 4	45 ± 6	33 ± 3	46 ± 6	38 ± 4	5	3	3	4.4	
9 (46, F)	70.5	38 ± 4	45 ± 6	36 ± 4	40 ± 4	38 ± 6	3	4	2	5.4	Norm/stationary
	67.3	39 ± 5	45 ± 6	36 ± 5	41 ± 5	38 ± 5	4	4	3	5.4	
10 (49, M)	62.9	37 ± 4	47 ± 6	35 ± 4	45 ± 4	38 ± 4	5	7	5	4.2	Norm/narr aft dial
	60.0	35 ± 3	43 ± 4	33 ± 4	42 ± 4	36 ± 5	3	4	4	4.5	
11 (49, F)	72.3	35 ± 4	48 ± 6	33 ± 3	44 ± 5	38 ± 4	5	3	2	4.8	Norm/stationary
	67.1	34 ± 4	46 ± 6	32 ± 3	41 ± 6	37 ± 5	5	4	2	4.7	
12 (51, M)	64.5	33 ± 4	43 ± 5	33 ± 4	42 ± 5	35 ± 4	5	4	3	4.7	Norm/stationary
	61.3	30 ± 5	37 ± 4	29 ± 4	36 ± 6	33 ± 5	5	3	3	4.8	
13 (51, M)	78.5	33 ± 5	43 ± 4	32 ± 4	44 ± 6	35 ± 4	7	4	4	4.2	Norm/mild narr aft dial
	75.0	31 ± 4	40 ± 4	32 ± 4	39 ± 6	32 ± 4	5	3	3	4.5	
14 (52, F)	65.6	35 ± 5	44 ± 4	33 ± 5	47 ± 6	36 ± 7	9	8	8	3.6	Enlarged/narr aft dial
	63.7	31 ± 5	41 ± 3	31 ± 4	42 ± 5	33 ± 6	7	7	6	3.8	
15 (57, M)	75.5	34 ± 4	44 ± 6	34 ± 4	43 ± 5	35 ± 5	9	9	6	4.6	Enlarged/stationary
	70.3	31 ± 5	39 ± 5	29 ± 4	39 ± 5	34 ± 5	9	9	6	4.5	
16 (60, F)	48.4	31 ± 4	42 ± 6	33 ± 3	45 ± 5	36 ± 4	5	4	3	5.0	Norm/stationary
	47.1	29 ± 4	38 ± 5	31 ± 4	40 ± 5	34 ± 4	5	4	3	5.2	
17 (62, F)	54.6	34 ± 5	42 ± 6	33 ± 4	39 ± 5	38 ± 5	8	8	7	3.3	Enlarged/stationary
	51.3	33 ± 5	40 ± 5	31 ± 4	37 ± 5	36 ± 4	8	8	7	3.3	
18 (68, F)	53.5	34 ± 4	42 ± 5	34 ± 5	46 ± 4	38 ± 5	0	9	8	3.4	Enlarged/stationary
	51.0	28 ± 5	38 ± 6	31 ± 4	43 ± 5	32 ± 6	9	9	8	3.4	
19 (68, F)	47.0	35 ± 5	42 ± 6	33 ± 4	42 ± 5	35 ± 4	8	8	6	4.0	Enlarged/stationary
	45.4	30 ± 4	37 ± 5	29 ± 4	39 ± 6	32 ± 5	7	8	6	4.0	
20 (69, F)	75.0	41 ± 4	46 ± 5	33 ± 4	45 ± 5	38 ± 4	8	6	6	4.0	Mild enlargement/narr aft dial
	72.0	36 ± 6	44 ± 6	31 ± 4	41 ± 5	36 ± 4	6	6	5	4.2	
21 (71, M)	75.0	34 ± 5	41 ± 5	33 ± 4	36 ± 6	36 ± 4	0	10	8	3.3	Enlarged/narr aft dial
	70.3	35 ± 6	43 ± 6	32 ± 4	37 ± 6	35 ± 5	8	8	6	3.6	
22 (73, M)	56.7	35 ± 5	42 ± 5	34 ± 4	42 ± 6	37 ± 4	11	6	6	3.4	Enlarged/narr aft dial
	52.9	33 ± 5	39 ± 6	29 ± 4	37 ± 6	33 ± 4	11	6	6	3.4	

Note.—In all cases except 3, 6, 7, 8, 9, and 21, density values decreased in at least three measurements. Norm = normal; narr aft dial = narrowed after dialysis.

* Areas measured were: (1) third ventricle; (2) sylvian fissure; (3) interhemispheric fissure; and (4) cella media index.

the radiographic signs of a pulmoventous congestion were seen in these patients.

In five cases the normal appearance of the ventricular system and subarachnoid spaces narrowed an average of 1 mm after dialysis. Thus, in nine patients a narrowing of the CSF spaces after the dialysis was evident, although this was accompanied by density changes of the cerebral parenchyma in only six cases. Long-term follow-up studies excluded remarkable changes in the width of the CSF spaces.

Discussion

CT examinations of patients after dialysis usually have to dispense with initial findings uninfluenced by renal failure. When the

indication for dialysis is made, there is already evidence of metabolic disorders with cerebral damage due to both decreased oxygen and glucose uptake [7]. A diminution of volume of cerebral parenchyma may develop [4]. Thus, in children with chronic renal failure a widening of the CSF spaces has been discerned in seven of 12 CT examinations [8]. In our patients there was appropriate frequency of enlargement of the ventricular system (without periventricular hypodensity of the white matter) as well as the sulci and cisterns.

If cerebral damage is suspected before the beginning of dialysis treatment, neurologic peculiarities under dialysis should occur more often. A combination of these symptoms after dialysis treatment is defined as disequilibrium syndrome [9]. The most likely explanation is that during hemodialysis a disturbance of the osmoregulation of

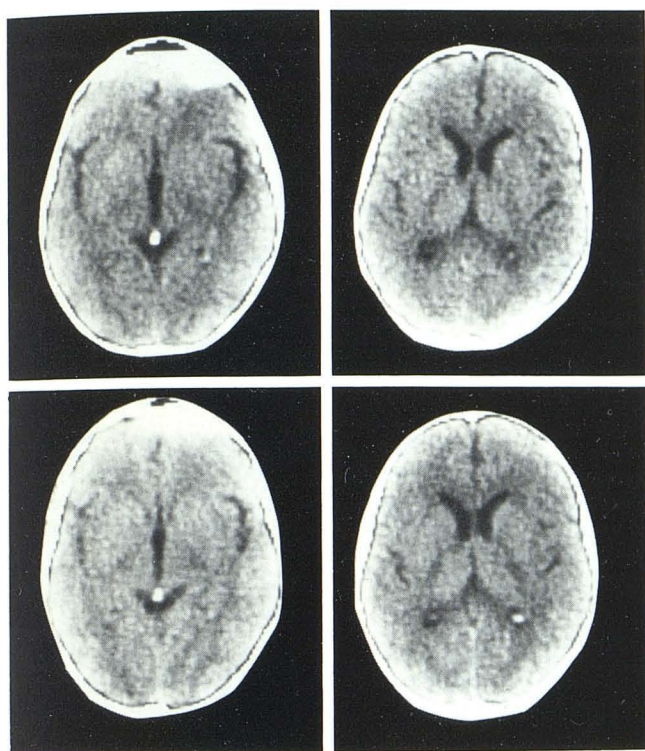


Fig. 1.—43-year-old woman with mild enlargement of third ventricle and sylvian fissure before dialysis (top row). Narrowing of the CSF spaces after dialysis (bottom row). Density values of white and gray matter are unchanged.

the central nervous system develops, the factors of which consist of reduced blood-brain barrier function, distinct sodium decrease in the extracellular space, delayed urea elimination, and abnormalities of the acid/base status. Therefore, during hemodialysis the osmolality of the extracellular fluid rapidly decreases, while the loss of intracellular liquid is delayed. An osmotically active gradient develops at the cell membrane, leading to an increase in water content of the cells [1, 10].

In 16 patients (73%) hypodense values of white and gray matter of about 2–3 H were provable immediately after dialysis. Similar observations of decreased absorption values subsequent to hemodialysis have been reported [5], in which the authors recognize a normalization of the parenchymal density within 2 days, and a further increase before subsequent dialysis sessions. This behavior is registered in chronic intermittent dialysis procedures only, not in chronic ambulant peritoneal dialysis treatment.

From our measurements, however, the changes in density after hemodialysis cannot be supposed to be due to brain edema or intracellular hydration alone. In six patients of all ages the density values remained unchanged. The weight loss of these patients was between 1.5 and 4.7 kg, so the possibility of insufficient dialysis treatment can be excluded.

Second, hydration of the cerebral parenchyma should have been accompanied by a narrowing of the ventricles and sulci. Indeed,

after dialysis nine patients exhibited narrowed CSF spaces; however, a contemporaneous decrease in density developed in only six cases. In 10 patients the CSF spaces remained unaltered, with decreased radioabsorption of the brain after dialysis. We cannot explain these contradictory results, but we believe that, in addition to the rise in water content, variations in electrolytes and the so-called "idiogenic osmoles" (i.e., organic acid and fragments of larger protein molecules) [11] seem to be of importance for the absorption values of cerebral parenchyma.

The width of CSF spaces does not indicate any correlation with over- or dehydration of the patient. A rise in CSF pressure observed under dialysis of animals [11] cannot be confirmed by CT.

Long-term follow-up studies demonstrate unchanged density values and stationary width of the CSF spaces. They do not reveal any signs of progressive encephalopathy during dialysis treatment.

Finally, it should be emphasized that despite striking CT findings of enlarged CSF spaces, their possible narrowing after dialysis, and the density change of parenchyma, there are only mild, sporadic disequilibrium syndromes (headache, nausea) clinically evident. Hence we may infer that if serious neurologic symptoms occur under dialysis treatment, a CT control is absolutely necessary.

REFERENCES

1. Port FK, Johnson W, Klass D. Prevention of dialysis disequilibrium syndrome by use of high sodium concentration in the dialysate. *Kidney Int* 1973;3:327–333
2. Benna P, Lacquaniti F, Triolo G, Ferrero P, Bergamasco B. Acute neurologic complications of hemodialysis. *Ital J Neurol Sci* 1981;2:53–57
3. Strian F, Severin F, Maurach R. Zur Diagnostik der urämischen Hirnleistungsschwäche. *Med Klin* 1982;77:90–91
4. Papageorgiou C, Ziroyannis P, Vathylakis J, Grigoriadis A, Hatzikonstantinou V, Capsalakis Z. A comparative study of brain atrophy by computerized tomography in chronic renal failure and chronic hemodialysis. *Acta Neurol Scand [Suppl]* 1982;66:378–385
5. Dettori P, La Greca G, Biasioli S, et al. Changes of cerebral density in dialyzed patients. *Neuroradiology* 1982;23:95–99
6. Meese W, Grumme TH. Die Beurteilung hirnatrophischer Prozesse mit Hilfe der Computertomographie. *Fortschr Neurol Psychiatr* 1980;48:494–509
7. Plum F, Posner J. *The diagnosis of stupor and coma*. Philadelphia: Davis, 1981
8. Rotundo A, Nevins TE, Lipton M, Lockman A, Maurer SM, Michael AF. Progressive encephalopathy in children with chronic renal insufficiency in infancy. *Kidney Int* 1982;486–491
9. Tyler HR. Neurological disorders in renal failure. *Am J Med* 1968;44:734–748
10. Teschan P, Ginn H, Bourne J. Neurobehavioral responses to middle molecules: dialysis and transplantation. *Trans Am Soc Artif Intern Organs* 1976;12:190–194
11. Arief AL. Neurological disorders in uremia. In: Brenner BM, Rector FC, eds. *The kidney*. Philadelphia: Saunders, 1981:2306–2343