



Providing Choice & Value

Generic CT and MRI Contrast Agents



FRESENIUS
KABI

CONTACT REP

AJNR

Treatment of vascular lesions with balloon catheters.

G Scialfa, F Valsecchi and G Scotti

AJNR Am J Neuroradiol 1983, 4 (3) 395-398

<http://www.ajnr.org/content/4/3/395>

This information is current as
of July 31, 2025.

Treatment of Vascular Lesions with Balloon Catheters

G. Scialfa,¹ F. Valsecchi, and G. Scotti

During a 4 year period, 48 patients were treated with balloon catheters. There were 39 fistulas and nine aneurysms. Detachable balloons with a modified Debrun technique were used in 37 patients. Different kinds of technical problems were encountered. The arterial axis remained patent in 29 of the 37 fistulas; in the two mixed internal and external carotid-cavernous sinus fistulas, combined embolization with dura, isobutyl cyanoacrylate, and detachable balloon was used. In six of the nine aneurysms the arterial axis was occluded with a detachable balloon. In three of 48 patients, severe neurologic complications resulted in death.

The use of balloon catheters is unquestionably a significant improvement for the treatment of vascular malformations; for simple fistulas this is the only possible low-risk therapeutic approach. Although different authors have used different types of material the results are very similar [1-12]. The aim of our work was to analyze the clinical and angiographic results during a 4 year period in the treatment of 48 patients with fistulas and aneurysms, using a slightly modified Debrun technique.

Materials and Methods

Forty-eight patients 4-70 years old were treated. Of these, 31 had internal carotid-cavernous sinus fistulas, three external carotid-jugular vein fistulas, two combined internal/external carotid-cavernous sinus fistulas, two vertebral arteriovenous fistulas, one

subclavian arteriovenous fistula, eight intracavernous internal carotid aneurysms, and one intracranial vertebral aneurysm. In most cases (44 of 48) the treatment was carried out with the patient under general anesthesia; in the last 18 cases continuous electroencephalographic (EEG) monitoring was obtained. A 3 French Fogarty catheter was used only for the first two carotid-cavernous fistulas, before the introduction of detachable balloons. All the other cases were treated with a modified Debrun technique. In one case in which the carotid artery had been ligated in the neck some years before, the balloon was introduced through the supraclinoid part of the internal carotid artery, which had been exposed surgically. Only in seven of 48 patients was the balloon system introduced by the femoral route (vertebral artery aneurysm and arteriovenous fistulas, carotid-cavernous fistulas in patients younger than 10 years). In the other cases the system was introduced by direct carotid puncture. The details of this technique have been described [12]. In combined fistulas between both the internal and external carotid arteries and the cavernous sinus, embolization with dura and isobutyl cyanoacrylate was used in association with detachable balloons.

Results

Angiography was performed immediately after the detachment of the balloon, and subsequent follow-up studies were carried out in some patients up to 1 year after treatment. Table 1 summarizes the clinical and angiographic results. In simple fistulas of the external carotid, vertebral, and subclavian arteries (six of 37 cases) the fistula was always occluded while maintaining patency of the arterial

TABLE 1: Angiographic and Clinical Results after Treatment of Vascular Malformations with Balloon Catheters

	No. Cases				
	Totals	Occlusion of Lesion	Arterial Axis Patency	Pseudoaneurysm, Sac	Complete Recovery
Fistulas:					
Internal carotid-cavernous sinus	31	30	23	22	29
External carotid-jugular vein	3	3	3	1	3
Vertebral arteriovenous	2	2	2	0	2
Subclavian arteriovenous	1	1	1	1	1
Combined external and internal carotid-cavernous sinus	2	1	1	0	0
Aneurysms:					
Intracavernous carotid artery	8	5	3	0	7
Vertebral artery	1	0	0	0	0

Note.—Three patients died from severe neurologic complications, one with a carotid-cavernous fistula, one with an intracavernous carotid artery aneurysm, and one with a vertebral artery aneurysm.

¹All authors: Department of Neuroradiology, Ospedale Niguarda, Piazza Ospedale Maggiore, 3, Milano, Italy. Address reprint requests to G. Scialfa.

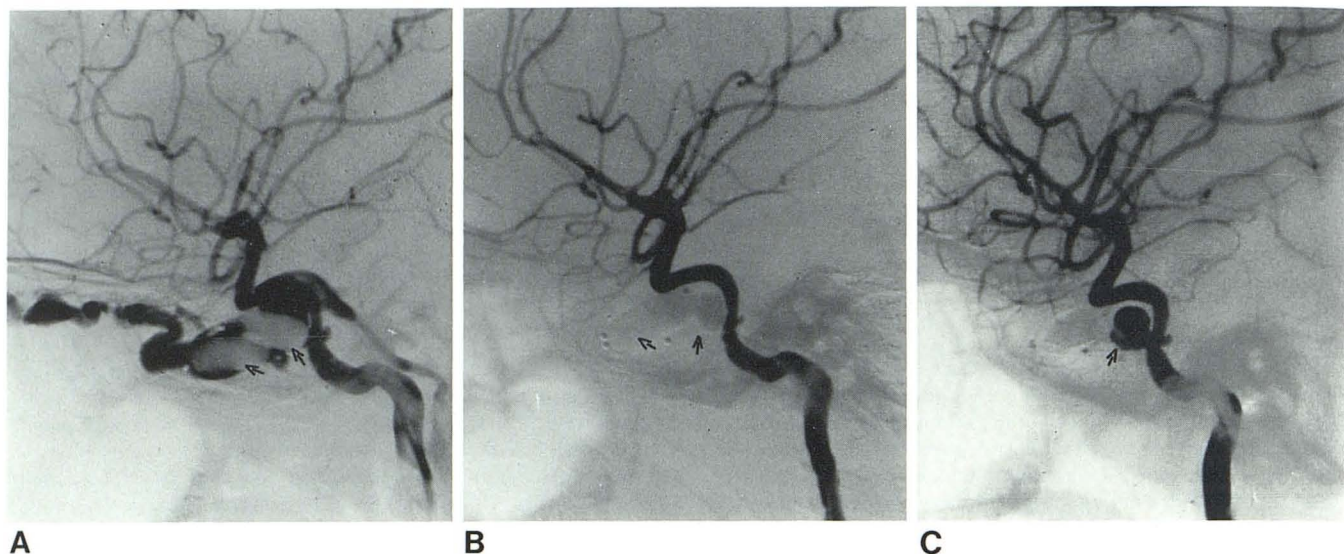


Fig. 1.—Carotid-cavernous fistula. **A**, Two balloons were insufficient to exclude fistula (arrows). **B**, Second procedure. Two more balloons in different locations were sufficient to obliterate fistula (arrows). **C**, Late angiographic follow-up. Pseudoaneurysm of carotid artery (arrow).

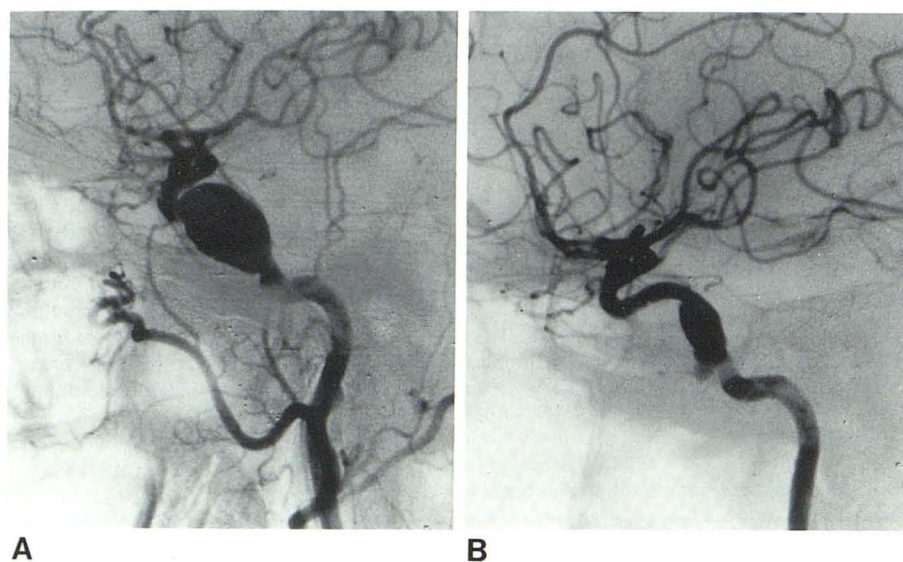


Fig. 2.—**A**, Intracavernous aneurysm. **B**, Angiographic follow-up. Aneurysm is partly occluded and internal carotid is patent after detachment of one balloon inflated with iodinated contrast and silicone.

axis. In the other simple fistulas between the internal carotid artery and the cavernous sinus (31 of 37 cases) the fistula was occluded in 30 of 31, with internal carotid patency maintained in 23 (76%) of 30. Formation of an intracavernous pseudoaneurysm usually occurs in the treatment of carotid-cavernous fistulas in which the arterial axis has remained patent (fig. 1). A pseudoaneurysm was also observed at the level of the treated fistula in one case of a subclavian fistula and in a second case with a fistula between the external carotid and jugular vein. In mixed fistulas between the external and the internal carotid arteries and the cavernous sinus, only in one case was the fistula completely occluded, with occlusion of the carotid siphon and middle meningeal artery by a balloon and of the internal maxillary artery by dura and isobutyl cyanoacrylate. In

intracavernous sinus aneurysms the carotid artery was occluded at the level of the aneurysm in five of eight cases, while in the other three cases the aneurysm was almost completely excluded with a balloon keeping the carotid artery patent (fig. 2). In one case of an aneurysm of the intracranial vertebral artery, the vertebral artery was occluded at the level of C1 since the balloon was not able to exclude the aneurysm. On angiography of the contralateral vertebral artery the aneurysm appeared largely occluded (fig. 3).

Clinical results correlated with the angiographic findings in simple fistulas of the internal and/or external carotid artery; of the vertebral and subclavian arteries, a complete cure was obtained in 35 of 37 cases. In mixed fistulas only a partial recovery was obtained in the two treated cases. In the aneurysm group a complete cure was

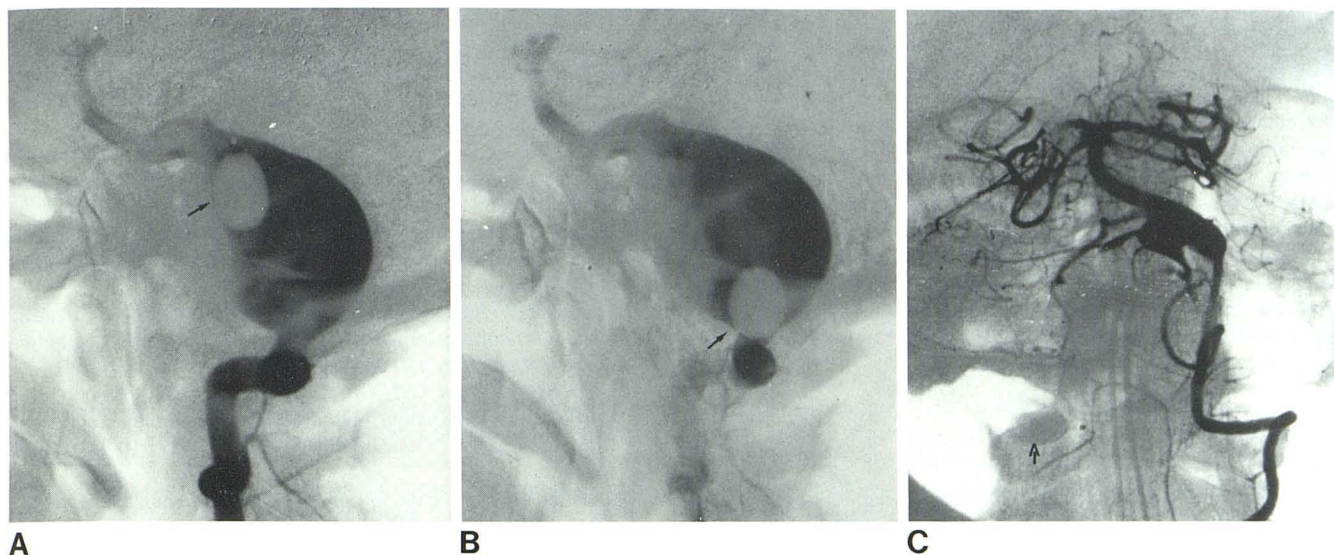


Fig. 3.—Right vertebral aneurysm. **A** and **B**, Right vertebral angiograms. Different positions of balloon within aneurysm but aneurysm is still visible (arrows). **C**, Left vertebral angiogram. Partial visualization of aneurysm after occlusion of right vertebral artery with balloon (arrow).

obtained in seven of nine cases, though in three the aneurysms remained partially patent. In one case of carotid-cavernous fistula the treatment was unsuccessful because the balloon never entered the fistula and the patient could not tolerate occlusion of the internal carotid artery. In three patients, one with a carotid-cavernous fistula and one each with an intracavernous and vertebral aneurysm, severe neurologic complications after treatment led to the patient's death.

Discussion

Different kinds of problems were encountered in the treatment of our patients; technical problems have been described in a previous paper [12]. A review of our material reveals the following. In carotid-cavernous fistulas it is preferable to introduce the system by direct puncture of the carotid artery through a catheter needle. The dead space in the Teflon catheter is less than by the femoral route, which facilitates the injection of larger amounts of silicone when necessary. The femoral route is more convenient in fistulas involving the vertebral axis and in patients younger than 10 years. The most delicate part of the technique is the detachment of the balloon by the coaxial catheter. If the ligature of the balloon on the Teflon catheter is too tight, the difficulties of detachment increase and repeated traction can cause spasm of the carotid. A too-loose ligature may cause a rapid deflation of a balloon inflated only with iodine. In six of our cases the detachment had to be done without the coaxial catheter, which could not be advanced because of marked tortuosity of the carotid at the neck. This maneuver was always difficult, displacement of the balloon occurring in two cases with occlusion of the carotid artery. In these cases the balloon must be inflated with iodine and silicone and detached when the silicone becomes solid. Exchanging iodine with silicone in a well positioned balloon is a problem, because the iodine-filled balloon can change position within the cavernous sinus during the exchange of iodine with silicone. Moreover, in one of our cases the silicone-filled balloon ruptured within the cavernous sinus when solidification had not yet occurred; there were, however, no clinical complications. We always fill the balloon with silicone when the carotid or the

vertebral artery must be occluded, since in four of our cases the iodine-filled balloon rapidly deflated and migrated within the cavernous sinus at detachment. The formation of an intracavernous pseudoaneurysm is another problem. In our patients the sac was always asymptomatic, but in two it enlarged with time, necessitating placing a balloon inflated with iodine and silicone within it. In our experience a smaller pseudoaneurysmatic sac results when the balloon is filled with iodine and silicone. Direct placement of the balloon within the supraclinoid part of the surgically exposed internal carotid artery can be used to treat those cases already unsuccessfully treated in the past with ligation of the carotid artery in the neck. This was done in one of our patients. According to Debrun et al. [5] occlusion of the carotid or vertebral artery represents the procedure of choice to avoid complications when treating aneurysms with balloon catheters. In fact in one patient the attempts to occlude the aneurysm caused rupture of the aneurysm with formation of a carotid-cavernous fistula cured only with occlusion of the carotid artery at the level of the aneurysm. Recently we have preferred a partial occlusion of the aneurysm with the balloon since this is accompanied by regression of symptoms. If the symptoms persist we occlude the carotid artery at a second stage and after an external-internal carotid bypass is carried out. Acute occlusion of a carotid artery, however, is not always tolerated, even if preceded by an external-internal carotid bypass [5]. The only severe complications that led to the patient's death occurred after acute occlusion of the arterial axis without an efficient collateral circulation. In a patient with a giant aneurysm, spasm of the circle of Willis secondary to subarachnoid hemorrhage was responsible for an inefficient collateral circulation after occlusion of the carotid artery. In a second case with a carotid-cavernous fistula even a perfectly functioning preventive external-internal carotid bypass was ineffective when the carotid was occluded at the level of the fistula since the balloon did not enter the cavernous sinus. In a third case of a giant aneurysm of the intracranial part of the vertebral artery, occlusion of the artery with a balloon was carried out after the patient had tolerated a test closure of the vertebral artery at the level of C1 under heparin for 1 hr and with continuous EEG monitoring, despite the fact that the contralateral vertebral artery was small. The angio-

graphic control showed that the aneurysm was poorly opacified and the vertebrobasilar circulation was morphologically normal (fig. 3). However, 20 hr later an acute respiratory arrest led to the patient's death. This complication could have been due in part to an inefficient collateral circulation. From our experience we can say that neuroradiologic treatment with detachable balloons results in a complete cure in most patients with fistulas or aneurysms (42 of 48 cases); the cure is incomplete in mixed fistulas (two of 48 cases). Severe complications (three of 48 cases) can be avoided only if the problem of the acute occlusion of an arterial axis without an efficient collateral circulation is solved. When the balloon does not enter the fistula and no efficient collateral circulation exists, as happened in one of our carotid-cavernous fistulas, endoarterial treatment with detachable balloons is not possible.

REFERENCES

1. Serbinenko FA. Balloon catheterization and occlusion of major cerebral vessels. *J Neurosurg* **1974**;41:125-145
2. Debrun G, Lacour P, Caron JP, Hurth M, Comoy J, Keravel Y. Inflatable and released balloon technique experimentation in dog. Application in man. *Neuroradiology* **1975**;9:267-271
3. Debrun G, Lacour P, Caron JP. New achievements in the treatment of carotid cavernous fistulae with a detachable balloon. *Neuroradiology* **1978**;15:52-53
4. Debrun G. Detachable balloon and calibrated leak balloon technique in the treatment of cerebral vascular lesions. *J Neurosurg* **1978**;49:635-649
5. Debrun G, Fox A, Drake C, Peerless S, Girvin J, Ferguson G. Giant unclippable aneurysms: treatment with detachable balloons. *AJNR* **1981**;2:167-173
6. Picard L, Lepoivre J, Montaut J, et al. Endoarterial occlusion of carotid cavernous fistulas using a balloon tipped catheter. *Neuroradiology* **1974**;8:5-10
7. Picard L, Manelfe C, Roland J, et al. Embolisations et occlusions par ballonnets dans les lésions vasculaires cranio-faciales. *Neuroradiology* **1978**;16:393-394
8. Kerber CW. Balloon catheter with a calibrated leak: a new system for superselective angiography and occlusive catheter therapy. *Radiology* **1976**;120:547-550
9. Bank WO, Kerber CW, Drayer BP, Troost BT, Maroon JC. Carotid cavernous fistula: endoarterial cyanoacrylate occlusion with preservation of carotid flow. *J. Neuroradiol* **1978**;5:279-285
10. Pevsner P. Micro balloon catheter for superselective angiography and therapeutic occlusion *AJR* **1977**;128:225-230
11. Scialfa G, Valsecchi F, Tonon C. Treatment of external carotid arteriovenous fistula with detachable balloon. *Neuroradiology* **1979**;17:265-267
12. Scialfa G, Vaghi A, Valsecchi F, Bernardi L, Tonon C. Neuro-radiological treatment of carotid and vertebral fistulas and intracavernous aneurysms. Technical problems and results. *Neuroradiology* **1982**;24:13-25