



## Discover Generics

Cost-Effective CT & MRI Contrast Agents



FRESENIUS  
KABI

WATCH VIDEO

# AJNR

### **Autoradiographic method for quantitative evaluation of the blood-brain barrier effects of contrast media.**

N Gregoire, C Nezri, J Gazendam, M Vial and G Salamon

*AJNR Am J Neuroradiol* 1983, 4 (3) 323-325

<http://www.ajnr.org/content/4/3/323>

This information is current as  
of June 23, 2025.

# Autoradiographic Method for Quantitative Evaluation of the Blood-Brain Barrier Effects of Contrast Media

Nicole Gregoire,<sup>1</sup> Charles Nezri,<sup>1</sup> Jurjen Gazendam,<sup>2</sup> Mireille Vial,<sup>3</sup> and Georges Salamon<sup>1</sup>

Opening of the blood-brain barrier after intravenous injection of different contrast media has been investigated by a quantitative autoradiographic technique using <sup>14</sup>C-aminoisobutyric acid (AIB) as the blood-brain barrier radiotracer. In this study, experiments were carried out in adult rats. Animals were injected intravenously with 2 ml/kg of the tested contrast medium, and immediately afterward with the blood-brain radiotracer AIB. The following contrast media have been tested: diatrizoate 38%, ioxithalamate 38%, ioxaglate 38%, the nonionic product metrizamide 40%, and a new nonionic product P-297, 400 mg l/ml. Control animals were injected intravenously with saline 0.9% (2 ml/kg) before the injection of the tracer. The degree of blood-brain barrier opening was quantitatively assessed by calculating the capillary rate constant for blood-to-brain transfer of AIB ( $k_i$ ) from the brain activity and the arterial integral for a 6 min experiment. Preliminary data seem to indicate that the intravenous injection of 2 ml/kg of a constant medium may produce a tiny opening of the blood-brain barrier. But, if this is so, this blood-brain barrier opening is of a very low magnitude in the normal brain and there are no obvious differences between the test contrast agents injected intravenously.

Different methods have been developed to determine the effects of contrast media on the blood-brain barrier (BBB). This problem has been classically investigated by vital dyes [1, 2]. Then, several investigators have used smaller tracer molecules, particularly the radioisotopes, <sup>32</sup>P-orthophosphate [3] and <sup>197</sup>Hg-diacetate [4], in an attempt to develop a more sensitive index for assessing BBB alterations. Another method has been electron microscopy [5, 6]. But none of these techniques has permitted us to quantify the effects of contrast media on BBB and to compare them with an objective index.

Therefore, to investigate this problem we selected a new quantitative radiographic method recently developed by Blasberg et al. [7, 8]. The BBB marker is <sup>14</sup>C-aminoisobutyric acid (AIB), which is a small synthetic neutral amino acid, not metabolized; it has been found to be a very suitable tracer for quantifying BBB opening of moderate magnitude. This molecule does not cross normal brain capillaries rapidly and is avidly taken up and concentrated by brain cells. Because of these properties a simple transport model may be applied. According to this kinetic model, it is possible to calculate an unidirectional blood-to-brain transfer constant for AIB:  $k_i$  from

the following simple equation:

$$K_i = \frac{C_b}{\int_0^t C_p dt},$$

in which  $C_b$  equals the concentration of the labelled material in the brain at the end of the experimental period, evaluated by quantitative autoradiography, and  $C_p$  is the tracer's concentration in the plasma.

In the present study, we have used this technique to evaluate the effects of contrast media on the BBB after intravenous injection, as with computed tomographic (CT) scanning. Since the widespread use of CT, large volumes of iodinated compounds have been injected intravenously. Physicians would like to select the contrast material with the lowest neurotoxicity, and, at the same time, the highest CT opacification to delineate an eventual lesion after intravenous injection.

## Materials and Methods

Experiments were carried out in adult rats which were injected intravenously with a contrast medium at a dose of 2 ml/kg. The eventual opening of the BBB was evaluated by injecting the radiotracer AIB immediately afterward. Table 1 shows the contrast media we have tested. Control animals received 2 ml/kg of saline 0.9%. Three kinds of contrast media were investigated: (1) ionic monomeric compounds like diatrizoate or ioxithalamate, which are the most hypertonic; (2) ionic dimeric compounds like ioxaglate, which is much less hypertonic; and (3) nonionic compounds like metrizamide and a new product from Guerbet Laboratory, P-297.

TABLE 1: Test Compounds used in this Study

Generic Name	Trade Name	mg l/ml
Diatrizoate	Radioselectan	380
Ioxithalamate	Telebrix	380
Ioxaglate	Hexabrix	380
Metrizamide	Amipaque	400
P-297	...	400

Note.—Control animals received NaCl 0.9%.

This work was supported by a grant from Guerbet Laboratory, Aulnay-sous-Bois, France.

<sup>1</sup> Laboratoire de Biochimie et Circulation Cérébrale, C.H.U. Timone, 13005 Marseille, France. Address reprint requests to N. Gregoire.

<sup>2</sup> Academisch Ziekenhuis Groningen, Central Klinisch Chemisch Laboratorium, Oostersingel 59, Groningen, Netherlands.

<sup>3</sup> Laboratoire de Physiologie, Faculté de Médecine Timone, Bd. Jean Moulin, 13005 Marseille, France.



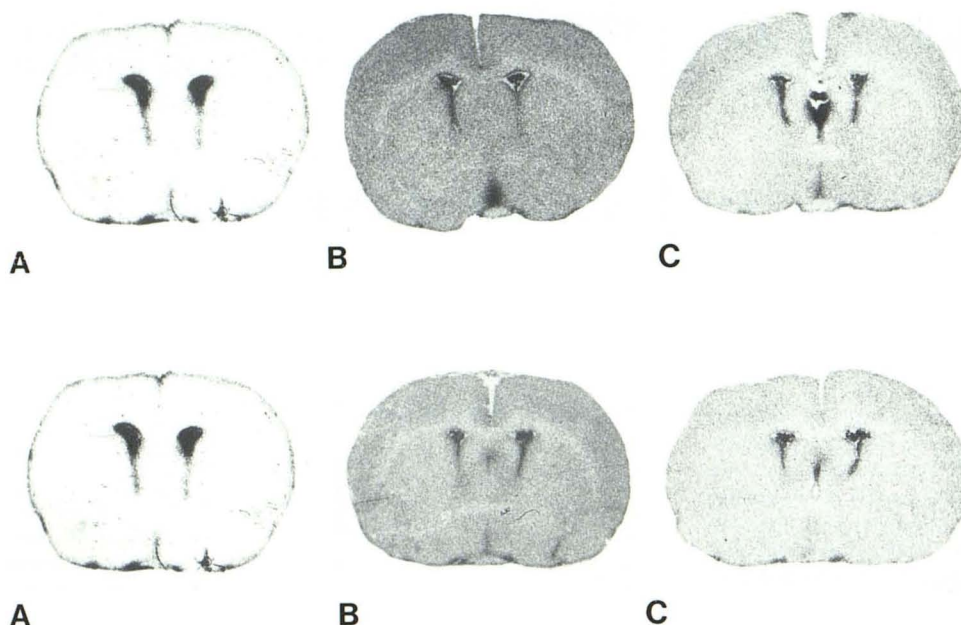


Fig. 1.—Autoradiographs of rat brain sections showing  $^{14}\text{C}$ -AIB distribution after intravenous injection of saline 0.9% (A), diatrizoate 38% (B), and ioxaglate 38% (C) at 2 ml/kg.  $k_i = 5, 28$ , and 15 for A–C, respectively. It is the blood-to-brain transfer constant for AIB ( $10^{-5} \times \text{sec}^{-1}$ ) measured in the parietal cortex.

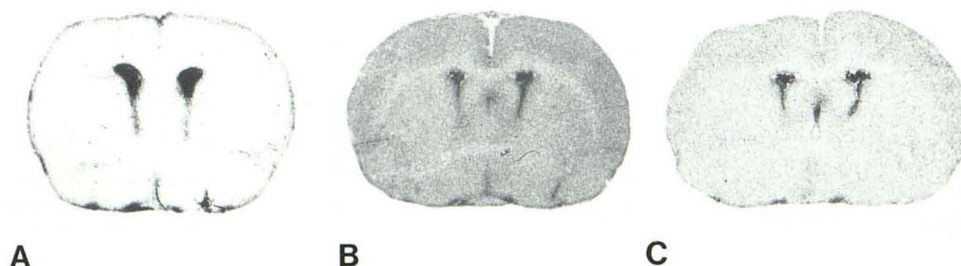


Fig. 2.—Autoradiographs of rat brain sections showing  $^{14}\text{C}$ -AIB distribution after intravenous injection of saline 0.9% (A), metrizamide 40% (B), and P-297 400 mg I/ml (C) at 2 ml/kg.  $k_i = 5, 22$ , and 17 for A–C, respectively. It is the blood-to-brain transfer constant for AIB ( $10^{-5} \times \text{sec}^{-1}$ ) measured in the parietal cortex.

The experimental procedure included the following steps: (1) insertion of catheters in the femoral vein and artery; (2) a bolus intravenous injection of the contrast medium, plus the tracer AIB ( $100 \mu\text{Ci}$  [ $0.37 \text{ Bq}$ ]), serial arterial blood sampling for  $^{14}\text{C}$ -counting in plasma, and, 6 min after start, sacrifice of the animal and rapid freezing of the brain; (3) serial sectioning of frozen brain ( $20 \mu\text{m}$ ) in a cryomicrotome at  $-20^\circ\text{C}$ ; (4) quantitative autoradiography; and (5) calculation of the blood-to-brain transfer constant for AIB ( $k_i$ ) in the following cerebral structures: olfactory cortex, parietal cortex, striatum, occipital cortex, and white matter of pons.

Quantitative autoradiography requires the exposure on the same film (Kodak SB-5) of brain sections of the same thickness and of calibrated  $^{14}\text{C}$ -standards with different known  $^{14}\text{C}$ -concentrations. The optical density of standards is measured on the film and correlated to  $^{14}\text{C}$ -concentration; from this calibration curve, the  $^{14}\text{C}$ -concentration of a cerebral structure may be calculated after measurement of its optical density.

## Results and Discussion

Autoradiographs of  $^{14}\text{C}$ -AIB distribution within rat brain in control and experimental animals are presented in figures 1 and 2. In control animals (figs. 1A and 2A), we may observe that  $^{14}\text{C}$ -activity in cerebral structures is remarkably low, except in the area of choroid plexus. Compared with the control,  $^{14}\text{C}$ -AIB distribution seems to be slightly increased after the intravenous injection of Diatrizoate (fig. 1B) or ioxaglate (fig. 1C). Autoradiographs from animals injected with nonionic contrast media (figs. 2B and 2C) also demonstrate a slight increase of  $^{14}\text{C}$ -AIB distribution. However, in all cases, the variation of  $^{14}\text{C}$ -AIB distribution pattern does not seem to be of a great magnitude after the intravenous injection of contrast media; no major difference is obvious between the tested contrast media.

Tables 2 and 3 summarize the preliminary quantitative data we have obtained. Until now, our data are limited to a few animals: three controls and 10 experimental animals injected by contrast media (two animals for each contrast agent).

For each animal, the blood-to-brain transfer constant for AIB ( $k_i$ )

TABLE 2: Effect of Intravenous Injection of 2 ml/kg of Contrast Medium on Blood-to-Brain Transfer Constant for  $^{14}\text{C}$ -AIB ( $k_i$ ) in Rats

Cerebral Structure	$k_i (10^{-5} \times \text{sec}^{-1})$	
	Control Animal (Saline 0.9%)	Animal Injected with Contrast Medium (Diatrizoate)
Olfactory cortex	10	32
Parietal cortex	10	28
Occipital cortex	12	24
Striatum	8	28
Pons white matter	5	16

TABLE 3: Blood-to-Brain Transfer Constant for AIB ( $k_i$ ) after Intravenous Injection of Contrast Media

Test Compound	$k_i (10^{-5} \times \text{sec}^{-1})$ in Parietal Cortex		
	Rat 1	Rat 2	Rat 3
Diatrizoate	28	6	...
Ioxithalamate	12	26	...
Ioxaglate	15	26	...
Metrizamide	22	9	...
P-297	17	29	...
Control	5	10	10

was calculated in five cerebral structures, as indicated on table 2. In this table, there are quite similar values of  $k_i$  in the different gray matter structures, and a relative lower value for white matter, which is probably due to differences in capillary density rather than differences in capillary permeability. Because of the similarity of  $k_i$  values in different gray matter structures, table 3 shows only the blood-to-brain transfer constant for AIB measured in the parietal cortex for each animal.

There were too few animals to evaluate the results statistically.

However, table 3 reveals that in control animals the blood-to-brain transfer constant for AIB was 5–10 U, while in animals injected with different contrast media values of  $k_i$  in most of the cases were above the control values (in most animals,  $k_i$  was greater than 10 U). On the other hand, the results in table 3 suggest there may not be significant differences of  $k_i$  among the tested contrast media.

In summary, our data indicate that the intravenous injection of 2 ml/kg of a contrast medium may produce a tiny opening of BBB, as tested by the AIB transfer measurement. But, if it is so, this opening is of a very low magnitude in a normal brain, and there are no obvious differences between the tested media when they are injected intravenously. These findings may be helpful to further investigate problems of neurotoxicity of contrast media and CT enhancement after their injection. Blood-brain barrier opening after intravenous injection of contrast media does not seem to be the most important problem. What the contrast medium is doing to the central nervous system tissue and how it moves and diffuses through the parenchyma after crossing the BBB are probably of more interest.

#### REFERENCES

1. Broman T, Olsson O. Experimental study of contrast media for cerebral angiography with reference to possible injurious effects on the cerebral blood vessels. *Acta Radiol* (Stockh) **1949**;31:321–334
2. Rapoport SI, Thompson HK, Bidinger JM. Equi-osmolal opening of the blood-brain-barrier in the rabbit by different contrast media. *Acta Radiol [Diagn]* (Stockh) **1974**;15:21–32
3. Gonsette R. La perméabilité des vaisseaux cérébraux. Etude systématique de la tolérance des capillaires cérébraux pour les produits de contraste utilisés en artériographie. *Acta Radiol [Suppl]* (Stockh) **1967**;270:228–244
4. Golman K. The blood-brain-barrier: effects of non-ionic contrast media with and without addition of  $\text{Ca}^{2+}$  and  $\text{Mg}^{2+}$ . *Invest Radiol* **1979**;14:305–308
5. Waldron RL. Effect of angiographic contrast media at the cellular level in the brain: hypertonic vs. chemical action. *AJR* **1974**;122:469–476
6. Waldron RL. Effect of contrast agents on the blood-brain-barrier. *Radiology* **1975**;116:195–198
7. Blasberg RG, Patlak CS, Jehle JW, Fenstermacher JD. An autoradiographic technique to measure the permeability of normal and abnormal brain capillaries. *Neurology* (NY) **1978**;28:363
8. Blasberg RG, Gazendam J, Patlak CS, Fenstermacher JD. Quantitative autoradiographic studies of brain edema and a comparison of multi-isotope autoradiographic techniques. In: Cervos-Navarro J, Ferszt R, eds. *Brain edema*, Advances in neurology, vol 28. New York: Raven, **1978**:255–270