



## Discover Generics

Cost-Effective CT & MRI Contrast Agents



WATCH VIDEO

# AJNR

### **Iotrol, a new myelographic agent: 2. Comparative electroencephalographic evaluation by spectrum analysis.**

M Sovak, R Ranganathan, C W Kerber, R Bickford and J F Alksne

This information is current as of June 13, 2025.

*AJNR Am J Neuroradiol* 1983, 4 (3) 319-322  
<http://www.ajnr.org/content/4/3/319>

## Iotrol, a New Myelographic Agent: 2. Comparative Electroencephalographic Evaluation by Spectrum Analysis

M. Sovak,<sup>1</sup> R. Ranganathan,<sup>1</sup> C. W. Kerber,<sup>1</sup> R. Bickford,<sup>1</sup> and J. F. Alksne<sup>2</sup>

Iotrol, a nonionic dimer isotonic with cerebrospinal fluid at 300 mg l/ml, was evaluated against metrizamide, iopamidol, and iohexol by electroencephalography (EEG) in nonanesthetized cynomolgus monkeys. Each of four monkeys was injected intrathecally with 0.5 ml/kg of 300 mg l/ml of each contrast medium. EEG was obtained before, 45 min, and 3 hr postinjection. EEG spikes, motor disturbances, convulsions, and behavior changes were observed. The EEG from C3 channel was also computer-analyzed. Average percentage differences between control and test energy content of the entire EEG and of the EEG spectrum subdivided into five frequency bands were calculated. With metrizamide, three animals suffered seizures, and all were lethargic and irritable. With iopamidol, two animals convulsed; all animals were lethargic. Transient apathy and motor disturbances were observed in the iohexol animals. No motor or behavior changes were produced by iotrol. Metrizamide and iopamidol increased the spectrum energy in all bands. Neither iohexol nor iotrol affected the EEG significantly. On the basis of these findings, iotrol holds promise as a clinical contrast material for the subarachnoid space.

A biologically inert contrast material for visualization of the subarachnoid space is not yet available. In the United States, Pantopaque is still used by those who are impressed by its high radiopacity and lack of acute neurotoxicity. The latter stems from its slow biologic interaction caused by its immiscibility with cerebrospinal fluid (CSF), which property also causes it to globulize and thus to obscure fine detail. But Pantopaque may manifest late neurotoxicity through inducing chronic inflammation of the central nervous system envelopes [1].

Ionic contrast agents have proved to be strongly epileptogenic and have also elicited chronic late arachnoiditis which, paradoxically, is potentiated by concurrently administered intrathecal steroids [2]. Neurotoxicity of ionic media (attributable to the charge, hydrophobicity of the molecule, and hyperosmolality of the solutions) has been lessened with the nonionic concept, first realized in metrizamide. In this molecule, the charge has been removed and hydrophobicity decreased by covalently attaching a highly hydrophilic substituent, a sugar residue. Consequently, osmolality has been more than halved. Yet metrizamide has its drawbacks: it is not stable in aqueous solutions, which necessitates its lyophilization; and its osmolality is equal to the CSF only at the relatively low iodine concentration of 180 mg/ml. At the more diagnostically useful 300 mg l/ml, metrizamide's osmolality is about 70% higher than the CSF.

Although some arachnoiditis has been produced experimentally with more concentrated metrizamide [3], no clinical arachnoiditis has been reported so far [4]. But metrizamide has been shown to have a considerable acute neurotoxicity that correlates with the dose and ingress into the cranial space. Side effects occur with varying frequency, and range from headache, neck pain, and stiffness to nausea, vomiting, dizziness, tinnitus, hypotension, fever, collapse, radicular pain, paresthesias, psychoorganic syndromes, and epileptic seizures [5-8].

In an effort to produce a medium superior to metrizamide, new compounds have been developed: ioglundine (P-297), Guerbet, Aulnay-sous-Bois, France; iopamidol, Bracco, Milan, Italy; MP 1013, Mallinckrodt; and iohexol, Nyegaard, Oslo, Norway. Comparative neurotoxicity studies of these compounds, sometimes conflicting, have been summarized elsewhere [9]. Although some improvement has been achieved, none of these media appears to be biologically inert. The first controlled clinical studies indicated the incidence of side effects of iopamidol similar to those of metrizamide [7]; results for MP1013, ioglundine, and iohexol are not yet available.

Although most compounds of the second generation of nonionic contrast media have lower chemotoxicity and, with the exception of loglundine, greater stability than metrizamide, they all have higher osmolality. Yet, in the intrathecal space, hyperosmolality has been shown to be a toxicologic factor [10]. To induce iso-osmolality, high hydrophilicity, and water solubility, nonionic oligomers containing six iodines and new asymmetric polyhydroxyalkyl substituents were designed and synthesized [11]. From a series of compounds, DL-3-117 (fig. 1) was chosen for further development. This became iotrol. At a concentration of 300 mg l/ml, iotrol is isotonic with the CSF, a 37°C has a viscosity of 9.1 cps, is hydrolytically stable, and infinitely water soluble. Studies of systemic toxicity and neurotoxicity have indicated superiority of iotrol to iopamidol, metrizamide, and/or iohexol [12], justifying preclinical evaluation in nonanesthetized monkeys.

### Materials and Methods

Ten quarantined cynomolgus (*Macaca fascicularis*) monkeys were prepared for the study by placing a catheter for intrathecal injections in the thoracic subarachnoid space. Under ketamine anesthesia (20 mg/kg) and sterile conditions, a partial hemilaminectomy was performed at L1 level. A 2 mm OD Silastic catheter was introduced intrathecally to the midthoracic level, the arachnoid opening was sealed with cyanoacrylate surgical glue, and the muscles were closed in layers. Unimpeded CSF flow was ascer-

This work was supported in part by National Institutes of Health grant RO1 CA32852 and Schering AG, Berlex, NJ.

<sup>1</sup> Department of Radiology, University of California San Diego, La Jolla, CA 92093. Address reprint requests to M. Sovak, S-009.

<sup>2</sup> Department of Surgery, University of California, La Jolla, CA 92093.

tained before connecting the catheter to a 2 ml Ommaya reservoir, placed subcutaneously above one of the sacroiliacal joints. A healing period of at least 10 days was allowed.

Testing the media followed standard protocol: light transient tranquilization was achieved with 0.3 ml ketamine with atropine. The animal was placed prone on a padded cradle and mechanically restrained. An hour after return to full consciousness (ascertained by reactivity), EEG was recorded from eight scalp electrodes inserted into F, C, P, and O positions. Earlobe electrodes were used as a reference bilaterally. The amplifiers were calibrated individually. At the same time, the data were recorded on an eight-channel tape recorder, and later processed by a computer system designed for EEG spectrum analysis.

A baseline EEG was established by at least 2 min of recording. The contrast medium (0.5 ml of 300 mg l/ml) was injected into the Ommaya reservoir, which was depressed and flushed with 0.5 ml of saline. The animal was inverted on the board for 5 min, until contrast material was seen by fluoroscopy to be spread over the hemispheres. EEG was recorded at 45 min and at 3 hr. During and after the experiment the animals were observed continuously for

changes in behavior, locomotion, feeding, and reactivity patterns. At least 10 days had to elapse before a monkey could be reinjected. Eight different monkeys were used, and each was exposed to the media interchangeably, so that each medium was tested on four different monkeys.

#### Evaluation of EEG

The EEG recordings were first evaluated visually for the presence of spikes. The EEG recorded from C3 channel was also analyzed in frequency ranges of 0–20 Hz, 0–4 Hz, 4–8 Hz, 8–12 Hz, and 12–20 Hz. For this analysis, the EEG segments during and after epileptic discharges were excluded, and the energy content of the EEG spectrum was expressed in arbitrary units. For the purpose of comparison we calculated percentage differences from the preinjection levels of the averages of four injections. Each animal, and each injection, thus served as its own control. The statistical significance at the 98% level of confidence was obtained by Student *t* test.

#### Results

Visual inspection of EEG and observations of the injected animals are summarized in table 1. In the metrizamide group, gross signs of neurotoxicity were a rule. Of the four animals, all had motor disturbances and three suffered seizures that, in one case, developed into a persisting epileptic status culminating in death, despite intravenous diazepam therapy. During the first 24 hr, the animals invariably showed irritability and/or depression, although at 48 hr they were found to be normal.

In the iopamidol group, two animals suffered convulsions. In one animal a transient stupor developed immediately after the inversion (i.e., about 5 min after injection). In all animals, some depression of

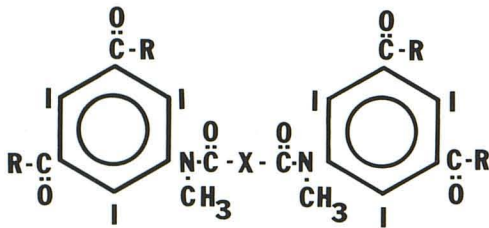


Fig. 1.—Formula of Iotrol, a nonionic dimer.

TABLE 1: EEG and Behavior Changes after Intrathecal Injection of 0.5 ml/kg, 300 mg l/ml Contrast Media in Nonanesthetized Cynomolgus Monkeys

Contrast Material: Animal No.	Motor Disturbances	Convulsions	Behavior Changes	EEG Spikes
<b>Metrizamide:</b>				
1	tremor	no	irritability, lethargy	yes
2	tremor	multiple	ditto	numerous
5	no	single, short duration	ditto	yes
6	no	multiple	death	yes
<b>Iopamidol:</b>				
1	no	multiple	exhaustion, lethargy	yes
3	no	no	irritability, lethargy	no
5	agitation, tremor	no	lethargy, transient paresis	occasional
7	no	one, single	lethargy	occasional
<b>Iotrol:</b>				
2	no	no	none	no
4	no	no	none	no
5	no	no	none	no
8	no	no	none	no
<b>Iohexol:</b>				
3	transient motor depression	no	none	no
4	transient stupor	no	none	no
7	no	no	apathy	no
8	no	no	apathy	no

TABLE 2: Changes in EEG Energy Content after Intrathecal Contrast Media

Contrast Medium: Frequency Range (Hz)	% Changes after Injection (SD)	
	45 min	3 hr
<b>Metrizamide:</b>		
0-4	253.6 (84.8)	254.1 (120.9)
4-8	507.6 (267.8)	243.9 (116.9)
8-12	677.3 (177.2)	582.8 (341.7)
12-20	653.0 (78.3)	235.5 (49.8)
0-20	305.2 (147.9)	309.7 (58.8)
<b>Iopamidol:</b>		
0-4	137.1 (24.1)	156.4 (56.9)
4-8	454.9 (158.4)	289.4 (97.4)
8-12	420.3 (224.15)	168.4 (128.7)
12-20	416.8 (362.3)	206.3 (126.3)
0-20	217.7 (148.9)	143.7 (47.4)
<b>Iohexol:</b>		
0-4	-25.1 (12.7)	20.6 (60.0)
4-8	-51.2 (6.5)	-8.1 (17.5)
8-12	13.8 (21.2)	63.7 (10.5)
12-20	122.5 (97.7)	130.0 (189.5)
0-20	-25.0 (20.7)	24.1 (23.7)
<b>Iotrol:</b>		
0-4	1.9 (18.7)	-8.4 (22.0)
4-8	28.9 (50.8)	29.5 (40.9)
8-12	54.9 (108.3)	33.4 (69.1)
12-20	-49.8 (18.9)	4.4 (35.0)
0-20	2.0 (33.3)	-5.6 (22.6)

TABLE 3: Statistical Significance among Changes in EEG Content after Intrathecal Contrast Media (98% Level of Confidence, *t* test)

	Metrizamide	Iopamidol	Iohexol	Iotrol
<b>Metrizamide:</b>				
45 min	...	NS	SS	SS
3 hr	...	SS	SS	SS
<b>Iopamidol:</b>				
45 min	NS	...	NS	SS
3 hr	SI	...	NS	SS
<b>Iohexol:</b>				
45 min	SI	SI	...	NS
3 hr	SI	NS	...	NS
<b>Iotrol:</b>				
45 min	SI	SI	NS	...
3 hr	SI	SI	NS	...

Note.—NS = equal; SS = significantly superior; SI = significantly inferior. These apply to media listed in horizontal column evaluated versus media in the vertical column.

motor activity during the first 24 hr was observed; the animals also were extremely irritable and aggressive, but at 48 hr had returned to normal. In the iohexol group, no severe motor disturbances and no spikes were seen. In two animals lethargy and irritability were observed at 3 hr, but at 24 hr postinjection the animals behaved normally. The iotrol animals did not show any changes in behavior or EEG. There was no lethargy or irritability. Following the experiments the monkeys readily exhibited normal cage activity.

The average changes of energy content of the entire EEG range (i.e., 0-20 Hz) are shown in table 2 and figure 2; the statistical significance of these changes among the various contrast media is shown in table 3. On the basis of their effects on the 0-20 Hz range, the contrast media fall into two distinct categories: metrizamide and iopamidol, and iohexol and iotrol. Both metrizamide and

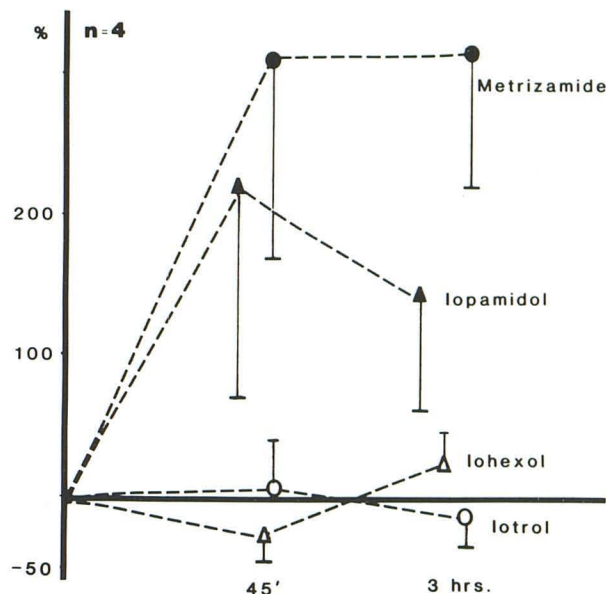


Fig. 2.—Percentage differences with standard deviations between controls and tests of the energy content of entire EEG spectrum (0-20 Hz).

iopamidol greatly increased the spectrum energy after 45 min. At 3 hr the iopamidol value had declined compared with metrizamide. Changes caused by iohexol and/or iotrol were minimal. Since changes in the EEG energy content can be interpreted as lack of inertness, it can be seen that both iohexol and iotrol were superior to metrizamide both at 45 min and 3 hr, while iopamidol was equal to metrizamide at 45 min and superior at 3 hr. At both observation periods iohexol was equal to iopamidol and iotrol was superior to iopamidol, although iohexol was statistically equal to iotrol.

The division of the EEG spectrum into ranges (table 2) revealed that metrizamide was statistically inferior to iopamidol only at 45 min in range 0-4 Hz, while it was equal in all other ranges at both 45 min and 3 hr. The largest significant increases, both for metrizamide and iopamidol, occurred in the 4-8 and 8-12 Hz ranges. Both iotrol and iohexol were superior to metrizamide and/or iopamidol in the 0-4, 4-8, and 8-12 Hz ranges, and equal at 12-20 Hz, both at 45 min and 3 hr. Iohexol was found equal to iotrol in all ranges, both at 45 min and 3 hr.

## Discussion

Several conclusions can be drawn from this study. Cynomolgus appears to be an extremely sensitive experimental animal for the intrathecal testing of neurotoxicity, much more so than the rhesus used by Hilal et al. [13]. With cynomolgus, smaller doses should probably be used in future experiments. On the other hand, there is some justification for using excessive doses experimentally, in the expectation they would compensate for a clinical situation where specific pathology makes the patient less resistant to the neurotoxicity of contrast media.

In the preclinical intrathecal testing, use of a nonhuman primate is justified, as lower species can exhibit only manifestations of gross toxicity (e.g., epileptogenicity). Infrequent clinical side effects were predicted for metrizamide on the basis of studies in lower animals, but its considerable neurotoxicity became apparent in clinical use. Also, the EEG changes seen in lower species can differ qualitatively from those in primates. Previous analysis of rabbit EEG, for exam-

ple, revealed preponderant increase in the low frequency band only, indicative of formation of a transient subcortical pacemaker [14]. In this study, the increase was observed in all bands.

Analysis of the EEG spectrum, subdivided into ranges, is a neuropharmacologic approach superior to visual inspection or determination of the entire frequency range of the EEG spectrum, since the latter may not reveal any abnormalities. Yet, the present technology of EEG analysis must be considered a comparatively crude method of evaluating neurotoxicity. It is obvious that certain side effects reported for metrizamide (i.e., headache, nausea, perception disturbances, hallucinations, and psychoorganic syndrome) cannot be evaluated by this methodology. Further, even if EEG detects disturbances of the electrical activity of neural tissue, it only rarely gives a clue as to their origin. However, the animals' behavior, although extremely difficult to quantify, can be useful, especially if methods of behavioral research are employed [15]. If the lack of interference with the electrical activity of the central nervous system and the unaffected behavior of cynomolgus injected with iotrol accurately predict clinical experience, iotrol seems to be a promising contrast material for the human subarachnoidal space.

#### REFERENCES

- Burton CV. Lumbosacral arachnoiditis. *Spine* **1978**;3:24-30
- Ahlgren P. Early and late side effects of water soluble contrast media for myelography and cisternography: a short review. *Invest Radiol [Suppl]* **1980**;15:264-266
- Haughton VM, Eldevik OP. Complications from aqueous myelographic media: experimental studies. In: Sackett JF, Strother CM, eds. *New techniques in myelography*. New York: Harper & Row, **1979**:183-194
- Hansen EB, Fahrenkrug A, Praestholm J. Late meningeal effects of myelographic contrast media with special reference to metrizamide. *Br J Radiol* **1978**;51:321-327
- Sackett JF, Strother CM, Quaglerie CE, Javid MJ, Levin AG, Duff TA. Metrizamide—CSF contrast medium. Analysis of clinical application in 215 patients. *Radiology* **1977**;123:779-782
- Sartor K. Ascending and descending myelography with water-soluble contrast medium. A report on thoracic and cervical metrizamide-myelography in 200 patients. *Rontgenblatter* **1979**;32:251-265
- Hammer B, Lackner W. Iopamidol, a new non-ionic hydrosoluble contrast medium for neuroradiology. *Neuroradiology* **1980**;19:119-121
- Gelmers HJ. Adverse side effects of metrizamide in myelography. *Neuroradiology* **1979**;18:119-123
- Sovak M. Contrast media for imaging of CNS. In: Sovak M, ed. *Radiocontrast media. Handbook of experimental pharmacology*. New York: Springer, **1982** (in press)
- Piwonka RW, Healey JF, Rosenberg FJ. Intrathecal tolerance of metrizamide in chloralose-anesthetized cats. *Invest Radiol* **1976**;11:182-186
- Sovak M, Ranganathan R. Novel amino-dioxepane intermediates for the synthesis of new nonionic contrast media. U.S. Patent 4,341,756, July 27, **1982**
- Sovak M, Ranganathan R, Speck U. Nonionic dimer: development and initial testing of an intrathecal contrast agent. *Radiology* **1982**;142:115-118
- Hilal SK, Dauth GW, Hess KH, Gilman S. Development and evaluation of a new water-soluble iodinated myelographic contrast medium with markedly reduced convulsive effects. *Radiology* **1978**;126:417-422
- Sovak M, Ranganathan R, Johnson M. Spectral analysis of lapine EEG: neurotoxicologic evaluation of new nonionic contrast media. *Invest Radiol* **1980**;15:452-456
- Sovak M, Deutsch JA, Ranganathan R. Evaluation of intrathecal contrast media by aversion conditioning in rats. *Invest Radiol* **1982**;17:101-106